Digitized by Illinois College of Optometry

DR. WILLIAM FELLMAN, 2nd

Digitized by Illinois College of Optometry

NASAL NEUROLOGY
HEADACHES AND EYE DISORDERS

Digitized by Illinois College of Optometry

NASAL NEUROLOGY
HEADACHES AND EYE DISORDERS

BY

GREENFIELD SLUDER, M.D., F.A.C.S.

CLINICAL PROFESSOR AND DIRECTOR OF THE DEPARTMENT OF OTO-LARYNGOLOGY,
WASHINGTON UNIVERSITY SCHOOL OF MEDICINE
ST. LOUIS

WITH 167 ILLUSTRATIONS, INCLUDING 2 COLOR PLATES

ST. LOUIS
THE C. V. MOSBY COMPANY
1927

Digitized by Illinois College of Optometry

COPYRIGHT, 1927, BY THE C. V. MOSBY COMPANY

(All rights reserved)

Printed in U. S. A.

Carl F. Shepard Memorial Library
Illinois College of Optometry
3241 S. Michigan Ave.
Chicago, Ill. 60616

11927

Press of
The C. V. Mosby Company
St. Louis.

Digitized by Illinois College of Optometry

To the Memory of

DR. GUSTAV BAUMGARTEN

Professor of Physiology in the St. Louis Medical College, now the Medical Department of Washington University, from 1873 to 1887; Professor of Special Therapeutics and Pathology, from 1887 to 1893; Professor of Medicine from 1893 to 1910

Whose infinite kindness and personal help with advanced subjects not then in the curriculum has been a help throughout my life.

Digitized by Illinois College of Optometry

PREFACE

Since the appearance of my monograph in 1918, *Concerning Some Headaches and Eye Disorders of Nasal Origin,* the neurological side of rhinology has become constantly more manifest to me, and so far as I know no rhinologist has emphasized the neurological side of rhinology. I have, therefore, chosen the title *Nasal Neurology, Headaches and Eye Disorders* for this monograph with the special intention that it may attract the interest of neurologists, internists and ophthalmologists to a greater extent than the customary treatise on rhinology. Rhinology is sadly in need of this cooperation for two very definite reasons, namely, in order to secure clinical cooperation in obscure neurological cases and in order to obtain post-mortem material in which the life history of the individual is definitely known. Material for the study of the pathology involving these issues so far as I know is the most difficult of any to obtain, in fact heretofore it has been impossible to obtain.

In the chapter on Some Neurological Problems in Rhinology special emphasis has been laid upon the neurological side of rhinology and the special part played by the involuntary nervous system which is superficial in the nose and nowhere else in the body. Much of the recent clinical and experimental work on the involuntary system has been reviewed in this chapter with the hope that this collateral information may possibly be of help in exciting ideas in the minds of others concerning the nose and the involuntary system. There was much neurological material in the monograph that I published in 1918 and for the purposes of this book that material has been incorporated.

I have also included some items of purely rhinological interest, namely, an antrum technique heretofore unpublished, and a short chapter on orbital abscess, as well as a chapter on anterior ethmoidal neuralgia.

I desire earnestly to thank Dr. French K. Hansel, Instructor in Oto-Laryngology, Washington University School of Medicine, St. Louis, for some highly efficient help in the preparation of

Digitized by Illinois College of Optometry

abstracts of work appearing in the past fifteen months. Without his assistance the bibliography could not have been presented so well; indeed the volume could not have been brought up to date.

I also desire to thank Miss Dorothy L. Hollman for expert help in the arrangement of much of this material into book form.

GREENFIELD SLUDER.

St. Louis, June, 1927.

Digitized by Illinois College of Optometry

CONTENTS

PAGE

CHAPTER I.—AN INTRODUCTION REFERRING TO SOME POINTS IN THE MINUTE PATHOLOGICAL ANATOMY OF THE PROCESS. BY JONATHAN WRIGHT, M.D. _ _ _ _ _ _ _ _ _ _ _ _ _ _ _ _ 17

CHAPTER II.—THE NOSE _ _ _ _ _ _ _ _ _ _ _ _ _ _ _ _ _ _ 25
A General Consideration _ _ _ _ _ _ _ _ _ _ _ _ _ _ _ _ 25

CHAPTER III.—VACUUM FRONTAL HEADACHES WITH EYE SYMPTOMS ONLY _ 31
Clinical Picture _ _ _ _ _ _ _ _ _ _ _ _ _ _ _ _ _ _ 33
Ewing's Sign _ _ _ _ _ _ _ _ _ _ _ _ _ _ _ _ _ _ _ 33
Gross Etiology _ _ _ _ _ _ _ _ _ _ _ _ _ _ _ _ _ _ _ 35
Anatomy of the Middle Meatus _ _ _ _ _ _ _ _ _ _ _ _ 36
Differential Diagnosis _ _ _ _ _ _ _ _ _ _ _ _ _ _ _ 63
Headaches from all Causes and Their Separation from That Produced by Closure of the Frontal Sinus without Suppuration _ _ _ _ 64
Prognosis _ 64
Treatment _ 65
Vacuum Ethmoidal Headaches with Eye Symptoms Only _ _ _ _ _ 66

CHAPTER IV.—ANTERIOR ETHMOIDAL (B. N. A.) (NASOCILIARY [QUAIN]) NEURALGIA _ _ _ _ _ _ _ _ _ _ _ _ _ _ _ _ _ 68
Nasociliary or Nasal Nerve _ _ _ _ _ _ _ _ _ _ _ _ _ _ _ 68
Varieties _ 70
Clinical Pictures _ _ _ _ _ _ _ _ _ _ _ _ _ _ _ _ _ _ 70
Diagnosis _ 71
The Differential Diagnosis _ _ _ _ _ _ _ _ _ _ _ _ _ _ 71
Treatment _ 71
Case Report _ 72

CHAPTER V.—THE SYNDOME OF NASAL (SPHENOPALATINE-MECKEL'S) GANGLION NEUROSIS _ _ _ _ _ _ _ _ _ _ _ _ _ _ _ _ _ 74
Anatomy _ 74
The Sphenopalatine Ganglion _ _ _ _ _ _ _ _ _ _ _ _ _ 74
The Anatomic Relations of the Sphenopalatine Ganglion _ _ _ _ 78
Anatomical Relations of the Nerve of the Pterygoid Canal _ _ _ _ 82
Anatomical Relations _ _ _ _ _ _ _ _ _ _ _ _ _ _ _ _ 83
The Relations of the Nasal Ganglion to the Walls of the Paranasal Cells _ _ _ _ _ _ _ _ _ _ _ _ _ _ _ _ _ _ _ 88
The Relation of the Nasal Ganglion to the Lateral Wall of the Nose 89
Clinical Relations _ _ _ _ _ _ _ _ _ _ _ _ _ _ _ _ _ _ 90
Lower Half Headache _ _ _ _ _ _ _ _ _ _ _ _ _ _ _ _ _ 93
The Neuralgic Syndrome with the Usual Forerunner _ _ _ _ _ 93
The Sympathetic Syndrome _ _ _ _ _ _ _ _ _ _ _ _ _ _ 94

Digitized by Illinois College of Optometry

PAGE

Diagnosis - 107
Differential Diagnosis - - - - - - - - - - - - - - - - - - 110
Prognosis - 111
Treatment - 115
Anatomical Considerations - - - - - - - - - - - - - - - - 115
Instrumentarium - 122
Technique - 123

CHAPTER VI.—HYPERPLASTIC SPHENOIDITIS AND ITS CLINICAL RELATIONS TO THE ENVIRONING NERVES, TO WIT: N. OPTICUS, N. OCULOMOTORIUS, N. TROCHLEARIS, N. TRIGEMINUS, N. ABDUCENS AND N. CANALIS PTERYGOIDEI (VIDII), AND NASAL GANGLION - 139
Anatomical Relations - - - - - - - - - - - - - - - - - - - 140
Clinical Relations - 156
Diagnosis - 185
The Correlated Action of the Pharynx and Soft Palate; and Its Effects upon Post-nasal Diagnosis - - - - - - - - - - - - - - 193
Prognosis - 216
Treatment - 219
Proetz Displacement Irrigation - - - - - - - - - - - - - - 221
Surgery of the Paranasal Cells - - - - - - - - - - - - - - 237
The Author's Technique - - - - - - - - - - - - - - - - - 242
Anesthesia - 242
The Operative Procedure - - - - - - - - - - - - - - - - - 246
Technique - 248

CHAPTER VII.—SOME NEUROLOGICAL PROBLEMS IN RHINOLOGY - - - - - 271

CHAPTER VIII.—SURGERY OF THE MAXILLARY ANTRUM - - - - - - - - 303
The Author's Antrum Operation - - - - - - - - - - - - - - - 303

CHAPTER IX.—ORBITAL ABSCESS - - - - - - - - - - - - - - - - - 311
History - 312
Diagnosis - 312
Treatment - 315

CHAPTER X.—CASE HISTORIES - - - - - - - - - - - - - - - - - - 318
References - 403

Digitized by Illinois College of Optometry

ILLUSTRATIONS

FIG.		PAGE
1.	Osteoblasts	18
2.	Hyperplasia of bone of sphenoethmoidal wall	19
3.	Papillary hypertrophy of mucous membrane of sphenoid sinus—rarefying osteitis	20
4.	Rarefying osteitis	21
5.	Chronic hypertrophy of middle turbinate body	22
6.	Chronic hypertrophy of middle turbinate body	23
7.	Showing where needle has been passed through the floor of the frontal sinus at the point of attachment of the pulley of the superior oblique	31
8.	Showing a dissection of the right orbit from above	32
9.	Showing a needle passed from frontal sinus at a point back of the attachment of the pulley of the superior oblique	34
10.	Showing hiatus semilunaris, infundibulum and frontal sinus in direct and uncomplicated connection	37
11.	Showing ethmoidal cell entering infundibulum from above and behind	37
12.	Showing ethmoidal cells entering infundibulum and hiatus semilunaris from above and below in front	38
13.	Showing ethmoidal cells entering infundibulum and hiatus semilunaris from above in front and behind and below	38
14.	Showing hiatus semilunaris ending in blind pocket above, infundibulum limited above by roof of nose	38
15.	Frontal sinus; bristle passed from frontal sinus into hiatus semilunaris; a large hiatus cell of the ethmoid	38
16.	Showing ethmoidal cells opening into hiatus semilunaris which ends above in a blind pocket	39
17.	Showing hiatus semilunaris ending in blind pocket above	39
18.	Specimen from a term fetus. The recessus frontalis is exposed for study by the removal of the operculating concha nasalis media	39
19.	Specimen from a term fetus. Recessus frontalis exposed	40
20.	Specimen from a term fetus. A single frontal fold or concha presents, bordered by a dorsal and a ventral frontal furrow	40
21.	Specimen from a term fetus. Recessus frontalis exposed by partial removal of concha nasalis media.	41
22.	Specimen from a child aged fourteen months, showing the apparent absence of frontal furrows and folds; whole recessus frontalis is expanding or growing frontalward in the establishment of the sinus frontalis	41
23.	Specimen from an adult. Recessus frontalis and nasofrontal connections exposed for study by the removal of part of the concha nasalis media.	42
24.	Specimen from an adult. Recessus frontalis and nasofrontal connections exposed for study	42
25.	Specimen from an adult. Dissection showing the nasofrontal connections and the ethmoidal labyrinth exposed	43

Digitized by Illinois College of Optometry

FIG. PAGE

26. Dissection from an adult, showing two sinus frontales, the absence of ductus nasofrontalis, and the ventral termination of the infundibulum ethmoidale _ _ _ _ _ _ _ _ _ _ _ _ _ _ _ _ _ _ _ 43
27. Dissection from an adult, showing sinus frontalis present in duplicate, the proximal ostia frontalis in relation to the recessus frontalis, and the ventral termination of the infundibulum ethmoidale _ _ _ _ _ 44
28. Dissection from an adult. Recessus frontalis exposed _ _ _ _ _ _ _ 44
29. Dissection from an adult. Recessus frontalis exposed _ _ _ _ _ _ _ 45
30. Dissection from an adult, showing the roomy ductus nasofrontalis, discontinuous with the infundibulum ethmoidale _ _ _ _ _ _ _ _ _ 45
31. Hiatus semilunaris situated unusually far back _ _ _ _ _ _ _ _ _ 46
32. Amputation of middle turbinate with the line of origin from the lateral wall. Cavernous tissue on the internal aspect of frontal pouch _ _ _ 47
33. Normal left lateral wall, showing orbit, middle turbinate, sphenoidal sinus, eustachian tube orifice, soft palate _ _ _ _ _ _ _ _ _ _ _ 48
34. View of lateral wall showing free margin of middle turbinate and total absence of cavernous tissue _ _ _ _ _ _ _ _ _ _ _ _ _ _ _ 49
35. Showing middle turbinate detached in its anterior two-thirds and turned up at the bulla ethmoidalis _ _ _ _ _ _ _ _ _ _ _ _ _ _ _ 50
36. Bulla ethmoidalis in contact with processus uncinatus _ _ _ _ _ _ _ 50
37. Septum showing well-marked tubercle and deeply marked imprint of entire middle turbinate _ _ _ _ _ _ _ _ _ _ _ _ _ _ _ _ _ _ _ 51
38. Sagittal section through the capsule of the ethmoid, left side, showing relations of middle turbinate to the turbercle of the septum _ _ _ 52
39. Showing middle turbinate placed with free space between septum and lateral wall _ 53
40. Showing tubercle of the septum well marked almost like a spur at its upper limit _ 54
41. Bivalve, Vienna model _ 55
42. Showing posterior spur and well-marked ridge with large tubercle _ _ 56
43. Cross section in posterior part of nose showing spurs above and below middle turbinate _ _ _ _ _ _ _ _ _ _ _ _ _ _ _ _ _ _ _ 57
44. Wood's metal casts of a narrow middle meatus _ _ _ _ _ _ _ _ _ 60
45. Wood's metal casts of a wide middle meatus _ _ _ _ _ _ _ _ _ _ 60
46. Wood's metal cast of a middle meatus with wide frontal and ethmoidal pouches readily permitting the flow of metal into frontal and ethmoidal sinuses _ 61
47. Wood's metal cast of very wide middle meatus with very wide frontal and ethmoidal pouches readily permitting flow of metal into frontal ethmoidal cells _ 61
48. Schema showing the connection of the sphenopalatine (Meckel's, nasal) ganglion (Color Plate) _ _ _ _ _ _ _ _ _ _ _ _ _ _ _ _ _ 76
49. A basal dissection of the sphenoidal and maxillary sinuses _ _ _ _ _ 81
50. Showing nasal ganglion, Vidian nerve, nasal and palatal branches _ _ 83
51. Showing sphenopalatine foramen bounded above by sphenoidal sinus, and in front by ethmoidal cells _ _ _ _ _ _ _ _ _ _ _ _ _ _ _ 84
52. Sagittal section 7 mm. lateral to the sphenopalatine foramen _ _ _ _ 85
53. Showing left sphenoidal sinus prolonged downward in front to form the anterior wall of the sphenomaxillary fossa _ _ _ _ _ _ _ _ _ _ 86

Digitized by Illinois College of Optometry

FIG. PAGE

54. Showing anatomy of the nasal ganglion – – – – – – – – – – – 87
55. Showing anterior face of right pterygoid process – – – – – – – – 89
56. Sagittal section 3 mm. lateral to the sphenopalatine foramen, showing a dissection of the sphenopalatine fossa – – – – – – – – – 90
57. Showing middle turbinate; sphenopalatine foramen directly posterior to and slightly above posterior tip of middle turbinate – – – – – – 91
58. Showing an unusual placement of the sphenopalatine foramen – – – – 92
59. Anatomic model showing Gasserian ganglion, internal carotid artery, carotid sympathetic plexus and related structures – – – – – – 109
60. Showing pterygoid process projecting forward beyond the posterior limit of sphenopalatine foramen – – – – – – – – – – – – – – 116
61. Showing usual sphenopalatine foramen. The pterygoid process is behind it 117
62. Showing correct placing of the needle for injection of the nasal ganglion 118
63. Showing both straight and curved needles correctly placed for injection of the nasal ganglion – – – – – – – – – – – – – – – 119
64. Showing nasal ganglion needle having passed across the sphenomaxillary fossa and then through the thin wall of a low set sphenoidal sinus – 120
65. Showing needle transfixing the middle turbinate – – – – – – – – 121
66. Showing needle (point) having passed across the sphenomaxillary fossa to be free in a prolongation of the sphenoidal sinus prolonged downward into the pterygoid process – – – – – – – – – – – – 124
67. Curved and straight needles for injection of ganglion – – – – – – 125
68. Showing a specimen in which the needle has passed through the posterior palatine canal to arrive automatically on the face of the sphenoid where the nasal ganglion lies – – – – – – – – – – – – 127
69. Specimen showing needle having passed through the posterior palatine canal and deflected slightly outward – – – – – – – – – 128
70. Bony environments of sphenopalatine foramen and sphenoidal fissure, demonstrating their relations and the distance between them – – – – 131
71. Semidiagrammatic representation of the contents of the sphenoidal fissure, showing their relations to one another, both in the fissure and in the cavernous sinus – – – – – – – – – – – – – – – – – – 132
72. Relations of the structures in the cavernous sinus and the sphenoidal fissure as depicted in Cunningham's *Anatomy* – – – – – – – – – 133
73. Contents of the sphenoidal fissure right side – – – – – – – – – 134
74. The contents of the sphenoidal fissure, showing their relations to one another and to the nasal ganglion and the Vidian nerve – – – – – – 135
75. The same dissection shown in Fig. 74, but viewed from the mesial side 136
76. Left sagittal section 5 mm. lateral to sphenopalatine foramen showing post-ethmoidal cell above and beyond optic nerve – – – – – – – 139
77. The thin transparent bony wall of the sphenoidal sinus has been removed, showing sphenoidal sinus, Gasserian ganglion, first division of trigeminus, second division of trigeminus, third division of trigeminus, abducens, trochlearis, oculomotorius – – – – – – – – – – – – 140
78. Showing prolongation of sphenoidal sinus around optic canal – – – – 141
79. Anterior and middle fossae of skull seen from above – – – – – – 142
80. Showing an older representation of the sphenoidal sinus and the cavernous sinus – 143
81. Cross transverse section of the cavernous sinus – – – – – – – – 143

Digitized by Illinois College of Optometry

FIG. PAGE
82. The usual cavernous sinus with large cross section and great length 143
83. Cavernous sinus district 143
84. Cavernous sinus district 144
85. Left middle fossa of skull, viewed from above and to the left showing foramen ovale separated from sphenoidal sinus by thin bone 144
86. Same specimen as Fig. 60 viewed from above and to the right 144
87. Top view of left sphenoidal district dissected 145
88. Shows a sagittal section of left side through the ophthalmic nerve 146
89. Sphenoidal cell. Columnar marking of the internal carotid artery 147
90. Showing Vidian exposed in right sphenoidal sinus. Cross section through the pterygoid processes 148
91. Left Vidian canal deficient at point of indicator 149
92. Right sphenoidal cell; first division of fifth nerve; second division of fifth nerve 149
93. Showing paper-thin separation of maxillary nerve in foramen rotundum from sphenoidal sinus 150
94. Cross section just anterior to anterior clinoid process 150
95. Cross section showing anterior clinoid process right, N. oculomotorius, N. trochlearis, N. ophthalmicus, N. maxillaris, anterior beginning of cavernous sinus, middle fossa of skull 150
96. Cross section of sphenoidal body through anterior clinoid processes posterior to optic canals, seen from in front 151
97. Lateral part of sagittal section through the line of sagittal cut 151
98. Sagittal section between the foramen rotundum and Vidian canal, right side, viewed from without inward 152
99. Sagittal section of specimen shown in Fig. 100 through the maxillary nerve 153
100. Showing the nasal (internal) surface of specimen shown in Fig. 99 154
101. Sagittal section between foramen rotundum and Vidian canal viewed from without 155
102. Shows lateral view of a dry specimen in which the space between the plates of the pterygoid process has been filled with barium paste 156
103. Shows the lateral view of a sphenoid which extends downward into the pterygoid process 157
104. The same case as shown in Fig. 103. This sphenoid has been partly filled with iodized oil which is readily seen extending downward into the prolongation into the pterygoid process 158
105. Shows anteroposterior view of Fig. 104. The iodized oil in the pterygoid process is readily recognized 159
106. Shows the same case as Fig. 105 without the iodized oil. No mark in this picture reveals the prolongation to the pterygoid 160
107. Shows an ordinary lateral view of a large sphenoid 161
108. Shows the lateral view of a sphenoid which extends downward and backward 162
109. The same sphenoid as that shown in Fig. 108 filled with iodized oil 163
110. Same case as Fig. 109, anteroposterior view of sphenoid filled with iodized oil 164
111. Leitz lilliput arc lamp 186
112. Showing a cell which appeared to be the sphenoidal cell 206

Digitized by Illinois College of Optometry

FIG. PAGE

113. Same as Fig. 112 showing probe in lower cell _ _ _ _ _ _ _ _ 207
114. Showing an upper and lower subdivision of the sphenoidal body _ _ _ 208
115. Showing an anterior and posterior subdivision of the sphenoidal body _ 209
116. Showing subdivided sphenoidal body _ _ _ _ _ _ _ _ _ _ _ _ 210
117. Showing probe in large undivided sphenoidal body _ _ _ _ _ _ _ 211
118. Shows probe introduced into a very large sphenoidal cell downward to the bifurcation of the plates _ _ _ _ _ _ _ _ _ _ _ _ _ _ _ 212
119. Same as Fig. 118 taken from in front _ _ _ _ _ _ _ _ _ _ _ _ 213
120. Shows the left half of a specimen. Right sphenoidal sinus extending into left side to border left optic canal _ _ _ _ _ _ _ _ _ _ _ _ 214
121. Two views of palate hook _ _ _ _ _ _ _ _ _ _ _ _ _ _ _ _ 215
122. Diagram indicating the correct position of the head for displacement irrigation _ _ _ _ _ _ _ _ _ _ _ _ _ _ _ _ _ _ _ 222
123. Displacement irrigation. The introduction of fluid into the nostril _ _ 223
124. Displacement irrigation. Intermittent suction is applied at the nostril, withdrawing bubbles of air from the sinuses and permitting their replacement with drops of the overlying fluid _ _ _ _ _ _ _ _ 223
125. Displacement irrigation. Patient returned to the erect position _ _ _ 224
126. Displacement irrigation. Diagram illustrating the prone position _ _ _ 224
127. Displacement irrigation. Lateral plate made in the position in which the displacement was done _ _ _ _ _ _ _ _ _ _ _ _ _ _ _ 230
128. Displacement irrigation. The same as Fig. 127, in the erect position _ _ 231
129. Displacement irrigation. Lipiodol mapping of a sphenoid, which observed empty showed no abnormalities _ _ _ _ _ _ _ _ _ 232
130. Displacement irrigation. Lateral and posterior anterior views of the right maxillary sinus, showing an intrinsic filling defect _ _ _ _ _ _ 233
131. Displacement irrigation. Typical intrinsic filling defect of the right maxillary sinus _ _ _ _ _ _ _ _ _ _ _ _ _ _ _ _ _ _ 234
132. Position of applicators for cocainization of the nasal ganglion and for cocainization of the anterior ethmoidal nerve _ _ _ _ _ _ _ 244
133. Angle knife is shown in the sagittal plane ready for insertion under the middle turbinate _ _ _ _ _ _ _ _ _ _ _ _ _ _ _ 249
134. Shows the angle knife introduced between the septum and middle turbinate 251
135. Same as Fig. 134, with the difference that the knife has been passed the second time along the cribriform plate to a distance 1 cm. back of the first cut _ 252
136. Shows the knife introduced sagittally under the middle turbinate for the purpose of cutting into the capsule of the ethmoid _ _ _ _ _ _ 253
137. Shows the snare loop placed around part detached _ _ _ _ _ _ _ 254
138. Showing the line of amputation of the pendulous middle turbinate _ _ 255
139. Shows knife passed backward along cribriform plate penetrating anterior face of sphenoid at its top _ _ _ _ _ _ _ _ _ _ _ _ _ 257
140. Shows knife to have been reintroduced through uppermost part of sphenoidal cut as shown in Fig. 139 to posterior wall of cell _ _ _ _ 258
141. Knight-Leuder forceps _ _ _ _ _ _ _ _ _ _ _ _ _ _ _ _ _ 259
142. Shows the Knight-Leuder forceps introduced into the opening in the anterior face of the sphenoidal body ready to bite out of the anterior half of the floor of the body _ _ _ _ _ _ _ _ _ _ _ _ _ 259

Digitized by Illinois College of Optometry

FIG. PAGE

143. Shows the Knight forceps in position to bite out the post-ethmoidal wall which has been cut loose – – – – – – – – – – – – – – – – 260
144. Shows post-ethmoidal wall in grasp of forceps – – – – – – – – – 260
145. Shows a three-quarter view of specimen with operation completed – – 261
146. A three-quarter view of a post ethmoidal forceps made right and left – – 262
147. Spheniod knife; turbinate knife; turbinate knives made right and left – 263
148. Shows the knife in position for cutting away the uncinate process preparatory to Ingals' removal of the frontal sinus floor – – – – – – – 264
149. Shows knife approaching a post-ethmoidal cell which lies on the top of the sphenoidal sinus and occupies about one-half of the body of the sphenoid – 265
150. Shows the usual sphenoidal sinus and the usual cribriform plate with their usual relations – – – – – – – – – – – – – – – – – – 266
151. Showing the left half of specimen. Right sphenoidal sinus extending into left side to border left optic canal – – – – – – – – – – – – 267
152. Sphenoidal speculum – – – – – – – – – – – – – – – – – – 267
153. Sluder's upper cell operation. Showing proportions in a short nose – – 268
154. Sluder's upper cell operation. Showing proportions in a tall nose – – 269
155. Sensory fibers of the trigeminus and the facial nerves; sympathetic system in its course from the nasal ganglion downward, passing through the upper cervical ganglion (Color Plate) – – – – – – – – – – – 274
156. The author's intranasal forceps – – – – – – – – – – – – – – 305
157. Author's antrum operation. The lower turbinate has been detached with straight scissors at its anterior two-thirds, and pushed upward – – – 306
158. Author's antrum operation. Showing an ordinary septum elevator which has entered the perforation shown in Fig. 157 – – – – – – 306
159. Author's antrum operation. Shows a pair of scissors used to divide the membrane at its middle after it has been elevated as shown in Fig. 158 307
160. Author's antrum operation. Shows the special forceps shown in Fig. 156, one blade of which has been introduced into the antrum, the other under the nasal membrane already elevated – – – – – – – – – 307
161. Author's antrum operation. Showing the lower turbinate brought down into normal position. Gauze has been packed through the opening in order to turn the upper and lower membranous flaps into the antrum 308
162. Author's antrum operation. Shows the lower turbinate replaced – – – 309
163. Orbital abscess. Extension of the inflammatory process through the periosteum into the orbital fatty tissue – – – – – – – – – – – – 313
164. Eye chart – 364
165. Eye chart – 373
166. Eye chart – 374
167. Eye chart – 375

Digitized by Illinois College of Optometry

NASAL NEUROLOGY, HEADACHES AND EYE DISORDERS

CHAPTER I

AN INTRODUCTION REFERRING TO SOME POINTS IN THE MINUTE PATHOLOGICAL ANATOMY OF THE PROCESS

By Jonathan Wright, M.D.

The drawings illustrate very well many of the points in Dr. Sluder's study of the involvement of the superior accessory sinuses in pathological processes.

As a rule these have started from conditions very common in the nasal passages. Evidently these conditions from start to finish come well within the definition of chronic inflammation. So far as the bone changes are concerned the pathological condition is directly related to the normal processes of bone growth in the nose in its origin and throughout its whole course.

This relationship is not difficult to recognize. In the explanation which follows I only pretend to arrange them in sequence and to make application of certain well-known facts.

This explanation may appear all very elementary and perhaps unsuitable for introduction in this work. I have however become accustomed to look upon this sort of inflammation, and doubtless there are numerous other examples of the same principle, as due to the substitution of the stimulus of irritation, whether from external surface agents, from bacterial agents of disease within the surface or from systemic vasomotor disorders, for that mysterious physiological stimulus of growth which carries with it some agency which shapes the symmetry of form.

In the pathological processes that agent which shapes the symmetry of form is absent or works badly and we get unsymmetrical development in the hyperplastic irregular and pur-

Digitized by Illinois College of Optometry

poseless cavities in the rarefying bone processes which are exemplified in the specimens.

In order to illustrate the above remarks, which sum up my understanding of the nature of the metabolism of bone in health and in disease of the nasal structure, I have ventured in one figure, made up of a series of three sketches, to select from material other than that left by Dr. Sluder in my hands.

Fig. 1 consists of certain parts of several drawings in a work* published by Doctor Smith and myself. I have taken these out to illustrate the process as it occurs not only in the embryo and in early uterine life, but in the bone processes of chronic inflammation of the bony structure of the nose.

In the embryo and in the normally developing child and in the young adult this bone process is responsible for the hollowing out and the shaping of the various accessory cavities

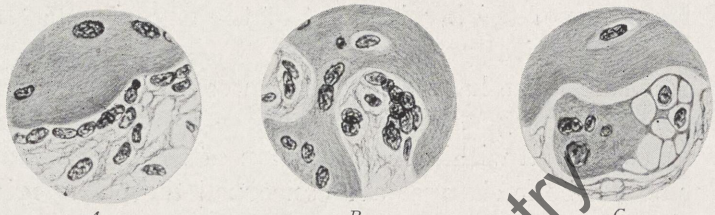

A *B* *C*

Fig. 1.—Composite drawing from Wright and Smith. *A*. Osteoblasts depositing bone salts. *B*. Transition stage. *C*. Osteoclast absorbing bone salts.

of the nose and it is also responsible for the maps, so to speak, of the turbinated bones, as they appear in transverse section.

In Fig. 1 it will be observed that *A* represents an edge of bone lined with ovoid cells, or osteoblasts, which are depositing lime salts in the formation of the bone structure. Much of the finer structure of all these sections has been destroyed by a decalcifying process. In the drawing *B* a locality has been chosen where the ovoid cells, or osteoblasts, are being grouped together; but they have not as yet lost the outlines of their limiting individual cell membranes. They are grouped together so that their peripheries, or external cell membranes, are touching one another. Subsequently, over the area of the surfaces which touch one another, these limiting membranes disappear, the cell bodies are thrown into one; and out of several mono-

*Wright, Jonathan, M.D., and Smith, Harmon, M.D.: A Textbook of the Diseases of the Nose and Throat, New York, Lea & Febiger, 1914.

Digitized by Illinois College of Optometry

nuclear osteoblasts, we have one large multinuclear giant cell, or osteoclast, shown in the drawing *C*.

With this change in cell form, brought about by a coalition, there results a change in the metabolism. The process is reversed. Bone salts are absorbed in place of being precipitated. What chemical change in the cells induces this reversal, it may be less difficult to imagine than the biological change which initiates it and of which the chemical change is only a

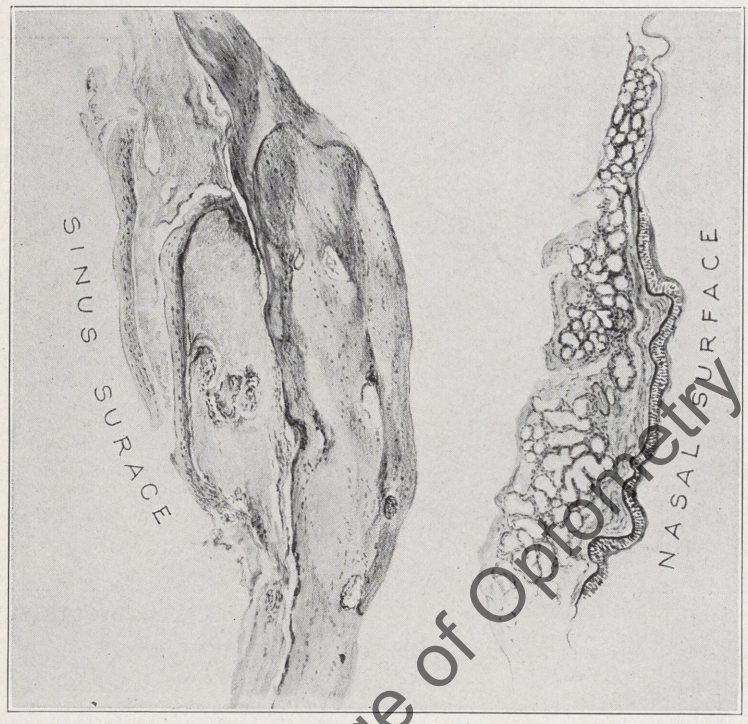

Fig. 2.—Hyperplasia of bone of sphenoethmoidal wall. (X 200, camera lucida.)

part. It is fair to assume that it is the physiological bone process by which nature shapes the framework of the body; but evidently there are other ways of giant cell formation, one of which is shown in Fig. 4.

In the material Doctor Sluder has left with me, I select that from Case 84,* which consists of pieces of the post-ethmoidal wall, to show in Fig. 2, a hyperplastic bone process. While other

*For Case Histories, see Chapter X, page 318.

Digitized by Illinois College of Optometry

localities in the same material show other conditions, it is strikingly evident we have here a thickening of the bone. The osteoblasts, not shown, of course, in the low-power magnification, beneath a thickened epithelium, have built up a solid wall of bone. If we turn now to the tissue from the sphenoidal wall in Case 86, we find that a rarefying osteitis, represented in Fig. 3, has been at work, perhaps in bony tissue which had been formed in the condition we have studied in Fig. 2. It is possible that the duration of the sinus diseases may have been longer in Case

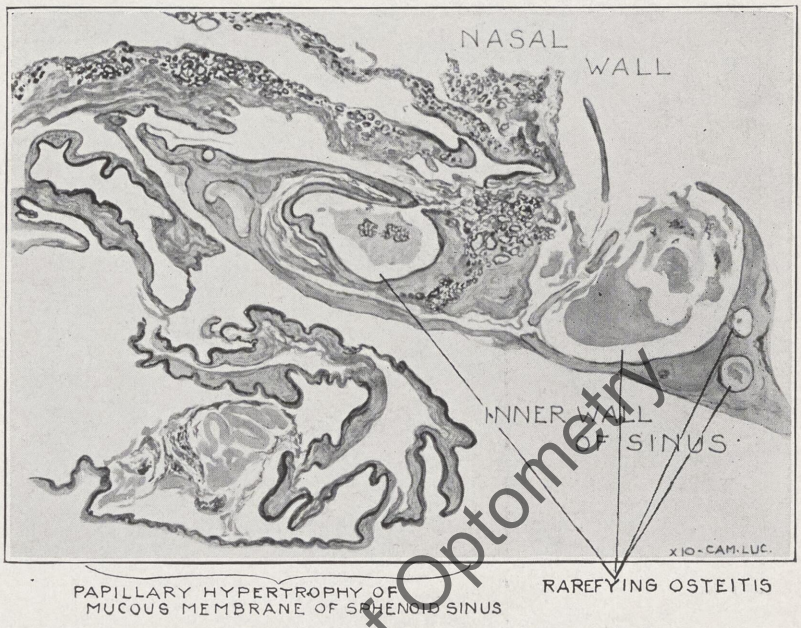

Fig. 3.—(X 10, camera lucida.)

86 (Fig. 3) than in Case 84 (Fig. 2), but that is not necessarily so. We perceive, however, in Fig. 3, the papillary hypertrophy of the mucous membrane lining the cavity, which is so common in these old cases, usually suppurative, of sinus disease.

The drawings (Figs. 2 and 3) have been made with camera lucida, from appearances under very low magnifications.

I select from Case 66, a field (Fig. 4), made under high magnification, admirably adapted to act as a companion piece to the partially schematic drawings in Fig. 1. A careful study of it will reveal a number of osteoclasts, or giant cells, varying

Digitized by Illinois College of Optometry

from indeterminate binuclear affairs up to the large multinuclear cell seen in close juxtaposition to the edge of the bone.

This cluster of osteoclasts seems to have indented the surface of the bone by virtue of their bone-absorbing functions. In the normal process of cavity formation, the sinuses grow in capacity by virtue of this activity of the osteoclasts. In almost the same locality of a single specimen of the pathological process, we may have both this absorption, or osteoclastic

Fig. 4.—Rarefying osteitis. ($\frac{1}{12}$ 0. imm.) Showing action of osteoclasts.

activity, and the bone-forming, or osteoblastic activity going on. Where the bone formation along one surface goes on at the same time that bone absorption goes on along the other surface of the anterior part of the middle turbinate bone, we occasionally get the formation of a bony cyst. I have remarked that the method of osteoclast, or giant cell formation, as exhibited in Fig. 1, is not always the apparent method of genesis. Occasionally the evidence suggests, as it does here in Fig. 4, that the giant cell grows, not by apposition of separate cell bodies, but by the

Digitized by Illinois College of Optometry

multiplication or proliferation of nuclei, beginning in a single cell.

It now remains for me to show in Figs. 5 and 6, drawn from the specimen of the middle turbinate bone from Case 12, how this bone process starts as a sequence of an ordinary hyperplasia of the mucous membrane of a turbinate body. In Fig. 6, you will see this typical hypertrophy represented under the high power at a point (*C*) selected from the structure shown under low power in Fig. 5. There is only one thing ex-

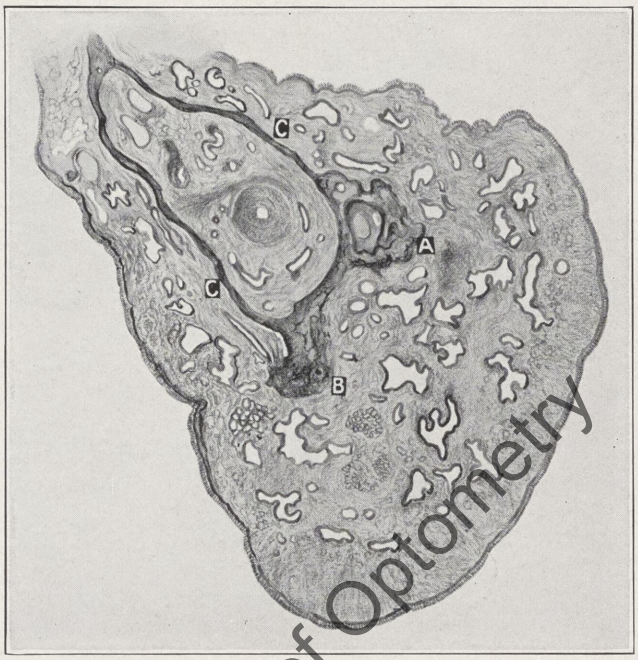

Fig. 5.—Chronic hypertrophy of middle turbinate body. (X 10, camera lucida). *A. B.* Showing osteophytic growth. *C.* Fibrous hyperplasia at points from which Fig. 6 was made with high power.

ceptional in the picture presented by the latter. You will see at *A* and *B* an osteophytic process starting at the edges of the middle turbinate bone, with suggestions of the existence already in the newly formed low-grade bone of a rarefying process. Now this new activity is representative of how a tissue change, which we know begins in the soft parts, inaugurates a tissue change in bone, which when arising in a locality channelled by sensitive nerves or nerves of special sense, leads to

Digitized by Illinois College of Optometry

distressing symptoms and grave consequences; but on a middle turbinate bone hanging free in a nasal cavity, nothing of vital importance usually results.

In Dr. Sluder's cases, then, it is not the specificity of pathological activity which engages our clinical attention, but the specificity of locality.

It would probably be difficult to find an adult individual in temperate or cold climates who does not present an example

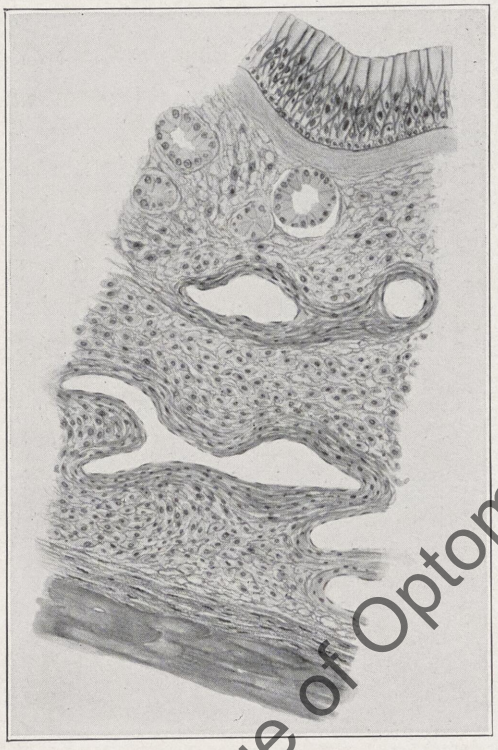

Fig. 6.—Chronic hypertrophy of middle turbinate body. (X 500.) Taken from a section shown in Fig. 5 at *C*.

of this bone change within his nasal chambers, which we have a right to call pathological. It is only exceptionally that the symptoms to which it gives rise are sufficient to cause him to seek relief. When, however, it causes bony occlusion of a nasal fossa by means of a spur or deviation, when it stops up the ostium of an accessory nasal sinus and prevents proper drainage, when it impinges on a branch of a sensitive nerve or

Digitized by Illinois College of Optometry

involves its peripheral distribution, marked symptoms and a long train of the consequences may ensue, which Dr. Sluder describes.

When in the walls of the sphenoidal or ethmoidal sinus there is involvement of the optic nerve, in so far as it depends on bony pressure, blindness, partial or complete, is pretty sure to occur. When, however, the alarming symptoms of optic involvement are recent and slight, the trouble may not be due to a bony pressure, but to a pressure of soft parts, or to an extension of their inflammation or of their vascular congestion. These latter conditions may be relieved by giving free drainage and ventilation to an occluded sinus; but in an inaccessible region, if there is pressure of a bony surface, such as the swelling, in Fig. 2, upon a sensitive or an optic nerve, it is difficult to see how the symptoms are to be relieved. Fortunately, there is good reason to believe that in the nature of things, the encroachment of the field of engorgement and soft hyperplasia upon the nerve structures gives a timely warning so that surgical interference is possible before an irreparable condition results.

It is perhaps well to remark that we have sought some objective evidence of inflammation spreading along the sheath of the optic nerves from the foci of inflammation in the sinuses. Though there is clinical reason to suppose this sometimes occurs, we have not as yet secured objective proof of it in the material at our disposal.*

*A very excellent piece of pathologico-anatomical work on the post-nasal tissues has been done by Bernard J. McMahon. He remarks that chronic hyperplastic sphenoethmoidal sinusitis is a definite clinical entity in which the operative results are attended with a high percentage of improvment or complete recovery (74.3 per cent). My (Sluder) impression is that the percentage is very much higher, although I am unable to give the exact figures.

Digitized by Illinois College of Optometry

CHAPTER II

THE NOSE

A General Consideration

The nose seems to me an anatomical and clinical region that has special features to be considered (that are self-evident as soon as thought is directed to them) which, so far as I know, have not been emphasized even in this day of highly specialized specialties.

First, the nose, as the most protruding feature of the face, is exposed to injury far more than the rest of the face, as has often been remarked. Falls and blows readily injure the nose, that do not harm the eyes or teeth; and probably during birth the nose is often injured despite its then elastic, pliable consistency. This seems the only etiology for the dislocation of the anterior part of the septum from the V of the wings of the premaxillary bones, giving rise to a deflected septum in patients who have never had an injury. Mosher[1*] has given us this anatomy comprehensively. A slightly deflected septum may seem clinically negligible, but later in life gives rise to the low grade vacuum headache with asthenopia.

Second, in the human being the nose has two paranasal cells that have no gravity drain, to wit, the maxillary and the sphenoidal cells, which is a great disadvantage. To these may be added possibly some of the ethmoidal cells. Infection in these cells, which leads to suppuration, is therefore less apt to subside spontaneously than in the frontal sinus when the outlet (or inlet) to it is normal; but here the normal is so easily disturbed as also to be striking. In the animal that spends much of its life with its nose pointing more or less to the earth these sinuses have a gravity drain.

Since the formation and function of the sinuses will not be considered in detail here the observations of A. W. Proetz[1] are indeed worthy of note. He freely discusses some of the various

*References are arranged alphabetically at end of book, page 403. Superior numbers represent the number of the article by the given author.

Digitized by Illinois College of Optometry

theories which have been advanced to explain the presence of the nasal sinuses. While he maintains that there is a grain of truth in each of the theories, none of them in itself is sufficient to explain the presence of the rather complicated arrangement and the irregularities in shape and size of the sinuses. Proetz has advanced the theory and has presented convincing evidence that the face plays an essential part in their development. In his conclusions he states that nowhere else in the skeleton do we find the requirements of disproportionate growth of the ossification that exists in the skull and are met by the formation of the sinuses. To summarize he remarks that: (1) "The nasal accessory sinuses and the mastoid are apparently the result of a plastic rearrangement of the skull necessitated by the disproportionate growth of the face and cranium and associated structures after they are fully or partly ossified." (2) "They are cavities left by the separation of two walls of a bone." (3) "They must communicate with the external air to avoid physical disturbances; they do this by communication with the nearest existing air cavity (from which they arise); they are lined for this reason with the membrane of the cavity from which they arise."

Third, the upper air passage from birth to death is subjected to recurrent severe inflammatory attacks (coryzas) which usually have no analogue or homologue in any other part of the body. These attacks bring about changes in other parts of the upper air passages as well as in the nose. In the nose the periosteum is in peculiarly close relation to the membrane which is so frequently subjected to this inflammatory attack. In most other parts of the body the periosteum is separated from its coverings by loose connective tissue which permits of much inflammation of the coverings without involvement of it.

Fourth, most of the cranial nerves leave the skull through close fitting bony foramina, except those which pass through the sphenoidal fissure (the oculomotorius, trochlearis, abducens, and ophthalmicus). The opticus, maxillaris and Vidius pass through foramina or canals in the sphenoid in a part of the nose which is subject to the pernicious influences that beset the other parts of the nose. These nerves represent the special sense of sight, as well as the motor, sensory and involuntary systems. The fre-

Digitized by Illinois College of Optometry

quency of lesions of the optic, maxillary and Vidian nerves is at once striking when compared to the infrequency of lesions of the other cranial nerves. The oculomotor, trochlear, abducent, and ophthalmic nerves in the sphenoidal fissure are also associated with a part of the sphenoid which is often a part of the nose, but less intimately as a rule, for two reasons—first, because the sphenoidal sinus is only sometimes prolonged into the great wing (not as a rule—if there be any rule for the anatomy of the nose) and secondly, they are not confined here in tight fitting bony foramina—they have loose connective tissue around them. The sphenoidal sinus sometimes extends to the foramen ovale and to the semilunar ganglion also, as well as into the great wing, but only seldom. The nerves in the sphenoidal fissure, even though they are surrounded by loose connective tissue, are more often involved (from the nose) than the cranial nerves which are totally removed from the nasal anatomy. Furthermore, these nerve complications are greatly increased by the presence of the nasal (sphenopalatine—Meckel's) ganglion, lying almost submucous to the nose. It is, moreover, situated in a fossa (sphenomaxillary) which is in many respects tantamount to a paranasal cell. In no other part of the body is an involuntary ganglion or sensory ganglion so exposed to surface influences. These facts bring these associated nerves with all the various questions arising with them, to wit, headaches and eye disorders, and neurological phenomena, with all that these maladies may mean in the life of the patient, into the concern of the rhinologist. They are also, of course, matters of concern for the neurological surgeon. Here the two fields overlap intimately. Each, therefore, needs the cooperation of the other to avoid errors in diagnosis. These facts also make the field of the rhinologist overlap that of the ophthalmologist, and here also each needs the cooperation of the other to avoid error. And the same reasons make the field of the rhinologist overlap that of the internist; nasal headaches must be differentiated from those of the various systemic disorders. The neck and shoulder pains of some nasal diseases call into question the orthopedic problems of these parts; and the dizziness of some nasal disturbances requires all the acumen of the internist, neurologist, aurist, and rhinologist for its differentiation. I have tried to

Digitized by Illinois College of Optometry

determine whether the hypophysis is not sometimes disturbed by nasal inflammation, but so far I have not been able to draw conclusions. Citelli has described what he believes are such disturbances. The paranasal cells are often the source of infections (focal infections) which supply organisms that are active in other parts of the body. It is unfortunate for rhinology that the nose in animals is not better adapted to experimentation.

Headache, whether it be seldom, or frequently recurrent, and bear the names "Megrim," "Bilious-headache," "Blind" or "Sick-headache" or "Hemicrania," like all other pain, according to present thought, must be a symptom of a lesion of some kind, whether a pathological-histological change, or a toxemia, be (at present) recognized as its cause. Just so it would seem that weak eyes (asthenopia) must be a symptom of a lesion, whether its nature be known now or not, and optic neuritis, optic atrophy, retinitis and choroiditis must have causes underlying them. In these fields, as in the domain of "hysteria," "neurasthenia" and "syphilis," the number of cases left in the categories of "migraine," "asthenopia," "idiopathic optic neuritis" and "idiopathic atrophy" becomes smaller with each advance in our understanding of deeper lying facts.

Recurrent headache when at all severe (or even when slight) in the course of time becomes a matter of serious moment for the individual; and with the higher grades, is the cause of so much disaster both in his affairs and to the general welfare of the family, that from the earliest times to the present hour it has had the serious efforts of some of the best minds bestowed upon the solution of its causes and treatment. To this end, many famous monographs have been written; and special chapters in all kinds of treatises and textbooks, with countless journal articles have been directed to the better understanding and treatment of this symptom.

Headache of any grade is a symptom in many diseases that are at once, or easily, recognizable; and in the course of which, it needs no more than the merest passing mention. These are self-limiting by either recovery or death in a period of time that represents proportionately a short span in the life of the individual. But headache is also a symptom of another disease or class of morbid conditions which present *no signs;* of which

Digitized by Illinois College of Optometry

it may be the *only symptom;* and which are *not self-limiting* by recovery or death but persist throughout the life of the individual from childhood to old age, and yet permit him to live the "allotted time of man." It is this class of headaches that in earlier times were considered diseases *per se.* Hippocrates did not differentiate the headaches. The first to do this was Aretaeus of Cappadocia in the second century A.D. Galen in that century, aside from their description, advanced a theory for their explanation, based on the Humoral-pathology of Hippocrates. This remained practically unchanged until the Renaissance, since which time many theories* have been advanced.†

It has been my opinion for twenty years or more that many, if not all of the diseases that produce this symptom and at the same time let the patient live his life to fullness of years and in health otherwise, are some kind of a disorder that involves the nerves independent of the brain centres, that its mechanism is a local one. I have recently found that this theory is far from original with me, that it was advanced by Laborroque in 1837 and Symonds in 1858. My ideas differ from theirs, however, in some essentials, as will appear.

Contributory to this class, is the large subclass of ocular headaches which may endure as long as the ocular defect remains unrectified, and the large subclass of nasal headaches which may recur indefinitely, caused by suppurations of the various paranasal cells. Both of these classes have been described by many of the master minds of our times and much wondrous, admirable surgical technic has been evolved for their relief.‡

The study of the severe headaches by the authors of the many superlative monographs has included the local causes of the eye, ear and nose ever since the understanding of these organs began to be comprehensive. The eye through Helmholtz's discovery of the ophthalmoscope was the first to be better understood. The ear also was the object of special study and understanding; and special study of the anatomy of the nose and the

*Dubois Raymond, Mollendorf, Laborroque, Piorry, etc. Quoted by E. Liveing: On Megrim, Sick Headache, etc., London, 1873.

†Extensive historical references are to be found in many of the monographs on Headache or Megrim, notably E. Liveing, L. Thomas, Harry Campbell, E. Flatau, J. P. Moebius.

‡In the list of these procedures stand conspicuous the Ingals, the Watson-Williams, the Halle, intranasal frontal, the Hajek[4] ethmoidal-sphenoidal, the Mosher[1] frontal-ethmoidal-sphenoidal, the Mikulicz and the Denker maxillary, the Killian[1] external frontal and the Caldwell-Luc external maxillary operations.

Digitized by Illinois College of Optometry

discovery of cocaine have done much to rank rhinology with ophthalmology; and latterly the ear is much better understood. Through the development of these specialties the classes of asthenopia, idiopathic optic neuritis and idiopathic headaches have been greatly narrowed.

It is my desire here to assemble the descriptions of some nasal lesions which give rise to these conditions without the gross symptoms or signs that betray the nasal origin of the primary lesion. The well-known, almost self-evident paranasal sinus suppurations, as well as the many systemic and central nerve causes for headaches and the various eye disorders, will not be considered here more than to be incidentally mentioned when a purpose is to be subserved.

Perusal of the literature on the subject of headaches reveals that the terms Megrim (Migrain, Migraene), Sick Headache, Bilious Headache, Blind Headache, Hemicrania, as used by Liveing, are accepted as synonymous by most writers on the subject.* Liveing cites cases to show that they are complete or incomplete pictures of the same disorder. It seems to me that my cases will also bear out this argument.

It is the purpose of this essay to describe six varieties of nasal disease or clinical pictures which have as symptoms, (1) headache, (2) more or less eye disorder, (3) neurological phenomena that are evidently of nasal origin or are controllable by nasal treatment: to wit, (1) closure of the frontal sinus without suppuration; (2) anterior ethmoidal (nasociliary) neuralgia; (3) the syndrome of nasal ganglion neurosis (lower half headache); (4) the picture of hyperplastic post-ethmoidal-sphenoidal inflammation; (5) some neurological phenomena that are apparently not of nasal origin and are controllable by nasal treatment; and (6) orbital phlegmon.

*E. Liveing, Purves Stewart, Harry Campbell, J. P. Moebius, Flatau, Gowers.

Digitized by Illinois College of Optometry

CHAPTER III

VACUUM FRONTAL HEADACHES WITH EYE SYMPTOMS ONLY

A low grade, unending headache is established by closure of the frontal sinus, without nasal symptoms or signs, i. e., obstruction or secretion, and is made worse by use of the eyes. These patients have ocular symptoms only. The air is partly

Fig. 7.—Showing where needle has been passed through the floor of the frontal sinus at the point of attachment of the pulley of the superior oblique.

absorbed in the sinus and the negative pressure causes the walls to be sensitive.* The floor of the sinus is its thinnest wall and has attached to it the pulley of the superior oblique. (Figs. 7 and 8.) The sensitive floor is pulled on by use of the eyes. I once (Sluder and Ewing, 1900[2]) thought that the closure of the sinus was an accident of the anatomy. I now believe that this is

*I have recently found that this idea was advanced prior to 1900 by P. McBride[2] (1891).

Digitized by Illinois College of Optometry

rare although possible. The mechanism by which closure is produced is a combination of *unfavorable anatomical settings* such as narrow noses present, *plus hyperplastic changes in the soft parts and the bone.* (Compare Doctor Wright's introduction.)

In this class of cases pus is never found in the nose; the severe pain produced by suppurating sinuses is lacking; and there are no complications such as blindness and changes within the globe. The eye disturbance is of the nature of "asthenopia." These are almost always cases of closed frontal sinuses which are otherwise normal. Occasionally it is the anterior ethmoidal labyrinth that has become closed. I have not been able to deter-

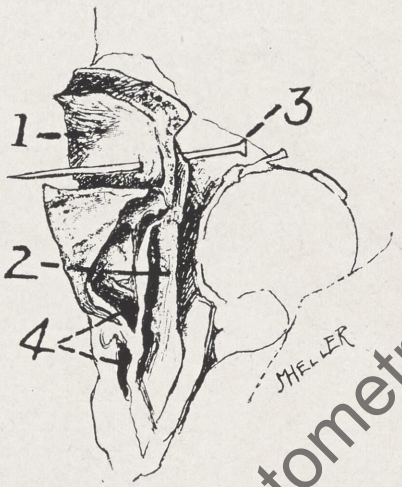

Fig. 8.—Showing a dissection of the right orbit from above. *1.* Frontal sinus. *2.* Superior oblique muscle. *3.* Pin passed from orbit into frontal sinus at point of attachment of pulley of superior oblique. *4.* Ethmoidal cells.

mine that contacts of one part of the lateral wall with the septum are ever responsible for similar symptoms. (This opinion is contrary to the statements of some writers.)

It is my wish in this chapter to classify from a rhinologic standpoint, the origin of this class of cases, which was first described in two papers presented by Dr. A. E. Ewing and by me before the American Ophthalmological Society, May 2, 1900.[2]

Ewing was the first to recognize these cases and to describe the symptoms, which briefly are: "Inability to use the eyes for near work because of the *headache* which is produced thereby,

Digitized by Illinois College of Optometry

and which is not relieved by glasses or eye treatment." They are accompanied by a tender point in the upper inner angle of the orbit (Ewing's Sign).

This class of cases is as a rule not accompanied by nose symptoms, unless they be produced by some lesion other than the one closing the sinus. Occasionally there is some obstruction to breathing, because of a narrow nose.

CLINICAL PICTURE

The headache is frontal, usually; very rarely is it referred to the external angular process of the frontal bone. It is frequently present on arising, but grows worse on using the eyes; or is brought on by use of the eyes. The pain never reaches the intense degree of that produced by a confined empyema, but is quite sufficient to prevent the use of the eyes. Occasionally a patient relates that "blowing his nose is sometimes accompanied by a squeaking sound and the sensation of air running up into his brain," which is followed very soon by temporary relief of the discomfort.

J. Parsons Schaeffer[3] reported a frontal sinus infection that extended backward, finally into both sinus wings and into the temporal bone. Vacuum headache in such a case would be of far wider distribution.

EWING'S SIGN

The nasal trouble in these cases is revealed by tenderness of the upper inner angle of the orbit at the point of attachment of the pulley of the superior oblique, and *internal* and *posterior* to it. (Fig. 9.) This is the portion of the orbit which is formed by the frontal sinus, the wall of which at this site is thinnest. Kuhnt observed that in empyema of the frontal sinus this was an exceedingly sensitive area, and suggested that this tenderness was in the supratrochlear nerves which were inflamed because of their juxtaposition. As a matter of fact, it is at a point in the bone where the nerves are absent.[36] It should be remembered that Ewing[1] put forth this sign as a diagnostic help for cases which had up to that time been declared not frontal sinus cases, not nasal cases at all, because there were no nose symp-

Digitized by Illinois College of Optometry

toms, nor any pus, nor secretion from the sinus, nor any of the grosser commonplace anatomical changes. This sign is sometimes the *only* indication of the nasal trouble, the rhinologist's findings being negative.

The frontal sinus is most frequently the one involved because of the peculiar anatomy of its outlet (or inlet). *Rarely is the anterior ethmoidal labyrinth* the one involved, and then the symptoms are different; the tenderness is at the site of the *lacrimal bone.* Patients affected in this way have the sensation of sand in the eyes, and refer the pain to "behind the eyes."

Fig. 9.—Showing a needle passed from frontal sinus at a point back of the attachment of the pulley of the superior oblique. This is the author's favorite point for eliciting "Ewing's sign." Dr. Ewing prefers the point of attachment of the pulley.

The posterior ethmoidal labyrinth and the sphenoid, in my opinion, never give rise to these symptoms. They may give rise to occipital, parietal or frontal headache, or headache brought on by the use of the eyes because some of the ocular muscles arise in the apex of the orbit from parts formed by the walls of these sinuses; or to blindness by reason of their nearness to the optic nerve; but never to this enduring low grade frontal pain with inability to use the eyes, *accompanied by Ewing's sign.*

Digitized by Illinois College of Optometry

Twenty-three years' observation of this class of cases leads me to believe Ewing's sign to be trustworthy and almost constant. The rare exception is in the case of the sinus having very thick walls, when the bones of the individual will in general be found to be very heavy and thick. Under these conditions I have found it absent even in acute empyema of the sinus accompanied by severe pain.

GROSS ETIOLOGY

In 1900 I (Sluder and Ewing[2]) stated that I believed the tenderness of the wall of the frontal sinus arises secondarily to closure of its outlet, and that a similar condition obtains here to that produced in the middle ear by a sudden closure of the eustachian tube. Many years ago this was recognized as a condition in which the oxygen of the enclosed air was absorbed and a negative pressure, a partial vacuum, established within the cavity. Brawley concurs in this opinion of the mechanism of the frontal pain. I still believe this is the correct explanation, and that secondarily to the closure of the sinus, arises a congestion of the lining membrane in which the bone takes part to a degree which, however slight, is sufficient to render the thin wall of the sinus sensitive to external pressure—even to very slight pressure. The pulley of the superior oblique is attached to this thin wall. The function of this muscle being to turn the eye downward and inward, it is called into use for most of the acts of accommodation. So for close work there continues, more or less, a tugging at this tender point. This intensifies the dull ache caused by the simple closure of the sinus. In cases of slight severity the patient is not especially uncomfortable until he begins using his eyes for close work.

The frontal sinus is the one by far most frequently the cause of this headache; according to my experience it being the origin of about 99 per cent of these cases. The attempt to classify the origins of these cases resolves itself, therefore, into a reference to the frontal sinus to that extent. For the present I shall neglect the other sinuses. In 1900 I made no effort to do more than mention the ways in which the outlet might become closed. I did not report cases. I felt that my number of cases was too small. My material now comprises

Digitized by Illinois College of Optometry

more than 580 cases. These were nonsuppurative at the time they came under observation; and never at any time showed pus in the nose, nor did transillumination or x-ray examination show any clouding.

X-ray plates of the sinuses in cases of vacuum headache are usually negative. Sometimes, however, the affected side shows a cloudiness which disappears after the sinus is opened for ventilation. This clouding may reappear when the outlet from the sinus becomes closed, as during an acute coryza or from some other cause.

ANATOMY OF THE MIDDLE MEATUS

Familiarity with the anatomical detail of the middle meatus is necessary for a comprehensive understanding of this class of cases.

The Correlated Anatomy of the Middle Meatus of the Nose

These patients *usually* have narrow nasal fossae.

Closure of the frontal sinus outlet or *inlet* may be brought about rather easily by a number of causes on account of the anatomical peculiarities. It has always seemed to me that a comprehensive understanding of the middle meatus (which is the beginning of the inlet) would have to come through a correlative study of the district. In this way only, can an understanding of the workings of this region be had. These anatomical observations relate to the anterior ethmoidal cells also.

The extant anatomical descriptions of the parts of the middle meatus and its paranasal cells and their means of communication with it, as well as the terms employed, are so various that an effort to synonymize them would be difficult if indeed possible. This arises probably from the fact that the various observers have each seen the parts variously, together with the difficulty anatomists have (apparently) had in understanding each other's description. Heymann and Ritter in a masterful presentation of the entire set of questions, with the confusions besetting this district, have systematized them for a comprehensive understanding and catalogued their variations. The term Infundibulum was introduced by Boyer in

Digitized by Illinois College of Optometry

1803 to designate the flattened funnel-shaped uppermost part of the middle meatus leading into the frontal sinus, which in its simplest arrangement passes directly between the uncinate process in front and ethmoidal bulla behind, i. e., smoothly, directly upward from the hiatus semilunaris, uncomplicated by pocketings, cells, or diverticula in any direction. (Boyer interpreted the infundibulum as an ethmoidal cell.) This then means that as long as the neck of funnel runs in parallel lines it is the hiatus semilunaris and as soon as its lines diverge it becomes the infundibulum. This is the construction and acceptation that the B. N. A.* puts upon this district. These were also the ideas of Zuckerkandl,[2] A. Logan Turner, and Mihalkovics. This complete flattened-funnel (cone and neck) is smoothly lined. But this smooth-lined funnel is varied in many

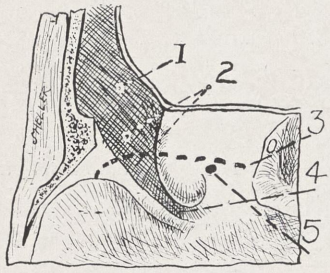

Fig. 10.—Showing hiatus semilunaris, infundibulum and frontal sinus in direct and uncomplicated connection. *1* Frontal sinus. *2*. Infundibulum. *3*. Line of attachment of middle turbinate. *4*. Hiatus semilunaris. *5*. Normal outlet on anterior ethmoidal cells.

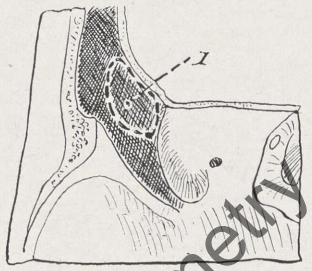

Fig. 11.—Showing ethmoidal cell entering infundibulum from above and behind. *1*. Ethmoidal cell.

ways by pocketings or cells developing anteriorly, laterally, superiorly and posteriorly from both infundibulum and hiatus, and by the hiatus becoming disjointed as it were from the infundibulum. These variations were also observed by Boyer. Heymann and Ritter have apparently taken the view that the simple smooth-lined funnel does not exist and have started with the next simple arrangement, that of the cone and neck (infundibulum and hiatus) being slightly disjointed. They have then shown all the variations in logical sequence, so clear is their systematizing of the district. Figs. 10 to 17 show diagram-

*Basle Anatomical Nomenclature (Barker).

Digitized by Illinois College of Optometry

matically the commonplace variations in the scheme of these parts. Fig. 31 shows a specimen in which there is no expanse of the breadth of the hiatus semilunaris at any point. It communicates with the frontal sinus by a pipe-like channel which has become more nearly horizontal, but not any wider. A large ethmoidal cell enters this channel from below and in front. J. Parsons Schaeffer[2] has depicted the anatomy of this region of the nose in a convincing manner. He has given it from fetal

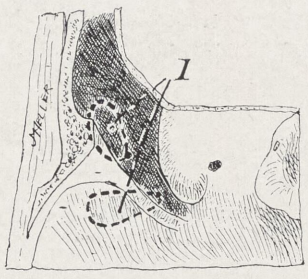

Fig. 12.—Showing ethmoidal cells entering infundibulum and hiatus semilunaris from above and below in front. *1.* Ethmoidal cells.

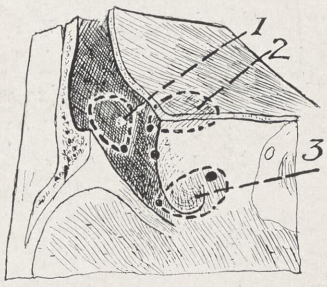

Fig. 13.—Showing ethmoidal cells entering infundibulum and hiatus semilunaris from above in front and behind and below. *1-2-3.* Infundibulum and hiatus cells.

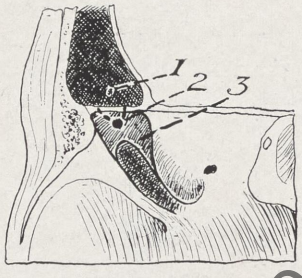

Fig. 14.—Showing hiatus semilunaris ending in blind pocket above, infundibulum limited above by roof of nose. Frontal sinus entering infundibulum from above and laterally. *1.* Frontal sinus. *2.* Outlet of frontal sinus. *3.* Infundibulum.

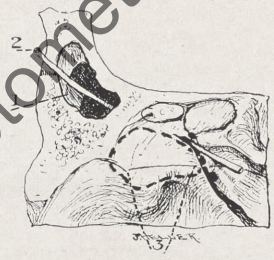

Fig. 15.—*1.* Frontal sinus. *2.* Bristle passed from frontal sinus into hiatus semilunaris. (Note that it takes a much more horizontal direction than usual.) *3.* A large hiatus cell of the ethmoid.

life on through its complete development and also its variations. His pictures are the most beautiful and detailed of any extant. He and the *American Journal of Anatomy* have given their consent to my reproducing them. They are represented by Figs. 18 to 30.

Digitized by Illinois College of Optometry

As a rule anatomists have described the way the frontal sinus communicates with the middle meatus. For my purpose it is advantageous to emphasize the way the middle meatus communicates with the frontal sinus.

The means of communication of the middle meatus with the frontal sinus are primarily from the "vault" of the middle meatus through or by way of its "frontal pouch." What-

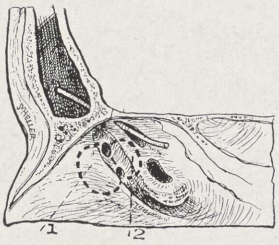

Fig. 16.—Showing (*1* and *2*) ethmoidal cells opening into hiatus semilunaris which ends above in a blind pocket. The frontal sinus enters the nose at a point above and behind the hiatus semilunaris as shown by bristle in position.

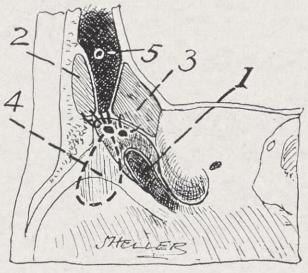

Fig. 17.—Showing hiatus semilunaris ending in blind pocket above. *1.* Hiatus semilunaris. *2-3-4.* Ethmoidal cells entering infundibulum from above, in front and behind, and from above and laterally in common with lower ethmoidal cell *4*. *5,* Entrance of frontal sinus.

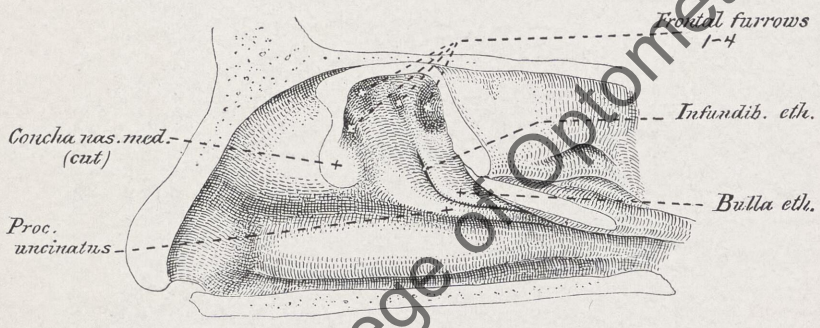

Fig. 18.—From a term fetus. The recessus frontalis is exposed for study by the removal of the operculating concha nasalis media. Note the frontal furrows and the relations of the infundibulum ethmoidale. Compare with Fig. 23. (J. P. Schaeffer.)

ever may be the further (upper) subdivision of the passway, i. e., hiatus semilunaris, infundibulum, nasofrontal duct, the start from below is, under the middle turbinate into the "vault" which is pouched upward at a point in the anterior third.

"Vault" is a term that I employ to designate the entire

Digitized by Illinois College of Optometry

uppermost extent of the middle meatus. At the junction of the anterior with the middle third of this space it extends upward, pocket-like, to eventually communicate with the frontal sinus. This particular district it seems to me may be advantageously termed the *frontal pouch* of the *vault* of the middle meatus.

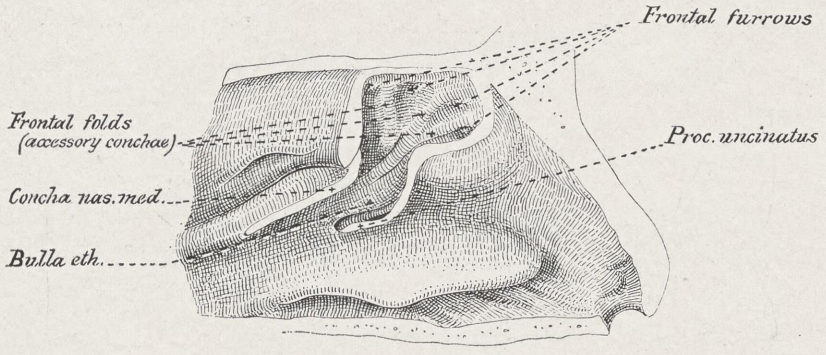

Fig. 19.—From a term fetus. Recessus frontalis exposed. Note frontal furrows and folds. Especially note the continuity of the suprabullar furrow and the fourth (most dorsal) frontal furrow. The infundibulum ethmoidale is in line with the first frontal furrow, but not directly continuous with it. (J. P. Schaeffer.)

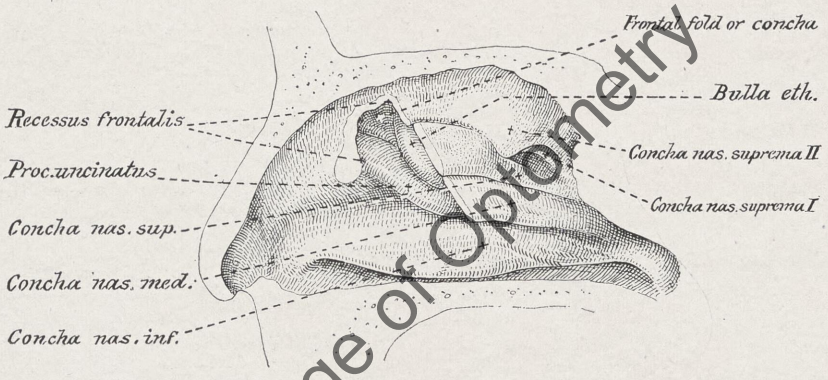

Fig. 20.—From a term fetus. Here a single frontal fold or concha presents, bordered by a dorsal and a ventral frontal furrow. The infundibulum ethmoidale and the frontal furrows are continuous channels. Whether this is a secondary condition due to growth, i. e., whether the frontal furrows and the infundibulum ethmoidale were discontinuous anlagen, cannot be said. According to my series the condition is not common. (J. P. Schaeffer.)

This pouch has been observed and named by Killian[2] "recessus frontalis," and by Mihalkovics "recessus meatus medii" (Tasche des mittleren Nasenganges). Its association with the remaining vault has not been described. At about the middle

Digitized by Illinois College of Optometry

of the vault, behind and above the bulla, is a similar smaller pouch which communicates with the anterior ethmoidal outlet or *inlet*, which may be termed the *ethmoidal pouch* of the vault

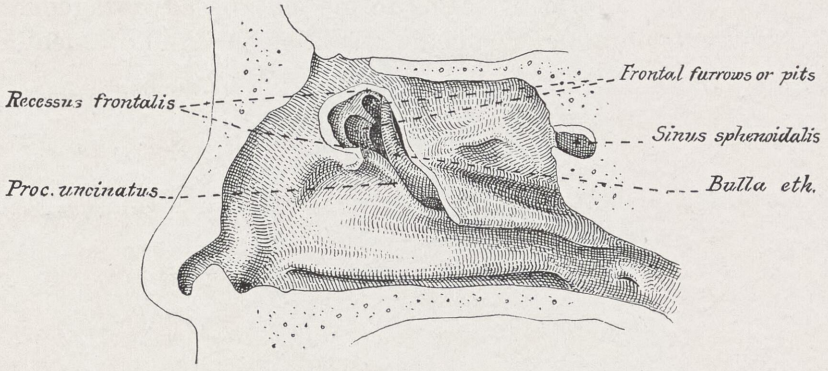

Fig. 21.—From a term fetus. Recessus frontalis exposed by partial removal of concha nasalis media. Note intimate relationship between ventral extremity of the infundibulum ethmoidale and the second or most dorsal frontal furrow or pit. Should the sinus frontalis develop from the second frontal furrow, the adult relationship between the former and the infundibulum ethmoidale would be very intimate. Indeed, there might be direct continuity, allowing for further changes in development. The conclusion would be wrongly drawn, however, to say that the sinus frontalis is a derivative of the infudibulum ethmoidale. (J. P. Schaeffer.)

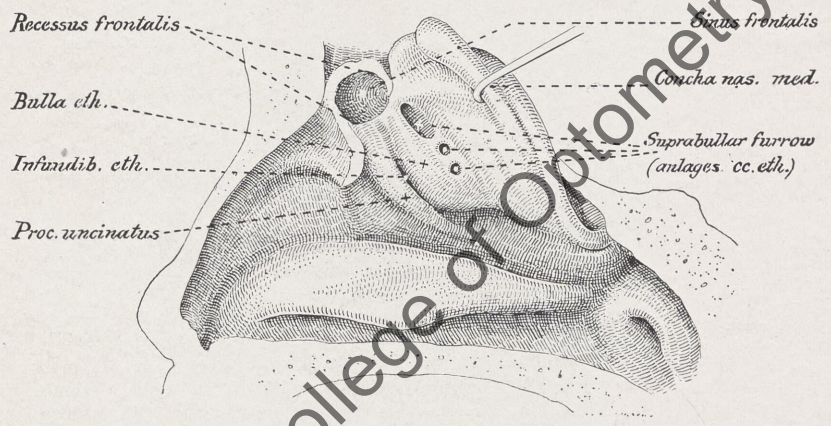

Fig. 22.—From a child aged fourteen months. Note the apparent absence of frontal furrows and folds. The whole recessus frontalis is expanding or growing frontalward in the establishment of the sinus frontalis. (J. P. Schaeffer.)

of the middle meatus. The frontal pouch is usually not only larger but extends higher than the ethmoidal pouch. For the maintenance of these pouches and their communication with the middle meatus, it is necessary that the middle turbinate

Digitized by Illinois College of Optometry

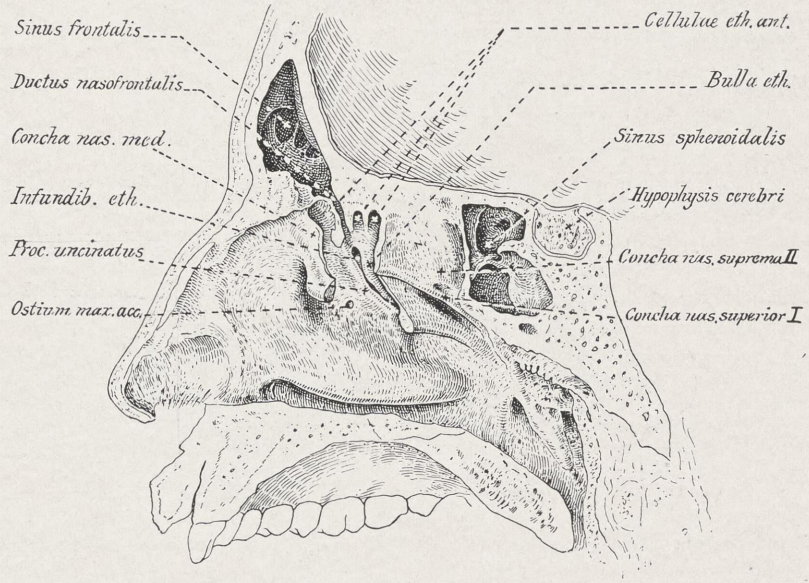

Fig. 23.—From an adult. Recessus frontalis and nasofrontal connections exposed for study by the removal of part of the concha nasalis media. (J. P. Schaeffer.)

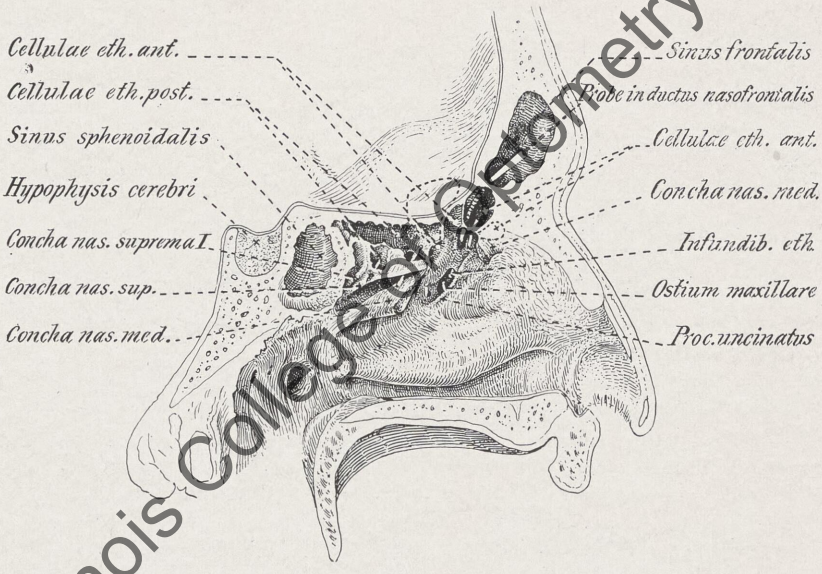

Fig. 24.—From an adult. Recessus frontalis and nasofrontal connections exposed for study. Especially note the derivatives of the frontal pits, the tortuous and narrow ductus nasofrontalis, and the termination of the ventral extremity of the infundibulum ethmoidale. (J. P. Schaeffer.)

Digitized by Illinois College of Optometry

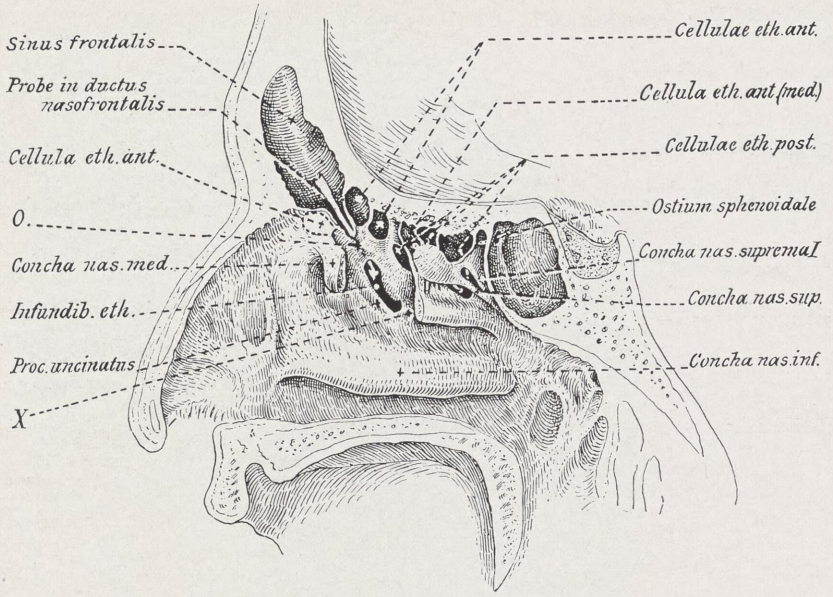

Fig. 25.—From an adult. Dissection shows the nasofrontal connections and the ethmoidal labyrinth exposed. Especially note the derivatives of the frontal pits and the direct continuity of the sinus frontalis with the infundibulum ethmoidale. The dorsal blind end of the infundibulum ethmoidale, due to the mucosal fold (*X*) passing from the free border of the processus uncinatus to the bulla ethmoidalis, should also be noted. In this specimen practically all secretion from the sinus frontalis would find its way into the sinus maxillaris. (J. P. Schaeffer.)

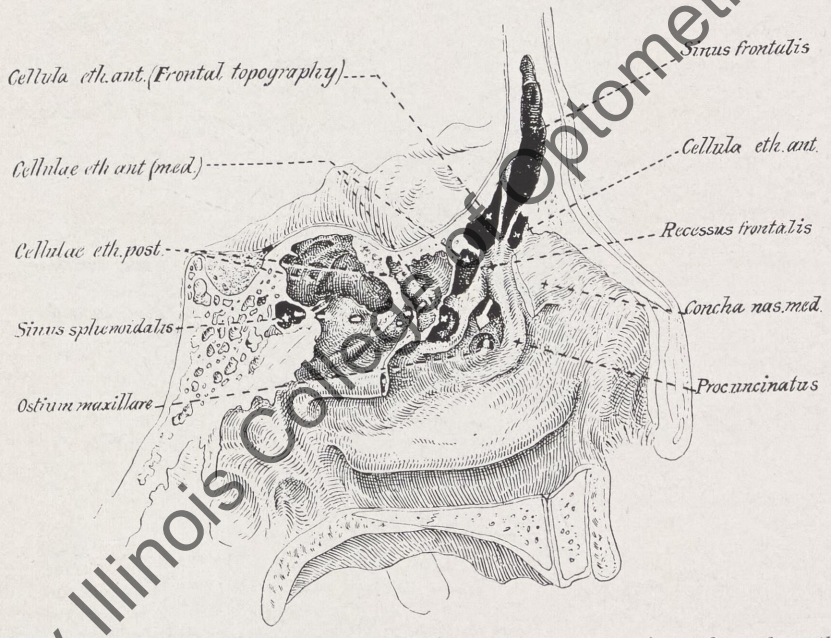

Fig. 26.—Dissection from an adult. Note the two sinus frontales, the absence of ductus nasofrontalis, and the ventral termination of the infundibulum ethmoidale. (J. P. Schaeffer.)

Digitized by Illinois College of Optometry

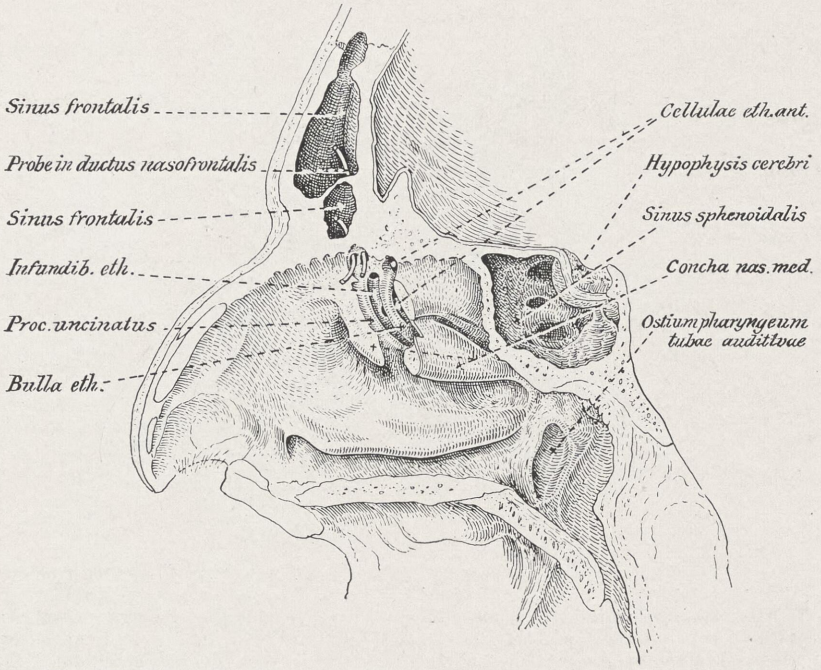

Fig. 27.—Dissection from an adult. Note the sinus frontalis present in duplicate, the proximal ostia frontalis in relation to the recessus frontalis, and the ventral termination of the infundibulum ethmoidale. (J. P. Schaeffer.)

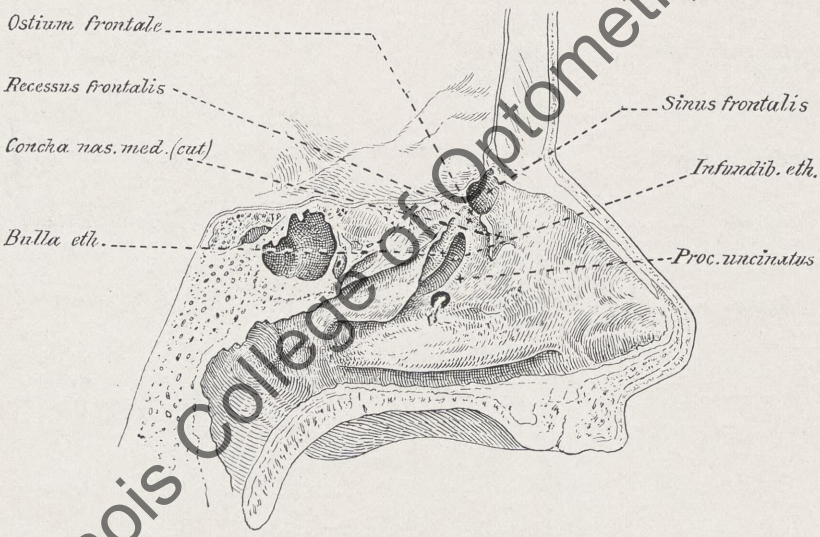

Fig. 28.—Dissection from an adult. Recessus frontalis exposed. Note the diminutive sinus frontalis and the absence of a ductus nasofrontalis. "The views held on the presence and absence of the sinus frontalis are, doubtless, largely due to differences of opinion as to what should be called a sinus frontalis, and how far the development must have progressed into the frontal region before the cell has reached the dignity of a sinus frontalis." (J. P. Schaeffer.)

Digitized by Illinois College of Optometry

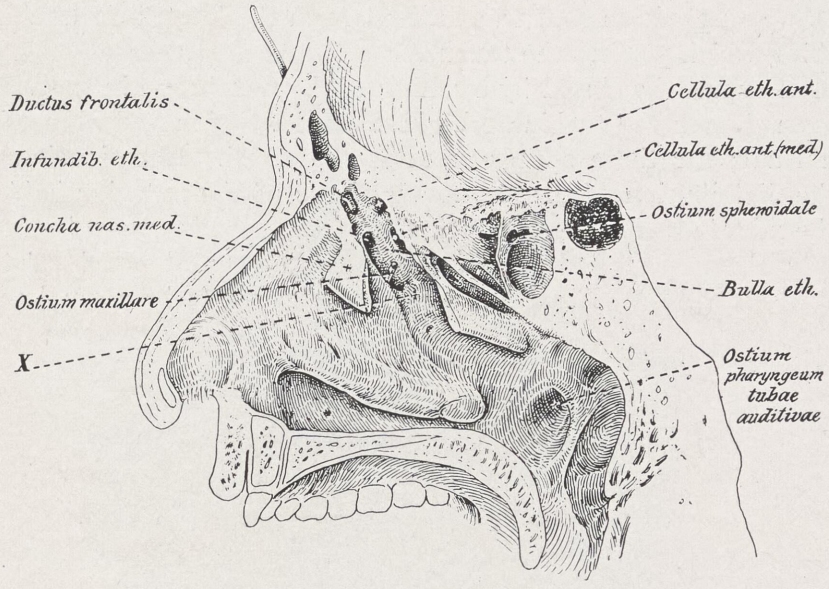

Fig. 29.—Dissection from an adult. Recessus frontalis exposed. Note the discontinuous channels, i. e., the ductus nasofrontalis and the infundibulum ethmoidale. (J. P. Schaeffer.)

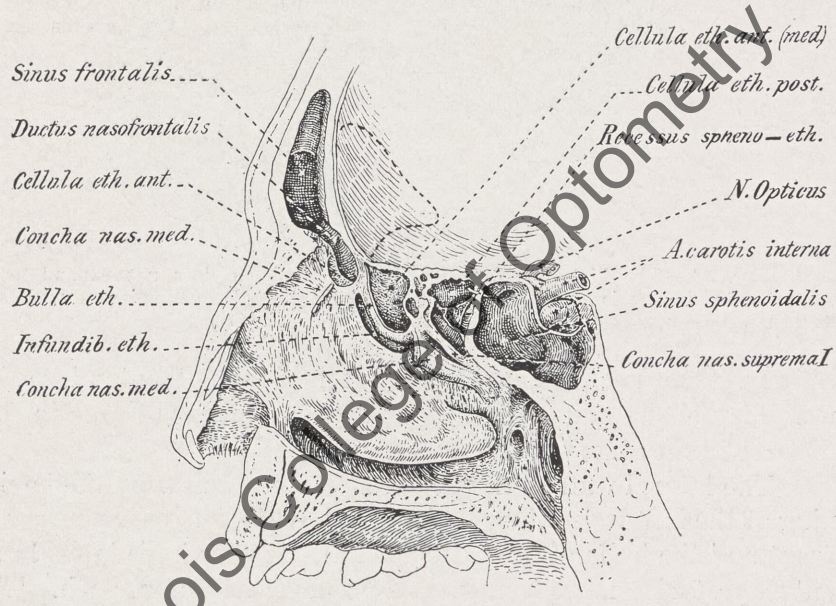

Fig. 30.—From an adult. Note the roomy ductus nasofrontalis, discontinuous with the infundibulum ethmoidale. The intimate relation between the sinus sphenoidalis and the *A.* carotis interna is also indicated in the dissection. The section is to the right of the midsagittal plane, hence the absence of the hypophysis cerebri. (J. P. Schaeffer.)

Digitized by Illinois College of Optometry
Carl F. Shepard Memorial Library
Illinois College of Optometry
3241 S. Michigan Ave.
Chicago, Ill. 60616
11927

occupy a position somewhat raised from the lateral wall. Anything which presses the turbinate outward closes these pouches; or they may be closed by swelling of the membrane in the vault even though the turbinate be in normal position and otherwise normal; for these spaces at most are small. Examination of the distribution of the *cavernous tissue* of the anterior half of the middle turbinate shows that it often extends upward on the lateral surface of the turbinate into the frontal pouch of the vault (Fig. 32). Fig. 33 shows what appears to be normal con-

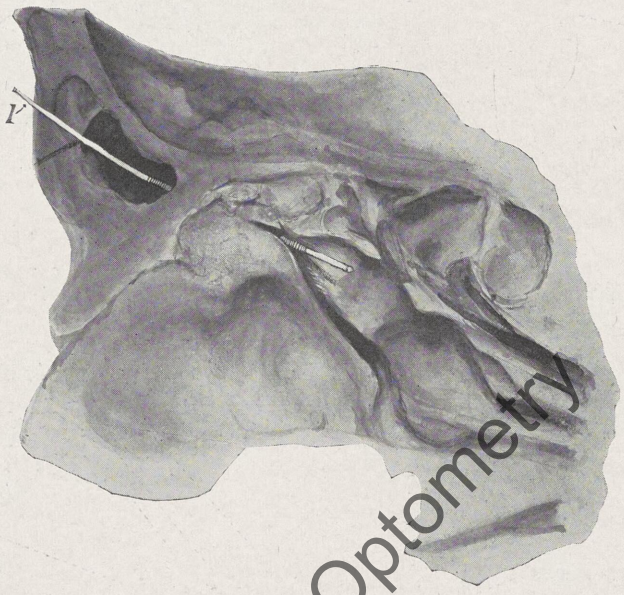

Fig. 31.—The hiatus semilunaris in this specimen does not expand as it passes upward. It is situated unusually far back and communicates with the frontal sinus by a channel more horizontal than usual (*1*.)

ditions. The rule, however, is that it does not extend so far up. Fig. 34 shows a striking absence of cavernous tissue in this district in an otherwise normal nose.

The lateral wall of the pouch is marked below by the beginning of the hiatus semilunaris bounded by the uncinate process in front and the bulla ethmoidalis behind. It may have lateral and anteroposterior measurements of as much as 3 mm. each. The uncinate and bulla may be on the same plane which, however, is not the rule. The bulla is usually well internal to the plane of the uncinate and often fitted accurately into a corresponding

Digitized by Illinois College of Optometry

cup on the lateral aspect of the middle turbinate. (Fig. 35.) The bulla may have come forward to meet the lower part of the uncinate and obliterate the lowest part of the hiatus or it may extend this contact higher up (Fig. 36). Under these conditions the inlet of the frontal sinus is closed in the *middle meatus*

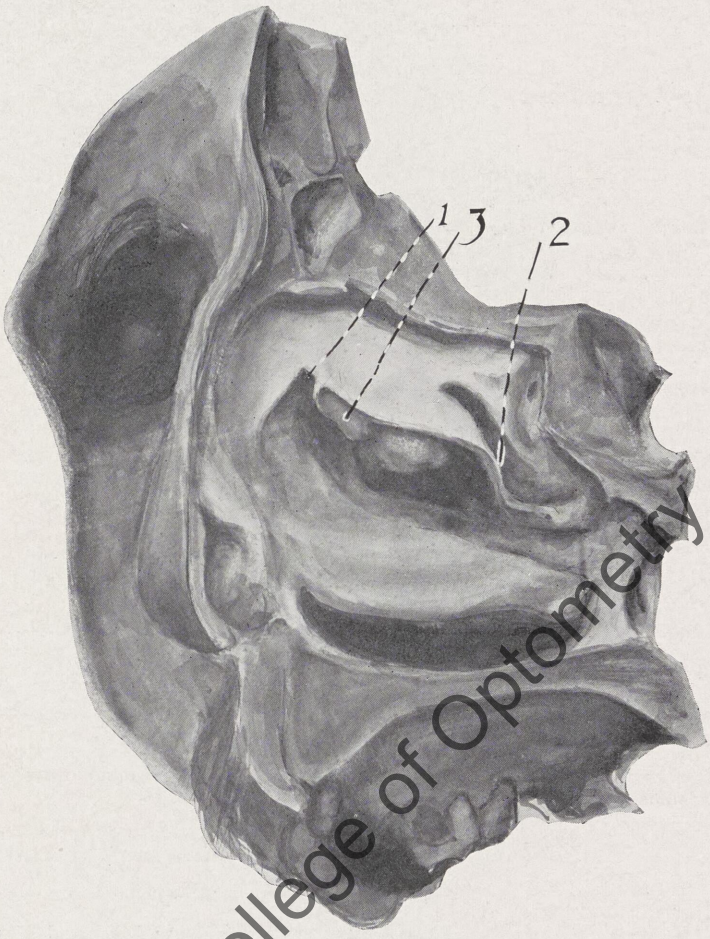

Fig. 32.—Three-quarter view of lateral wall from below upward and outward. Shows *1-2* line of amputation of middle turbinate with the line of origin from the lateral wall. *3*. Cavernous tissue on the internal aspect of frontal pouch.

unless the pouch in its internal limitation is of sufficient amplitude to permit it to extend both above and internal to the bulla. Under such conditions (closure of hiatus) *should the cavernous tissue extend into the pouch it will, upon slight swell-*

Digitized by Illinois College of Optometry

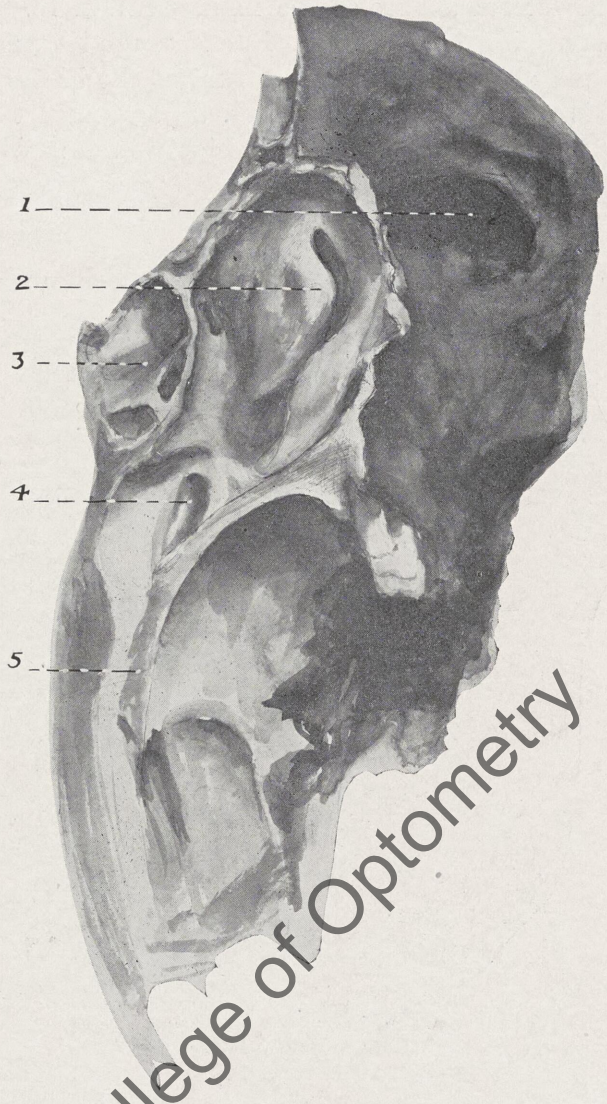

Fig. 33.—Three-quarter of a normal left lateral wall from below upward and outward. *1.* Orbit. *2.* Middle turbinate. *3.* Sphenoid sinus. *4.* Eustachian tube orifice. *5.* Soft palate. Compare Fig. 32.

ing, close to as a cork stops a bottle (see Fig. 32). The main mass of the cavernous tissue of the middle turbinate is developed on its lower half. Frequently, the bulla behind and the lower limit of the uncinate in front occupy a position just above this line and project inward beyond the plane of the lower part

Digitized by Illinois College of Optometry

of the lateral wall of the middle meatus with a shelf-like resemblance under which rests the external half of the mass of the cavernous tissue. These conditions are nearly always found when the markings on the lateral wall are, in general, emphasized (Fig. 36). The nose that shows such markings is apt to have the tubercle of the septum also well marked (Fig. 37), and to be of scant space because of the full development of all the tissues within the (usually) narrow nasal fossa. The great-

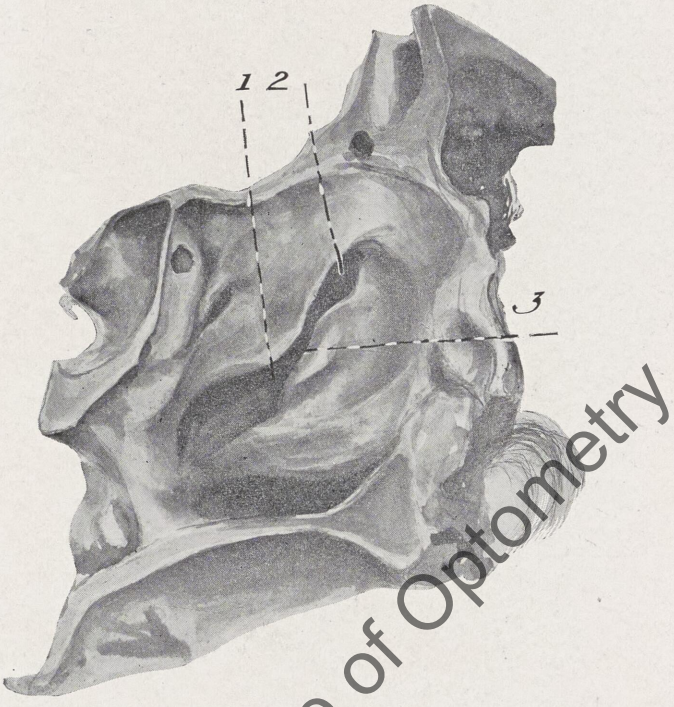

Fig. 34.—Three-quarters view of lateral wall seen from below upward and outward. *1-2.* Free margin of middle turbinate showing total absence of cavernous tissue. This specimen is otherwise apparently normal. *3.* Uncinate process.

est development of cavernous tissue on the middle turbinate is over its anterior third. Just below, in front and internal to this mass of cavernous tissue is developed the tubercle of the septum. In many specimens the relations of the middle turbinate are so intimate (close) that the outline of its anterior third or half is clearly graven not only upon the tubercle below and in front (Fig. 38) but equally upon the lateral wall (Fig. 36). The depression on the lateral wall combined with that on

Digitized by Illinois College of Optometry

the tubercle then forms more or less completely a rigid case in which the turbinate is enclosed. In normal noses these markings are poorly defined or absent and the turbinate has room to hang free in its confines—that is, there is room between it and the septum and between it and the lateral wall (Fig. 39). These spaces may be slightly narrowed. Then there will be

Fig. 35.

Fig. 36.

Fig. 35.—Lateral view showing middle turbinate detached in its anterior two-thirds and turned up. *1.* Bulla ethmoidalis. *2.* Cup on lateral surface of turbinate into which bulla was accurately fitted as shown in three-quarter view in Fig. 15.

Fig. 36.—Three-quarter view from below upward and outward. This anterior middle meatus was closed. Showing bulla ethmoidalis *1* in contact with processus uncinatus. *2.* This contact extends far above line of attachment of middle turbinate to lateral wall *3*. *4.* Cup on lateral wall into which middle turbinate was fitted.

Digitized by Illinois College of Optometry

only moderate marking of the turbinate on both walls. Should these spaces be wide, that is, wide enough to allow normal excursions of the cavernous tissue without its being clamped, neither the lateral wall nor the septum will be marked (Fig. 39). In some narrow noses the imprint of the turbinate on both walls is perfect throughout its length (Figs. 36 and 38).

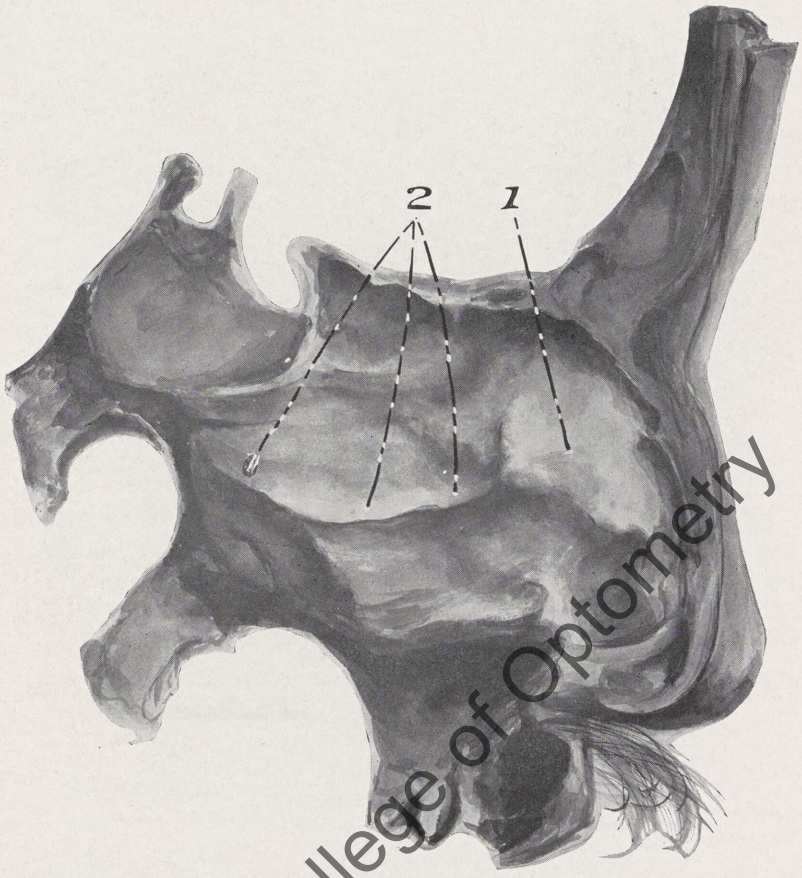

Fig. 37.—Septum of specimen shown in Fig. 36. Showing well-marked tubercle *1* and deeply marked imprint of entire middle turbinate *2*. This septum was not deflected to either side.

A tilting of the septum to one side, even though slight, is very apt by the help of the tubercle to close the lower slit opening of these case-like confines. A clamping of the turbinate below by a septal spur (Figs. 40, 42 and 43) or ridge is equally or even more efficacious. Swelling of the cavernous tissue then

Digitized by Illinois College of Optometry

can take only an upward direction into the olfactory fissure and the vault of the middle meatus.

In that way the lowest part or beginning of the frontal inlet may be closed. The uncinate and the bulla with the hiatus between them are present on the lateral wall at this (lower) level and extend thence upward and forward. Normally the

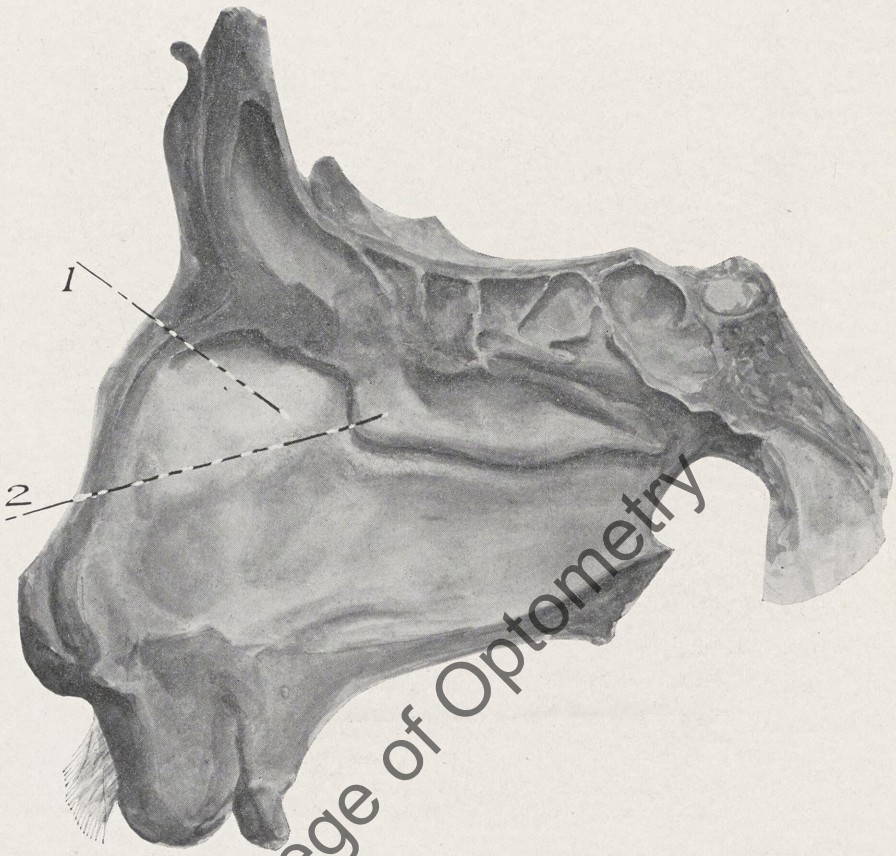

Fig. 38.—Sagittal section through the capsule of the ethmoid left side showing relations of middle turbinate (attached) to the tubercle of the septum *1. 2.* Middle turbinate sharply graven into the septum in its entire length. The tubercle of this septum is very well marked but not deflected.

hiatus should remain open from below upward into the infundibulum. The bulla, however, is often developed from behind and below in a forward and upward, or upward and forward direction to meet the uncinate process, and for a longer or shorter distance, obliterates the hiatus (Fig. 36). This is usu-

Digitized by Illinois College of Optometry

ally on the line of origin of the pendulous or free middle turbinate from the lateral wall, which line may be accurately located at the anterior limit of the origin of the turbinate. The frontal pouch is not necessarily closed, however, by the obliteration of the hiatus, as it should still have an opening internal to the plane of this closure and may have its uppermost dimen-

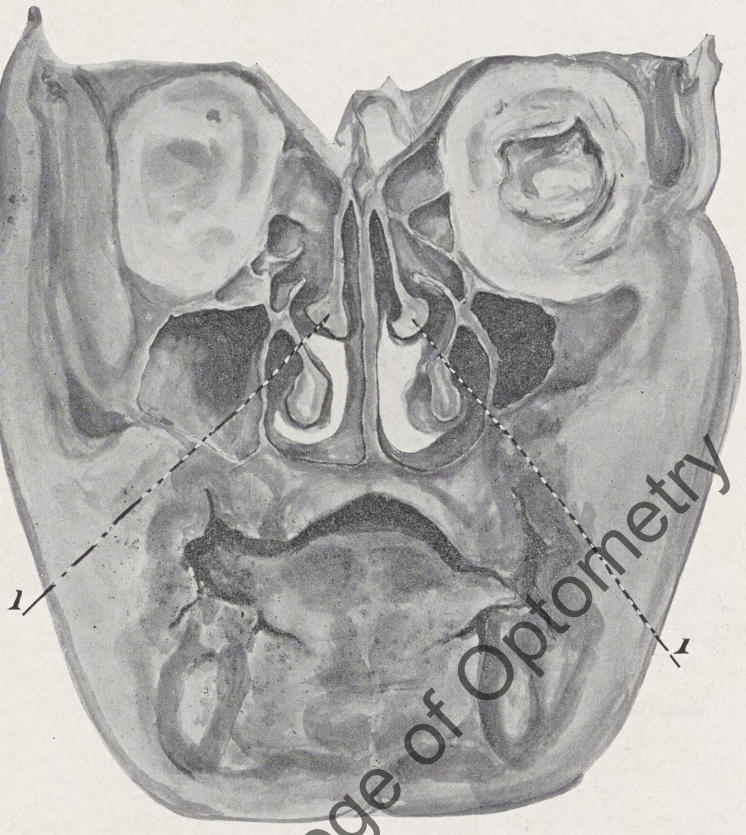

Fig. 39.—Showing middle turbinate displaced with free space between septum and lateral wall.

sions undisturbed by it. But should the bulla develop further in the directions of upward and forward, it will be found to develop *also inward* and *backward* to fit tight under the turbinate, and so close the *frontal* and *ethmoidal* pouches from *all directions* and *completely* (Figs. 35 and 36). This may often be discovered by the use of Killian's long blade speculum. For three years, however, I have had in use a speculum which, in

Digitized by Illinois College of Optometry

my hands, serves this use better, Fig. 41. It is bivalve, usually known as the Vienna Model, the blades of which are lengthened unequally, the internal blade is longer and designed primarily to be applied to the septum, and dislocate deflections to the opposite side while operating in the upper half of the nose. The external blade is shorter, like that of Hurd's speculum, and rests on the frontal process of the maxilla, which is then used as a resistance point from which the septum may be pushed to the opposite side. It differs, however, from Dr. Hurd's specu-

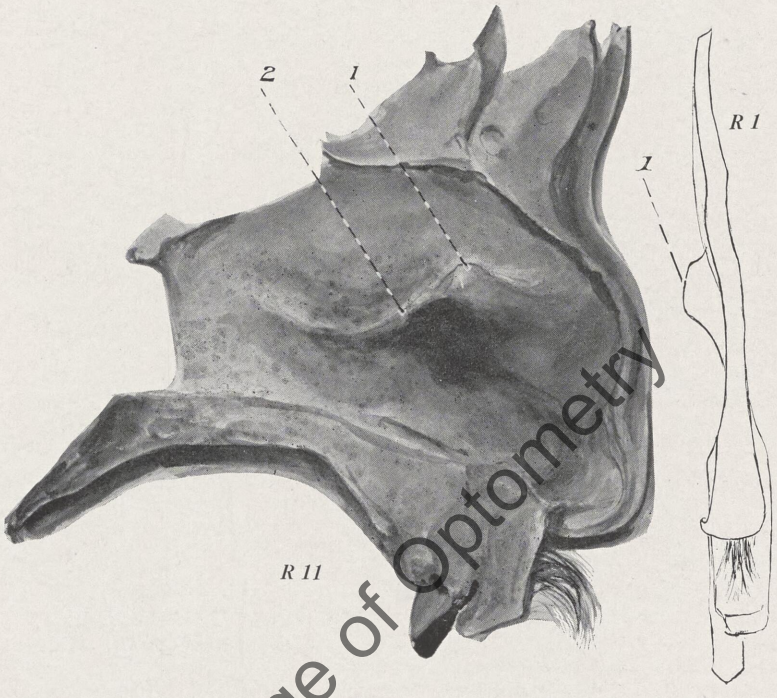

Fig. 40.—Showing tubercle of the septum (*1*, *2*) well marked almost like a spur at its upper limit. *R 1* shows a mechanical drawing of same seen from in *R 11* front.

lum in that the end of the short blade is curved slightly outward. This is designed to make it self-retaining and it serves this purpose well. It also has the additional advantage of being short, and thereby not in the way when operating on the lateral wall. This speculum is also helpful for raising the middle turbinate from the lateral wall (Killian's rhinoscopia media). The instrument is of tempered steel and strong enough to dislocate tur-

Digitized by Illinois College of Optometry

binate and septum to the opposite side. (Dr. Hurd designed his speculum as an aid in submucous resection of the septum.)

Above the limit of the frontal pouch is the infundibulum, which is usually more capacious and is not so readily closed in the manner just described. The opening of the infundibulum into the frontal sinus, however, may be small and tortuous as pictured (Fig. 18).

Pathology and Method of Closure.—The method of closure (or accidents of the anatomy) in these vacuum nasal headaches may be divided into six classes. The histological changes re-

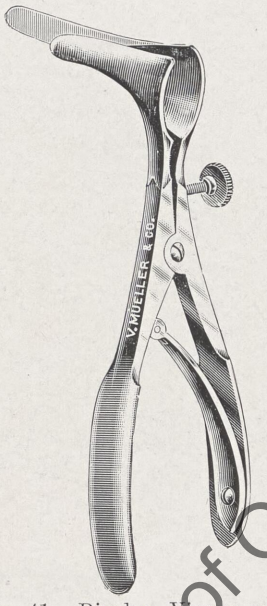

Fig. 41.—Bivalve, Vienna model.

corded in these classifications are the observations of Dr. Jonathan Wright from 207 specimens.

Class I.—From the above correlation of the parts of the middle meatus it may readily be seen that enlargement of the septum tubercle or the tilting of it out of the middle line in a normal or *particularly in a narrow nose* will so narrow the confines of the middle turbinate as to cause the cavernous swelling to take the direction of the vault and its pouches, and in this way close the inlet of the frontal sinus at its beginning. In a study of 451 vacuum frontal cases (Sluder[48]), 38 per cent

Digitized by Illinois College of Optometry

proved to have been established in this way, i. e., to have this mechanism as the etiological factor. The turbinate is histologically normal. The etiology of the deflected septum then comes into causal relation (see Mosher[2] and Lack).

Class II.—Noses with clinical appearances normal. By this I mean that the middle turbinate is not hypertrophied, the tubercle of the septum is normal, and the vault of the

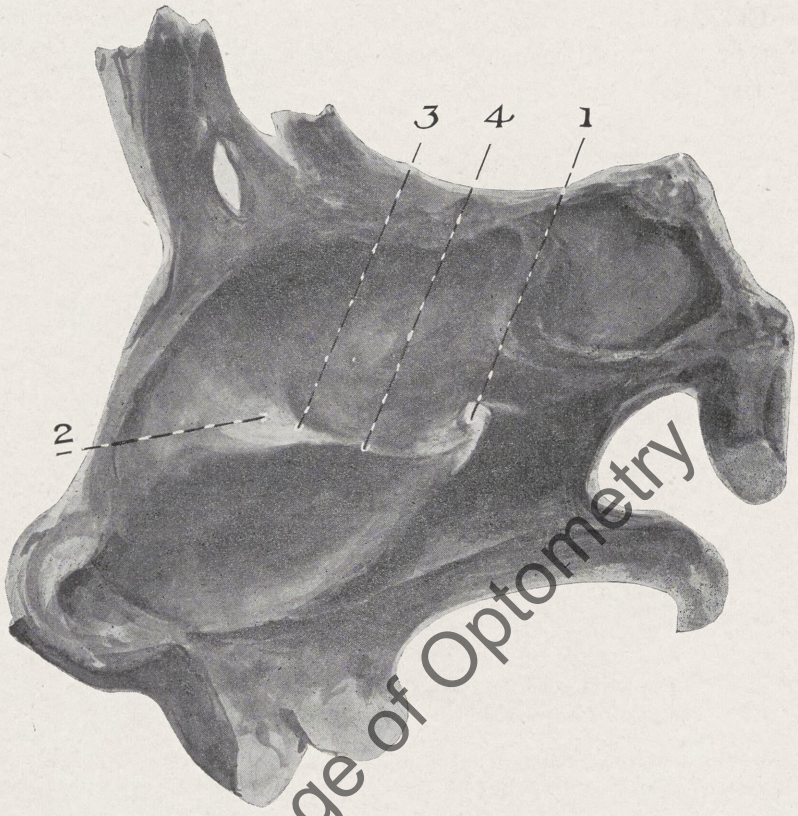

Fig. 42.—Showing posterior spur *1* and well-marked ridge *3-4* with large tubercle. *2*. This septum would clamp the middle turbinate in front, below and behind.

middle meatus is open. In this class of cases there is no history of empyema or of coryza as starting the trouble. These were the most mysterious until they were operated upon; that is, the middle turbinate removed. Then it was found that the hiatus semilunaris was narrowed or occluded by bony narrowing, the uncinate process and bulla being in contact. It was

Digitized by Illinois College of Optometry

this class of cases that I emphasized in the title of my paper in 1900 (Sluder and Ewing[2]). At that time I thought them to be more frequent than subsequent experience has proved. (The tubercle class I find is larger.) Twenty-four per cent of the cases were of this origin. The turbinates showed thickened periosteum with great bone activity, active osteoblasts and few osteoclasts with large bone areas.

Class III.—Edema of the vault of middle meatus. The vault of the middle meatus may be closed by swelling of its soft tissues (edema) without especial hypertrophy of the soft

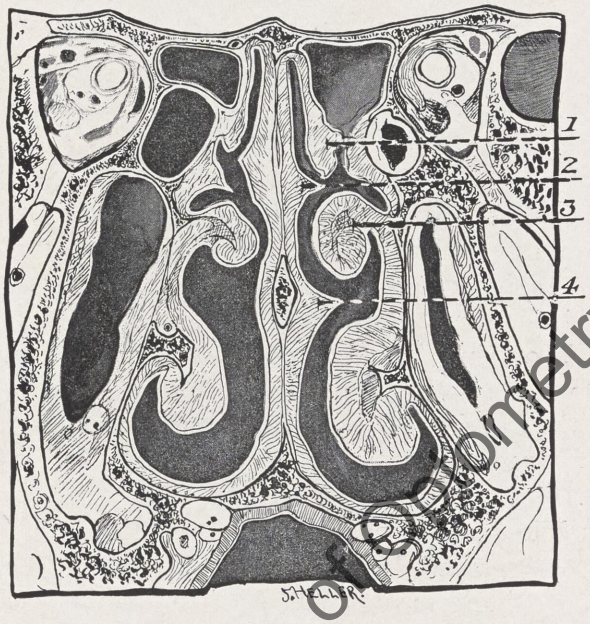

Fig. 43.—Cross section in posterior part of nose showing spurs *2-4* above and below middle turbinate *3*. *1*. Upper turbinate.

tissues of the middle turbinate proper, that is, of the cavernous portion of the middle turbinate. Under the influence of an acute coryza these noses often develop polyps. As the coryza subsides the polyps subside, but the edema remains. Fifteen per cent of the cases were of this origin. The turbinates showed some connective tissue in the stroma of the mucosa without any great activity in the bone, nor was the amount of bone increased. Some new bone formation showed at some places.

In these patients, in whom the middle turbinate has been

Digitized by Illinois College of Optometry

removed, I have many times seen, during a coryza, the hiatus semilunaris fill out with an edema and develop broad-base polyps in the hiatus and over the bulla, accompanied (without pus) by all the symptoms and signs of the original disturbance. These would subside in a little longer time than is required for a coryza in a normal nose and would not appear again until the next coryza. As time goes on, however, the condition gets more marked until the polyps are permanent. Application of radium usually controls the formation of polypi (Sluder,[47] Lyons[2]) and edema (see below).

Class IV.—Middle turbinate hypertrophy. The vault of the middle meatus may be closed by hypertrophy of the middle turbinate, uncomplicated by suppuration or polyps. Eleven per cent of the cases were of this origin. Turbinates from this class showed the same changes as Classes II, III and VI, but more marked.

Class V.—Anatomical insufficiency of vault. The vault of the middle meatus may be obliterated by the middle turbinate being simply lapped down against the external wall, in a nose that is otherwise normal. Seven per cent of the cases were of this origin. This seems an anatomical peculiarity, although the more I observe the nose, the more it seems to me that it is the result of a correlated influence in the past that has left no trace in its wake. Turbinates of this class were normal.

Class VI.—Empyemas or coryzas without suppuration which have recovered, but have left a degree of swelling in the vault of the middle meatus sufficient to keep the frontal sinus closed and so keep up enough pain to render the eyes unfit for ordinary work. Three per cent of the cases were of this origin. (These cases might be said to belong to Class III. They are, however, in a different stage of development.) (Cases 1-6.)

In addition to these chronic cases, one occasionally sees others that are excited by an acute coryza (without sinus suppuration) by reason of the swelling of the membrane in general, and subside spontaneously with the coryza. I have construed these cases as having a small inlet to the frontal sinus. Swelling of the membrane in the vault from the coryza is sufficient to close the inlet, but as soon as the coryza subsides,

Digitized by Illinois College of Optometry

the swelling also subsides, the sinus opens, and the symptoms subside.

Lately I have seen cases of typical vacuum frontal headache that showed clouding of the sinus in the x-ray picture. Subsequent pictures, after the patient had been operated upon and all symptoms relieved, did not, however, show any changes in the clouding. These patients never showed pus in the nose and got well by removing the middle turbinate. With the improvement of the technique of the roentgenologist that has steadily gone forward, it is quite possible that a definite percentage of the vacuum frontal cases may be found to show this clouding, which was not recognized in the past. I know of no explanation for clouding in the cases that I have observed; probably it is from normal but uneven thickness of the bony walls.

Rhinologists at the present time usually demand the presence of pus coming from the paranasal cells as essential for the clinical diagnosis of the painful diseases of these cells, and many superlative treatises upon these forms of their diseases have appeared in the recent past at the hands of the modern masters. Clinical recognition of changes in the ethmoid bone consequent to or upon inflammation of the mucous membrane was begun with the observations of Edw. Woakes in 1885 and have finally been concluded in the chapter of Hyperplastic Ethmoiditis by E. Zuckerkandl,[1] L. Gruenwald, M. Hajek,[3] H. Cordes, W. Uffenorde,[2] and Cholewa. These observations relate to the anterior ethmoid only. Doctor Wright's observations summarized in the introduction form an additional and conclusive chapter on this subject.

Woakes was a shrewd enough observer clinically to recognize that polyps were secondary to other changes in the nose. This was a great advance. His method of investigation, however, was unfortunate, seemingly. He used and recommended a small pointed probe, a "canniliculus probe," stating that the bulb-tipped probes did not answer the purpose. (It would seem that for the purpose of palpation the bulbous-tipped probe would give much more trustworthy results.) And he adhered to an unfortunate name, "necrosing ethmoiditis," even after Dr. Sidney Martin, who made the microscopical pathological examinations for him, had disclaimed that "necrosis" could be

Digitized by Illinois College of Optometry

recognized. A perusal of his (Woakes) text, in the light of the present, gives the impression that he observed several classes of cases with the common factor, rarefying osteitis (which may have given the impression of necrosis on palpation). Undoubtedly he observed hyperplastic ethmoiditis without pus and with pus. Hajek[3] gave the first full account of the microscopical changes in the process underlying polyp formations and proved them to be "hyperplastic ethmoiditis." Cordes and Uffenorde[2]

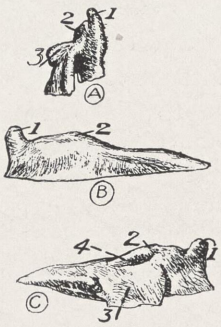

Fig. 44.—Wood's metal casts of a narrow middle meatus. *1.* Projection leading into a narrow, small frontal pouch, representing a small infundibulum. *2.* Small projection representing a small ethmoidal pouch. *3.* Mass of metal which had flown into maxillary sinus (through a large opening.) *4.* A small groove made by a poorly marked uncinate process. In this specimen the middle turbinate laid close to the lateral wall. *A* shows front view of cast; *B* shows internal surface; *C* shows external surface.

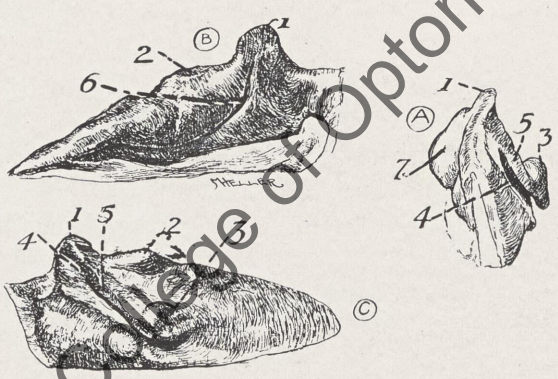

Fig. 45.—Wood's metal casts of a wide middle meatus. *1.* Projection representing frontal pouch. *2.* Small projection representing ethmoidal pouch. *3.* Projection marking the entrance into maxillary sinus. *4.* Groove made by uncinate process. *5.* Ridge made by hiatus semilunaris. *6.* Groove made by ridge on external surface of turbinate. *7.* Excess of metal. *A,* front view; *B,* internal surface; *C,* external surface.

Observe that although this meatus was wide in its lower part, the entire vault was quite narrow. The frontal and ethmoidal pouches are rapidly obliterated from below upward.

Digitized by Illinois College of Optometry

corroborated his findings, the latter giving a detailed description in his monograph of the clinical as well as the pathological aspects of the problems. Cholewa contested Hajek's findings. At the time of the controversy over Woakes' statements a most interesting discussion on the "Etiology of Mucous Polypi of the Nose" was held in the Section of Laryngology and Rhinology of the British Medical Assn., 1895. (British Med. Jour.,

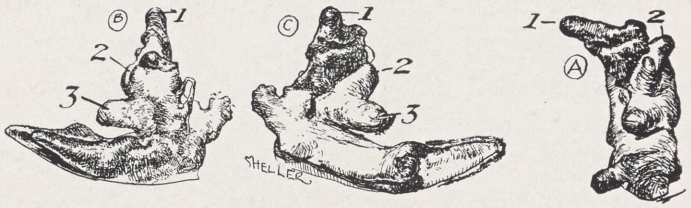

Fig. 46.—Wood's metal cast of a wide middle meatus with wide frontal and ethmoidal pouches readily permitting the flow of metal into frontal and ethmoidal sinuses. *A*, front view; *B*, internal view; *C*, external view. *1*. Frontal pouch. *2*. Ethmoidal pouch. *3*. Cast of opening into maxillary sinus.

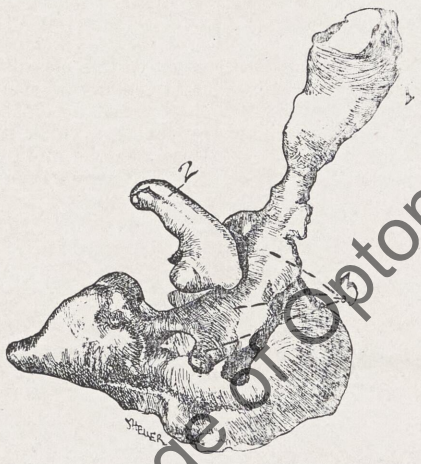

Fig. 47.—Wood's metal cast of very wide middle meatus with very wide frontal and ethmoidal pouches readily permitting flow of metal into frontal ethmoidal cells. *1*. Cast of part of very large frontal sinus. *2*. Cast of an ethmoidal cell. *3*. Very large hiatus semilunaris and infundibulum.

Aug. 24, 1895.) Many of the most prominent rhinologists of the day took part in it; to wit, Guye, Luc, Zuckerkandl, McBride, Hodgkinson, Spicer, Hill, Bosworth, Schmidt, Daly, Mackenzie, Newman, Lake, Williams and de Roaldes. Many ideas were expressed more or less approaching the present day views. Conspicuous are those of Zuckerkandl and P. Watson-Williams.

Digitized by Illinois College of Optometry

The former stated that instead of a necrosing process at the base of the polyp he found an hypertrophic process in the bone as well as in the soft parts, but no necrosis. Dr. Watson-Williams stated that he has observed "*formative* and *rarefying* osteitis in the base of polyps." These are Hajek's findings which are given in full detail. Hajek stated that Martin's findings in their essentials corresponded with his.

The anatomy of the nose was first described in detail by Zuckerkandl, otherwise anatomists have given only descriptions of the more self-evident. Since the time of Zuckerkandl rhinologists have added much detailed observation.

The methods of closure of the frontal sinus from the above description may appear to be accidents of the anatomy, and such was my idea for a number of years. Continued observation of these cases, however, has led me to believe that anatomical accidents may be unfavorable to the communication of the sinus with the nose and that these are more marked in a narrow nose than a wide one, as shown by the casts of such noses (Figs. 44 and 47); but that the real, underlying trouble is usually not a pure anatomical accident. It is usually a thickening process in the membrane and bone summed up under the caption "hyperplastic process" and further designated by the locality in which it is found. The present descriptions of this lesion limit it to the anterior ethmoid "hyperplastic ethmoiditis," but according to my observation it may begin and remain in other parts also, with more or less pernicious effects, according to the parts involved.

Geo. E. Shambaugh in a recent paper says that vacuum headaches have been attributed to closure of the frontal sinus. If this be the case they should appear in advanced hyperplastic ethmoiditis with development of polypi completely closing the middle meatus, but he had not found headache a frequent symptom of that condition. I have seen such cases with and without headache. It seems to me that the occurrence of vacuum frontal headache in such cases depends upon the location of the process. That it involves the capsule of the ethmoid is not ground for the assumption that it includes the hiatus semilunaris also, and even if it did it still might not be closed by the

Digitized by Illinois College of Optometry

process. The facts for the individual case are necessary for conclusions.

L. R. Effler recently published his experience with vacuum frontal headaches. He reports that in a group of 125 frontal sinus cases of all kinds he found 35 cases of the "vacuum frontal" type. His percentage would probably vary were the observations made on a thousand or more cases. It is interesting to note that in these 35 cases, no less than 25 were found with high septal deviations on the side of the trouble (71 per cent).

DIFFERENTIAL DIAGNOSIS

The supraorbital nerve emerges from the orbit at the junction of the inner and the middle thirds of the supraorbital ridge. At this point it passes through the supraorbital notch, and is distinctly accessible for finger pressure. Under normal conditions the site of this nerve is the most sensitive part of this area. The pressure tolerated by it normally is little. In neuralgia of the supraorbital nerve it becomes very much less. The pressure tolerated by that portion of the orbit which lies internal and posterior to the supraorbital notch, which is formed by the thinnest wall of the frontal sinus, is normally much greater than the nerve will tolerate. When the *nerve* is *normal* and the *frontal sinus closed,* the *orbit anteriorly* and *posteriorly* to *the supraorbital notch* becomes as *sensitive* or *more sensitive* than the nerve itself. The supratrochlear as well as the supraorbital nerves are external to Ewing's tender spot. The supraorbital is more accessible for tests. Anterior ethmoidal (nasociliary) neuralgia (see page 68) produces pain in the region of the nasal bones, which may extend slightly upward or downward and may give the impression of frontal sinus pain. Ewing's sign and supraorbital nerve tenderness, however, will be absent. Intranasal cocainization of the anterior ethmoidal nerve stops the pain of anterior ethmoidal neuralgia but does not stop the pain of frontal sinus vacuum neuralgia or that of supraorbital neuralgia. (In the use of the last term I have in mind a pain usually of toxic digestive origin. It must not be confused with major neuralgia of the ophthalmic nerve—tic douloureux.) The pain of nasal ganglion neuralgia also may

Digitized by Illinois College of Optometry

extend into this district, but Ewing's sign will be absent. The supraorbital nerve will not show tenderness, nor will it be relieved by anterior ethmoidal cocainization.

In the differential diagnosis of all headaches the rhinologist should be on guard for intracranial lesions, and should have the cooperation of the neurologist. Despite the acumen of both of these specialists, confusion and error may arise.

The rhinologist should be equally on guard for the pain of the various eye lesions and should have the cooperation of the ophthalmologist.

Headaches from all Causes and Their Separation from That Produced by Closure of the Frontal Sinus Without Suppuration

Closure of the frontal sinus gives Ewing's sign (see above). This is not found in headaches produced by ethmodial or sphenoidal sinuses, ocular, digestive, gynecologic, renal, gouty, neurotic, or any other cause except empyema of the frontal sinus.

PROGNOSIS

The prognosis for the individual case is difficult. The simplest treatment is sometimes rewarded by a strikingly satisfactory result. On the other hand, cases that would apparently furnish a satisfactory result are sometimes found to be most stubborn. For these cases everything fails save the removal of the middle turbinate. This alone frees the inlet to the frontal sinus.

The prognosis for the operated case will be found to vary according to the microscopical changes in the turbinate which has been removed. If it shows marked periosteal thickening and bone activity, it will be found that in two, three or five years the inlet will have so far narrowed, by the encroachment of the bulla upon the uncinate process of the ethmoid, that the patient will again have pain and a tender Ewing's point during and for a time following a coryza; and it may later come to pass that Ewing's point remains tender until the inlet has again been enlarged.

Digitized by Illinois College of Optometry

On the other hand, cases that show no bone or periosteal activity remain apparently permanently cured. These patients usually show age by change in the skin rather than change of features. Their skin will look old, but their features in fifteen years' time show almost no change.

TREATMENT

It suggests itself, in logical sequence, that anything that will diminish swelling of the soft tissues, which closes the inlet to the sinus, will be of service, and to this end I have employed the various astringents in commonplace usage, with satisfactory results for a very great number of cases, the applications being made in and about the middle meatus. My method of procedure is to try these applications in all cases. After a trial of two weeks, if there has not been any response to treatment, more radical measures may be resorted to.

It is sometimes astonishing to note what may be accomplished by the simple application of astringents. In this connection I should like to narrate the history of a patient. She had suffered for five years from headaches and eye disturbances. She came under my observation in 1902. Her case belonged in Class III. Following the routine, I made an application of 2 per cent silver nitrate to those parts, about twelve times, extending over a period of three weeks, when the headache stopped, and has not returned. I state this positively, because my association with the patient socially gives me full opportunity to know.

It is well known that the obstruction to the outflow of pus from the frontal sinus is usually the middle turbinate; and so it is likewise the middle turbinate that is usually the obstruction to the ingress of air to the frontal sinus.

The more radical treatment is then the opening of the inlet of the frontal sinus, which is usually accomplished by the removal of the middle turbinate. My method is to free the inlet to the anterior ethmoidal labyrinth, at the same time removing the anterior two-thirds or three-fourths of the middle turbinate. It is my especial effort to put the incision as high upon the capsule of the ethmoid (the external wall) as possible, about 2 mm. from the cribriform plate. In my experience this

Digitized by Illinois College of Optometry

has been accomplished most readily by the method I described in the *Journal of the American Medical Association,* June 29, 1907, and again in more detail and elaboration, before the American Laryngological Association, 1916. I prefer to give this technique in detail in connection with the ethmoidal sphenoidal technique in Chapter VI, page 139. By this method the turbinate may be cut out up into the infundibulum. This seems to me also to be necessary, as it is at this place that the obstruction very frequently exists. In the great majority of cases this suffices to open the sinus and thereby effects a cure; the headache stops and the eyes go into unlimited service.

Three times I have found the uncinate process and the bulla of the ethmoid in a firm contact, reaching so high up that I was obliged to remove the uncinate process up to the level of the cribriform plate, and once some little above it.

Fifteen times I found the hiatus semilunaris filled out by a fibrous hypertrophy of the membrane covering the bulla; in these cases I succeeded in getting the result by a superficial galvanocautery destruction, the line of which ran parallel to, and just posterior to the uncinate process. The contraction of the scar resulting from this wound tends to pull the tissues out of the hiatus semilunaris. (Cases 1-6.)

VACUUM ETHMOIDAL HEADACHES WITH EYE SYMPTOMS ONLY

Headache may arise from closure of the anterior ethmoidal labyrinth, and is in every way similar in its mode of establishment to the frontal sinus headache just described. This will appear from a perusal of the anatomy just described. It does not, however, occur as often. The few cases that I have recognized have had the external tender point at the site of the lacrimal bone instead of at Ewing's point and the pain was referred to behind or between the eyes. Use of the eyes is not so much a factor in causing the headache in these cases as in the frontal sinus cases. Considering the anatomy in the light of the description just given it is somewhat surprising that they do not arise oftener, especially from the cells which so often open into the infundibulum and hiatus semilunaris.

Digitized by Illinois College of Optometry

The pathology, diagnosis, prognosis, and treatment in these cases are otherwise the same as for the frontal sinus cases.

The outlet of the maxillary antrum in the hiatus semilunaris is so placed as to render it possible of closure under the same influences that close the frontal and anterior ethmoidal cells. I have not, however, seen a case that seemed to me to be such. I have construed this as explicable by virtue of the fact that the walls of the antrum are thick and do not become sensitive under these conditions. Nevertheless, I can conceive of such a case, and, moreover, R. C. Lynch has reported a number of them.

Digitized by Illinois College of Optometry

CHAPTER IV

ANTERIOR ETHMOIDAL (B. N. A.) (NASOCILIARY [QUAIN]) NEURALGIA

From the anatomy of the anterior ethmoidal nerve which enters the upper anterior limit of the nose through the small ethmoidal sulcus of the nasal bone (B. N. A.), I have felt for a number of years that cases of neuralgia (pain) of this nerve would eventually be found. It is superficial in the nose and enters through bone which may be the seat of hyperplastic changes, so it may be the site of inflammation or pressure, either of which can cause pain, but it was not until 1920[23] that I found such cases that permitted description. Better ability to recognize them, however, has proved that they are not so rare as I first thought, although they are probably the least frequent of the nasal headaches (my experience).

The anterior nerve supply of the nose is a small branch which enters the nasal fossa (through the ethmoidal sulcus) at its uppermost anterior limit. The B. N. A. gives this as the "anterior ethmoidal nerve," and further as a "branch of the nasociliary" and states that the old term for the latter is "nasal nerve." Various authoritative anatomists employ various names. At the time I described neuralgia of this nerve I used the term "nasociliary." It now seems best to use the term of the B. N. A., i. e., "anterior ethmoidal."

Anatomic Description (copied from Quain, eleventh edition, part II, vol. iii, p. 16, with changes to conform with the B. N. A.):

"**Nasociliary or Nasal Nerve.**—This nerve enters the orbit between the heads of the external rectus muscle and between the two divisions of the third nerve. It then inclines inwards over the optic nerve, passing beneath the superior rectus and superior oblique muscles, to the inner side of the orbit, and leaves that cavity by the anterior internal orbital canal. In this part of its course it furnishes a slender branch to the ciliary ganglion, one or two filaments (long ciliary) directly to the eyeball, and a

Digitized by Illinois College of Optometry

considerable infratrochlear branch, which arises just before the nerve enters its canal on the inner side of the orbit.

"Arrived in the cranial cavity, the nerve is directed forwards in a groove at the outer edge of the cribriform plate of the ethmoid bone to a small canal between the fore-part of the plate and the frontal bone (ethmoidal sulcus B. N. A.), through which it descends to the nasal fossa. Here it (anterior ethmoidal B. N. A.) gives off internal, or septal, and external branches to the mucous membrane of the fore-part of the nasal fossa, and is then continued downwards in the groove on the back of the nasal bone, to terminate as the anterior or superficial branch in the integument of the lower part of the dorsum of the nose.

"The *branch to the ciliary ganglion*, very slender and from a quarter to half an inch in length, arises generally between the heads of the external rectus. It lies on the outer side of the optic nerve and enters the upper and back part of the ganglion, constituting its *long root*.

"The *long ciliary nerves* are situated on the inner side of the optic nerve; they join one or more of the short ciliary branches from the ciliary ganglion, and after perforating the sclerotic coat of the eye, are distributed in the same manner as those nerves.

"The *infratrochlear nerve* runs forwards along the inner side of the orbit, below the superior oblique muscle, and parallel to the supratrochlear nerve, from which it receives, near the pulley of the oblique muscle, a filament of connection. The nerve is then continued below the pulley to the inner angle of the eye, and ends in filaments which supply the conjunctiva, the caruncle, and the lacrimal sac, as well as the integument of the upper eyelid and root of the nose.

"The *internal* or *septal branch* supplies the pituitary membrane over the fore-part of the septum, extending downwards nearly as far as the opening of the nostril.

"The *external branch*, often represented by two or three filaments, is distributed to the mucous membrane of the fore-part of the outer wall of the nasal fossa, including the anterior ends of the middle and lower turbinate bones.

"The *anterior* or *superficial branch* issues between the nasal bone and the upper lateral cartilage of the nose, and runs down-

Digitized by Illinois College of Optometry

wards under cover of the compressor naris muscle to the tip of the nose, supplying the skin of the lower part of the organ.

"**Varieties.**—The nasociliary (anterior ethmoidal, B. N. A.) nerve occasionally (frequently, Krause) gives filaments to the superior and internal recti muscles. A branch to the levator palpebrae superioris has also been met with (Fäsebeck). In one case filaments of communication passed from a small ganglion connected with nasociliary nerve to the third and sixth nerves (Svitzer). In two instances Testut observed absence of the infratrochlear branch, its place being supplied by the supratrochlear nerve. Offsets from the nasociliary (anterior ethmoidal, B. N. A.) nerve, as it traverses the anterior internal orbital canal, to the frontal sinus and ethmoidal cells are described by Meckel and Langenbeck; and a *sphenoethmoidal* (Luschka) or *posterior ethmoidal* (Krause) branch is said to pass through the posterior internal orbital canal to the mucous membrane of the sphenoidal sinus and posterior ethmoidal cells."

It is to be seen that the anterior ethmoidal nerve, as it enters the nose in its uppermost anterior limit, is quite near the surface of the membrane. It is more superficial than the nasal ganglion (usually). The ganglion may, however, be quite superficial (submucous), according to Krause. So it is easily understandable that an inflammation of the membrane in this part may irritate or inflame the nerve and produce pain. In older cases, with general hyperplasia of membrane and bone, it is also easily understandable that the ethmoidal slit may be encroached upon to narrow its caliber and place the nerve in a more easily vulnerable position.

Clinical Picture.—Patients who suffer from anterior ethmoidal neuralgia complain uniformly of pain in the region of the forehead, right or left, more or less limited between the eyebrows, extending somewhat above the line of the supraciliary ridge and below into the nasal bones, rarely as far as the tip of the nose. Occasionally they refer some pain to the orbit and the nasal fossa. They often complain that the wearing of eye glasses or spectacles is uncomfortable. They do not associate it with the use of the eyes as is usually the case with vacuum

Digitized by Illinois College of Optometry

frontal headache. It is not periodical like the pain of frontal sinus suppuration (sun pain). As a rule it is not very intense, although I saw one patient in whom it was very intense (prostrating). In this case it was more widespread. (Case 8.)

The attack is irregular in its development, probably associated with acute inflammation of the nose (coryza). It may, however, be more or less constant, which suggests pressure in the ethmoidal slit, probably from the hyperplastic lesion of the nose.

Diagnosis.—The diagnosis is established by placing an application of 5 per cent to 90 per cent cocaine upon the nerve at its entrance into the nose. A very small, straight, cotton-tipped applicator is moistened with the cocaine solution and inserted with gentle pressure into the most anterior limit of the nose. It is then passed upward to its upper limit, which is a place of firm resistance. In this way the application arrives automatically at the point of entrance of the anterior ethmoidal nerve. The effect of the cocaine is quickly obtained. It stops the pain of anterior ethmoidal neuralgia but fails for pains of other origins. (Case 7.)

The Differential Diagnosis.—Pain in the eyes, the brow and the root of the nose, is frequent and may be of various origins. Localization of the pain of the several origins by the patient is not precise. Pains from the frontal, ethmoidal or sphenoidal sinus, the nasal ganglion, or from the supraorbital or anterior ethmoidal nerve origin may overlap in their sensations. Pain from the anterior ethmoidal nerve is usually referred to the small district bounded by the supraciliary ridge above, the supraorbital notch laterally, and the nasal bones below.

The detailed differential diagnosis of pain of nasal origin in this region is given under vacuum frontal headache (see page 63).

Treatment.—Cocainization, as mentioned above, not only stops pain at once, but, in mild and recent cases, is apparently curative. More severe, older cases are sometimes relieved for long periods (months) by cocainization at two to five day intervals, possibly repeated five times. Application of astringent antiseptic remedies to the district naturally suggests itself and is helpful. The most stubborn cases require injection of carbolic

Digitized by Illinois College of Optometry

acid (5 per cent) and alcohol (95 per cent). Four times I have injected the anterior ethmoidal nerve for relief of pain, with success.

This nerve was first injected by Otto J. Stein[4] for hay fever. The technique is the same as that described by him. A straight needle, three inches long, of sufficient strength to make it firm so that it does not bend readily when in use, is inserted to reach the upper anterior limit of the nose. The point is then gently pressed. If it is in the right place, it will be found to engage itself two or possibly three millimeters into a bony canal. Should the first trial fail, several attempts should be made to find the canal. When found, two, or possibly three drops of the solution should be instilled. I have had these cases under observation long enough to give a reasonable prognosis. It seems to be as favorable as for other nasal headaches. Hutter also has had satisfactory results in this type of headache by the injection of alcohol into the nerve above described.

Case Report.—A man, aged 50 years, consulted me November 1, 1923. History negative, save for recurrent headache in his brow, of ten years' duration. It varied from slight discomfort to prostrating pain and recurred at irregular intervals of from three to ten days to eight or twelve weeks. Mild attacks were limited to an area bounded by the supraciliary ridge above, the supraorbital notch laterally, and the nasal bones below, with some eye discomfort. In severe attacks, the pain extended beyond these limits. He had been through much medical investigation. No explanation for the attacks was found. He had had a spur removed from his nose without relief. When first examined he was obviously suffering greatly. His nose showed reddening of the membrane, with moderate hyperplasia and no other abnormalities. The attack was left-sided. He stated it was always left-sided. A small, straight, applicator bearing one drop of 20 per cent cocaine solution inserted as described above, greatly relieved the pain. A second similar application produced complete relief. I gave him a hypertonic alkaline saline solution to use as a nose wash, twice a day. Six weeks later he returned with a similar attack of lesser severity. He had been well in the interval. Cocainization, as above mentioned, again relieved him. Two months later he returned in

Digitized by Illinois College of Optometry

great pain. He asked to be allowed to lie down. He stated that he had not been able to work that day. One drop of saturated solution cocaine muriate applied as above directed, relieved a great deal of the pain. A second application produced complete relief. Some discomfort (soreness) remained in the district for six days. Daily application of one per cent mercurochrome 220 with ⅓ per cent carbolized oil, restored the membrane to normal color. I have proposed injection of alcohol into the nerve. He has not yet agreed to this procedure.

I have injected with satisfaction four other stubbornly recurrent anterior ethmoidal neuralgias. None, however, was of the severity of this case. They are usually bilateral. As a rule (my experience) this is the most tractable of the nasal headaches.

It is difficult for me to understand why anterior ethmoidal neuralgia does not appear more often in practice. It is also difficult to understand why the peripheral nerves of the nose in general should not be the site of pain in a severe coryza. Very severe coryza may cause general soreness in the nasal fossae, even of considerable severity. This, however, is readily distinguishable from the pain of paranasal sinus suppurations and the neuralgias described in this text. For the neuralgias it seems that pressure is required (the hyperplastic lesion) or some particular bacterial toxin that has not been identified and is not produced in the common-place coryza.

Digitized by Illinois College of Optometry

CHAPTER V

THE SYNDROME OF NASAL* (SPHENOPALATINE—MECKEL'S) GANGLION NEUROSIS

In 1908 I[40] called attention to a set of neuralgic phenomena that in my opinion were produced by lesions affecting the nasal ganglion. Since then in several articles I have recorded motor, sensory, gustatory,[17, 31, 43] ocular, respiratory and sympathetic[42] (vasomotor and secretory), phenomena attributable to the same causes. I[14, 15, 16, 19, 26, 30, 33, 34] and others have also recorded inexplicable neurological phenomena connected with the nasal ganglion.

It is my desire in this essay to present fully the various manifestations of nasal ganglion neurosis as far as I know them at present, and to call attention to the anatomy of the district in which the ganglion is found. So far as I can determine, the histology of the nasal ganglion in man has been observed only by Müller and Dahl.

ANATOMY†

"**The Sphenopalatine Ganglion.**—The sphenopalatine ganglion (g. sphenopalatinum), also known as Meckel's, the nasal or the sphenomaxillary ganglion, is a small triangular, reddish-gray (in the fresh state) body and is a component of the group of sympathetic ganglia found in the head region of the body. It is located in the sphenopalatine fossa and very close to the sphenopalatine foramen and is suspended from the maxillary division of the trigeminal nerve. The sphenopalatine ganglion is, therefore, more or less intimately related topographically with the lateral wall of the nasal fossa, the sphenoidal sinus and certain of the posterior ethmoidal cells. In its histological make-up

*The term "Nasal Ganglion" is used by authoritative anatomists at the present day, although the "nomina Anatomica" accepted by the Anatomical Society at Basel in 1895 (B. N. A.) included that of Sphenopalatine Ganglion only. I prefer the term "Nasal Ganglion" because it directs the clinician more readily.

†Quoted from J. Parsons Schaeffer, *The Nose, Paranasal Sinuses, Nasolacrimal Passageways, and Olfactory Organ in Man*, Philadelphia, 1920, P. Blakiston's Son and Co.

Digitized by Illinois College of Optometry

it consists of an interlacement of nerve fibers and stellate nerve cell bodies. The nerve fibers, forming the ganglionic branches, participate in supplying the nasal fossa and the related parts.

"In conformity with the other sympathetic ganglia of the head the sphenopalatine or nasal ganglion has three so-called roots which convey nerve fibers to and from the ganglion; e. g., motor (visceral motor), sensory and sympathetic. Strictly speaking, it is a mere convention to designate the roots as motor, sensory and sympathetic respectively since they usually are of a mixed character as regards the physiology of their component nerve fibers. However, one or other type of fibers usually predominates in the several roots, a fact that probably justifies the naming of the roots as has been done.

"The motor root of the sphenopalatine ganglion in its major part consists of *visceral* (sympathetic) *motor fibers* (preganglionic) of the pars intermedia of the facial nerve (n. intermedius, n. glossopalatinus). These fibers arise in the medulla oblongata from a group of cells in the recticular formation dorsal and medial to the facial nucleus, pass through the geniculate ganglion and become component fibers of the great superficial petrosal nerve (n. petrosus superficialis major) and the nerve of the pterygoid canal (n. canalis pterygoidei Vidii, Vidian nerve) and reach their termination in the sphenopalatine ganglion by arborizing or synapsing there with the cell bodies of post-ganglionic neurons (see neurons numbered *6* in the diagram, Fig. 48). A few of the visceral motor fibers (preganglionic) arising within the medulla oblongata terminate within the geniculate ganglion by synapsing with the cell bodies of post-ganglionic neurons. The peripheral processes of some of the latter neurons follow the great superficial petrosal nerve and the nerve of the pterygoid canal of Vidian, pass through the sphenopalatine ganglion without interruption to be distributed via the ganglionic branches (see neuron numbered *7* in the diagram, Fig. 48).

"It is also established that a number of *somatic sensory neurons* with cell bodies located in the geniculate ganglion are associated with or rather are a part of the so-called motor root of the sphenopalatine ganglion. The peripheral processes of these somatic sensory neurons follow the great superficial petrosal and the Vidian nerves, pass through the sphenopalatine

Digitized by Illinois College of Optometry

ganglion uninterrupted and descend in the small palatine nerve to the soft palate and adjacent parts of the pharynx where some are seemingly concerned with the gustatory function and others with general sensation. The central processes of these somatic sensory neurons terminate about cells at the upper pole of the nucleus of the alar cinerea in the medulla (see neuron numbered *13* in the diagram, Fig. 48). Moreover, there is supporting evidence that there are *sympathetic afferent neurons* associated with the motor root of the sphenopalatine ganglion. The cell bodies of these neurons are located in the geniculate ganglion, the peripheral processes of which follow the same course as the somatic sensory neurons, above referred to, save that the sympathetic afferents enjoy a wider distribution, including among other parts the nasal cavity. The central connections of the sympathetic afferents are not definitely established (see neurons numbered *9* in the diagram, Fig. 48).

"The *great superficial petrosal nerve* is usually spoken of as the motor root of the sphenopalatine ganglion. It is, however, obvious from the foregoing that the nerve is not merely motor in its composition, but that in addition to the motor and most numerous fibers, it contains sensory (somatic and sympathetic) fibers. The great superficial petrosal arises from the geniculate ganglion of the pars intermedia of the facial nerve in the facial canal (canalis facialis), passes through the hiatus of the facial canal (hiatus canalis facialis, hiatus Fallopii) and a groove in the petrous portion of the temporal bone in the middle cerebral fossa. It now courses under the semilunar (Gasserian) ganglion to the position of the middle lacerated foramen (foramen lacerum) where it is joined by the *great deep petrosal* (n. petrosus profundus major) or the so-called sympathetic root of the sphenopalatine ganglion. The great superficial and the great deep petrosal nerves merge over the cephalic surface of the cartilage of the middle lacerated foramen in the formation of the *nerve of the pterygoid canal of Vidian.* The latter with the accompanying blood vessels traverses the pterygoid canal in the root of the pterygoid process of the sphenoid bone, enters the sphenopalatine (sphenomaxillary) fossa, there to connect with the sphenopalatine ganglion located on the lateral side of the sphenopalatine foramen.

Digitized by Illinois College of Optometry

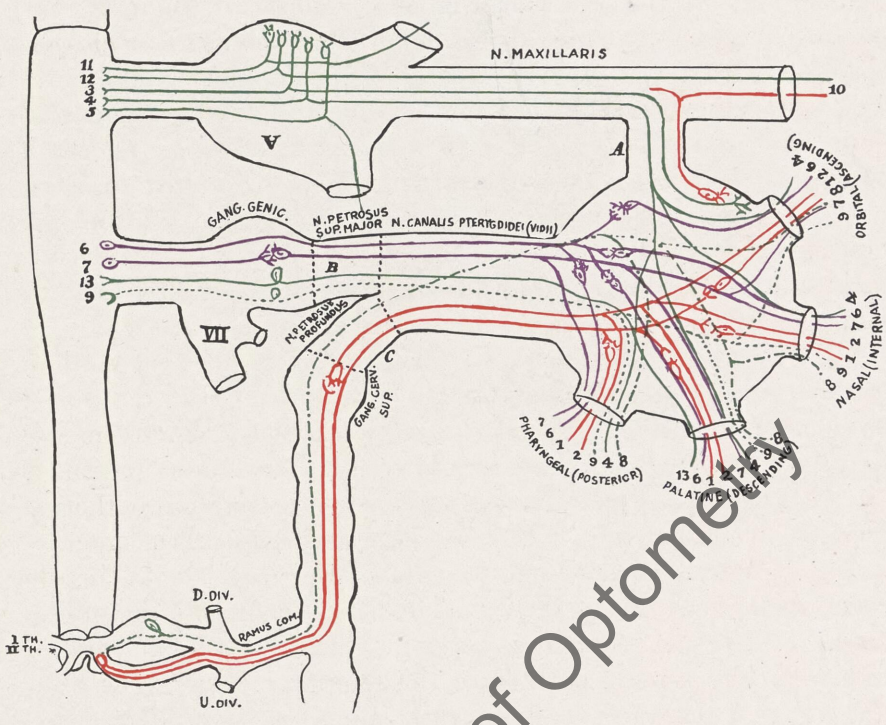

Fig. 48.—Schema showing the connection of the sphenopalatine (Meckel's, nasal) ganglion.

A, Sensory root; *B*, motor root; *C*, Sympathetic root. See text, pages 75-78, for a consideration of the components fibers of the so-called roots of the ganglion. The reference numbers are explained in the text. (From Schaeffer: *The Nose Paranasal Sinuses, Nasolacrimal Passageways, and Olfactory Organ in Man.*)

Digitized by Illinois College of Optometry

"The sympathetic root of the sphenopalatine ganglion is the great deep petrosal nerve (n. petrosus profundus major) which is, in a sense, a direct extension of the carotid plexus. Indeed, the great deep petrosal nerve may be considered the connecting or association fasciculus between the superior cervical sympathetic ganglion and the sphenopalatine sympathetic ganglion. Most of its fibers are the peripheral processes (axons) of post-ganglionic neurons arising from cell bodies located in the superior cervical sympathetic ganglion. These post-ganglionic fibers pass through the sphenopalatine ganglion uninterrupted for distribution by way of the ganglionic branches (neurons numbered *2* in the diagram, Fig. 48). Moreover, a few of the fibers contained in the great deep petrosal nerve are seemingly the peripheral processes of preganglionic neurons arising from cell bodies located in the ventral horns of the upper thoracic spinal cord segments. These preganglionic fibers end in arborizations or synapses around the stellate cell bodies of post-ganglionic neurons located in the sphenopalatine ganglion (see neurons numbered *1* in the diagram, Fig. 48). In addition to the motor elements the great deep petrosal nerve apparently contains sympathetic afferent fibers, the cell bodies of which are located in the ganglia of the dorsal roots of the upper thoracic spinal nerves. Further study is necessary to definitely establish these afferent sympathetic elements. Certain laboratory experiences and clinical evidence tend to support the existence of sympathetic afferent elements in the great deep petrosal nerve (see neurons numbered *8* in the diagram, Fig. 48).

"The sensory root of the sphenopalatine ganglion consists of the sphenopalatine nerve or nerves, e. g., of two to three short, stout trunks connecting the maxillary nerve with the upper border of the ganglion. Most of the component fibers of the sensory root are peripheral processes or dendrites of cell bodies located within the semilunar (Gasserian) ganglion of the trigeminal nerve. A few of these sensory fibers end in the sphenopalatine ganglion for the supply of the capsule of the ganglion and the capsules of its contained cell bodies (see neuron numbered *3* in the diagram, Fig. 48). However, the vast majority of the fibers of the sensory root pass either around or through the sphenopalatine ganglion without interruption in synapses

Digitized by Illinois College of Optometry

to be distributed by way of the numerous ganglionic branches (see neurons numbered *4* in the diagram, Fig. 48).

"There is some evidence that a few axons of post-ganglionic neurons (motor sympathetic) with cell bodies located within the sphenopalatine ganglion pass by way of the sensory root to be distributed with the somatic sensory fibers of the maxillary nerve (see neuron numbered *10* in the diagram, Fig. 48).

"The branches of the sphenopalatine ganglion are (1) orbital (ascending), (2) palatine (descending), (3) pharyngeal (dorsal), and (4) nasal (medial). In accordance with the foregoing paragraphs they contain vasomotor, secretory* and sensory fibers.†

"The Anatomic Relations of the Sphenopalatine Ganglion.—The small flattened triangular body of the sphenopalatine or nasal ganglion measures from 5 to 8 mm. in its sagittal plane and has its apex directed dorsally. It occupies a relatively deep position in the pterygopalatine or sphenomaxillary fossa, just caudal to the maxillary nerve and in advance of the ventral extremity of the pterygoid (Vidian) canal and in close proximity to the lateral side of the sphenopalatine foramen.

"In order that one may more fully appreciate the position and relations of the sphenopalatine ganglion, it is deemed advisable that the *pterygopalatine* (sphenomaxillary) *fossa* be briefly considered. This fossa represents in form a small inverted pyramid located at the point of juncture of the inferior orbital (sphenomaxillary) with the pterygopalatine (pterygomaxillary) fissures somewhat caudal to the apex of the orbit. The fossa is bounded *ventrally* by the infratemporal surface of the maxilla; *dorsally* by the base of the pterygoid process and the ventral surface of the great wing of the sphenoid; *medially* by the perpendicular plate of the palate bone with its orbital and sphenoidal processes; and *cephalically* by the caudal surface of the body of the sphenoid bone. Three important fissures terminate in the pterygopalatine fossa; e. g., the superior orbital, the pterygopalatine and the inferior orbital; leading thereby

*Prevost found that feeble electrical stimulation of the exposed sphenopalatine ganglion caused a copious secretion of mucus in the nasal fossa. Moreover, an increase in the nasal temperature and dilatation of the blood vessels was noted.

†The reader is referred to pages 306 to 310 (Schaeffer's book) for a discussion of the ganglionic branches in their distribution to the nasal fossa, the paranasal chambers, etc.

Digitized by Illinois College of Optometry

to a connection with the cranial cavity, the infratemporal fossa and the orbital cavity, respectively. In the articulation of the palate bone with the sphenoid, the sphenopalatine notch of the former, forms with the sphenoid bone a window or aperture, the *sphenopalatine foramen,* communicating between the pterygopalatine and the nasal fossae immediately dorsal to the superior nasal meatus and caudal to the body of the sphenoid. Six foramina communicate with the pterygopalatine fossa: one, the *sphenopalatine,* on the medial wall; three, the *foramen rotundum,* the *pterygoid* (Vidian) *canal* and the *pharyngeal* (pterygopalatine) *canal,* on the dorsal wall; one, the orifice of the *infraorbital canal,* on the ventral wall; and caudally the apex of the pterygopalatine fossa narrows into and continues as the *pterygopalatine* (posterior palatine) *canal* and the *accessory palatine canals.*

"When one recalls the structures that either enter or are wholly located within the pterygopalatine fossa, such as the maxillary nerve, the Vidian nerve, the sphenopalatine ganglion with its outflowing branches, etc.; moreover, that the sphenoidal and posterior ethmoidal air cells very commonly encroach to a marked degree upon the confines of the pterygopalatine fossa and secondarily upon the contained structures, one at once appreciates the importance of a clear understanding of the anatomic relationships; e. g., the topographic anatomy, of the region of the pterygopalatine fossa in dealing with nasal and paranasal disorders.

"Owing to the position of the sphenopalatine ganglion in the sphenopalatine fossa in close proximity to the sphenopalatine foramen, it is subject to surface influences from both the nasal fossa and certain paranasal (accessory) sinuses. The nasal mucous membrane and a variable but small amount of areolar tissue alone intervene between the ganglion and the nasal cavity in the recent or undissected state. The intimacy of the relationship between the ganglion and the nasal mucosa varies to a limited degree in different individuals. Moreover, the size of the sphenopalatine foramen is variable and when unduly large increased mucosal relations necessarily obtain. The extreme pneumatizations of the sphenoidal and posterior ethmoidal cells commonly encountered lead to additional intimate and impor-

Digitized by Illinois College of Optometry

tant relations between the respiratory mucous membrane and the sphenopalatine ganglion. A lamina of bone of papery delicacy and mucous membrane not infrequently alone intervene between the outside air and the ganglion. Indeed, the bone may be actually wanting; e. g., dehiscences may be present, thereby bringing the ganglion into intimate relationship or actual contact with the mucous membrane of the paranasal sinuses in question. It is particularly in those cases in which the sphenoidal sinus extends ventrocaudally recess-like into the pterygoid process (base and laminae) of the sphenoid and into the orbital process of the palate bone and occasionally into the ethmoid bone by encroachment on posterior ethmoidal cells or by replacing them that the very intimate ganglionic relationships are established. The intimacy of the relationship is, of course, dependent upon the direction and degree of the pneumatization. At times a posterior ethmoidal cell (or cells) replaces the extension of the sphenoidal sinus into the orbital process of the palate bone. Indeed, ethmoidal extensions may take place into the sphenoid bone, even pneumatizing into the root of the pterygoid process. In such cases the sphenopalatine ganglion bears a much more intimate relationship to the posterior ethmoidal cell or cells than it does to the sphenoidal sinus.

"Witness for example, the dissection represented in Fig. 49. Here the sphenoidal sinus on the right side of the body shows extensive pneumatization extending to the left beyond the midsagittal plane at the expense of its fellow. The right sinus has pneumatized into the basilar process of the occipital bone, the peterygoid process of the sphenoid bone, the orbital process of the palate bone, and has actually extended forward into the dorsal extremity of the ethmoid bone. The sphenoidal extension into the orbital process of the palate bone (the palatine recess of the sphenoidal sinus) is separated from the dorsocephalic extension of the maxillary sinus by a mere film of bone. A large posterior ethmoidal cell has likewise pneumatized into the orbital process of the palate bone and is throughout separated from the sphenoidal sinus by an extremely thin lamella of bone. It is obvious in such specimens that involvement of the sphenoidal sinus or of the posterior ethmoidal cell may readily influence the maxillary sinus and vice versa. Moreover, these several sinuses,

Digitized by Illinois College of Optometry

due to the extreme pneumatization, establish the most intimate relationship with the sphenopalatine foramen and the sphenopalatine ganglion. Sometimes posterior ethmoidal cells are superimposed, one over the other; the more caudally placed of which is the more intimately related to the sphenopalatine ganglion. Again, a posterior ethmoidal cell may extend its pneumatization into the body of the sphenoid bone and replace the

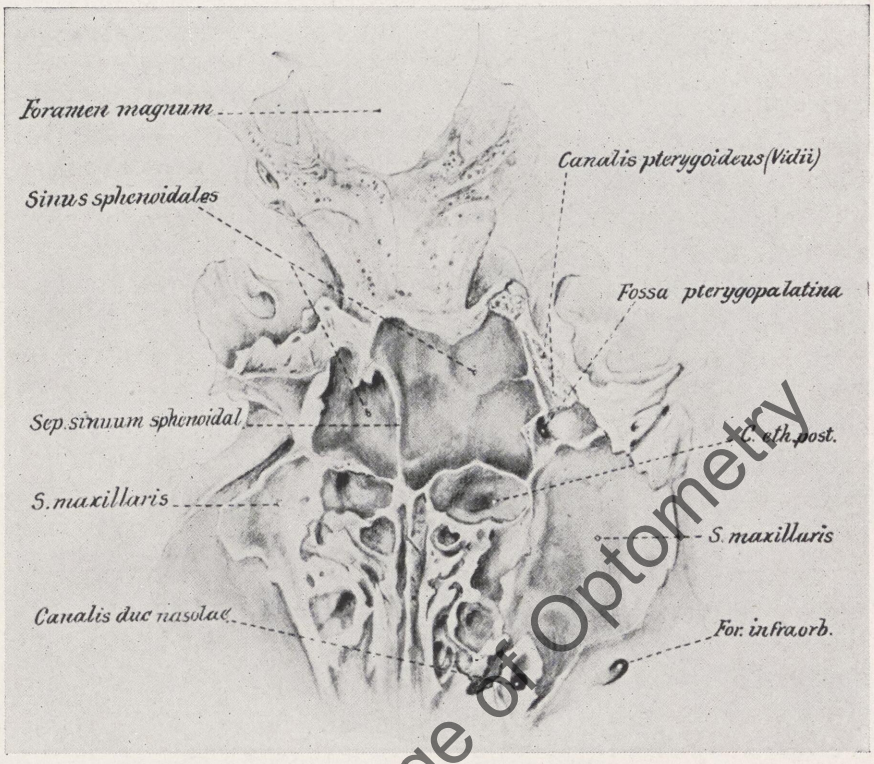

Fig. 49.—A basal dissection of the sphenoidal and maxillary sinuses. Particularly note that the right sphenoidal sinus has pneumatized forward into the ethmoidal region and established an immediate relationship with the maxillary sinus, a thin lamella of bone alone intervening. Note also the asymmetry of the sphenoidal sinuses. (From Schaeffer: *The Nose Paranasal Sinuses, Nasolacrimal Passageways, and Olfactory Organ in Man.*)

ventrosuperior portion of the sphenoidal sinus. This does, however, not preclude the extension of the sphenoidal sinus into the root of the pterygoid process and its encroachment upon the pterygopalatine fossa with its contained sphenopalatine ganglion.

Digitized by Illinois College of Optometry

"Anatomical Relations of the Nerve of the Pterygoid Canal.—In a study dating from 1907* the author has had opportunity to observe the relations of the nerve of the pterygoid canal (Vidian nerve) in an extremely large number of cadavers. These observations were made in regular dissections and in sections through the various planes and at different ages. In many of the specimens studied the floor of the sphenoidal sinus is separated from the pterygoid (Vidian canal) by a fairly thick layer of compact bone. However, there is a large percentage of specimens in which the sphenoidal sinus extends its pneumatization caudally and ventrally into the root of the pterygoid process. Indeed, the extension may pass beyond this, either medially or laterally or both, into the plates of the pterygoid process. In such instances the pterygoid canal with its contained Vidian nerve and vessels is at best merely separated from the mucous membrane of the sphenoidal sinus by an extremely delicate layer of bone. *Indeed, in the majority of such cases the canal is thrown into marked relief in the floor of the sphenoidal sinus so that it forms a distinct watershed dividing a lateral from a medial pterygoid diverticulum or recess of the sphenoidal sinus.* Again, it is not an unusual condition to find pterygoid canals in which the thin layer or bone is actually wanting (dehiscences), thereby exposing the contained Vidian nerve and accompanying blood vessels to the influences of the outside atmosphere or of an infected sphenoidal sinus. The mucous membrane of the sphenoidal sinus alone is interposed between the sinus cavity and the Vidian nerve, etc. Witness, for example, Figs. 133, 139, 195 and 197† in which the nerve of the pterygoid canal courses across the cavity of the sphenoidal sinus at a considerable distance above the sinus floor proper, thereby throwing the mucous membrane into marked relief."‡

The *environment* of the ganglion is of the greatest importance for the clinician. No mention of it has been made more than "it lies deep in the sphenomaxillary fossa" or "close to the sphenopalatine foramen."

*The first reference by the author concerning these observations was made at an Anatomical Seminar at Cornell University in 1909.

†See pp. 177, 190, 307, and 309 Schaeffer's book.

‡See also Greenfield Sluder, Archiv. f. Laryngol, u. Rhin., 1913, xxvii, No. 3; Annals Otol., Rhin., and Laryngol., 1913, 1914, and Ladislaus Onodi, Jour. Laryng., Rhin. and Otol., 1914, for instructive and valuable anatomico-clinical considerations of the Vidian and other nerves.

Digitized by Illinois College of Optometry

Anatomical Relations.—The treatises on anatomy describe the nasal (sphenopalatine-Meckel's) ganglion "as lying in the sphenomaxillary fossa close to the sphenopalatine foramen." (Quain, Piersol, and others.) The sphenomaxillary fossa is described as "formed above by the under surface of the body of the sphenoid and the orbital process of the palate bone; in front, by the superior maxillary bone; behind, by the anterior surface of the base of the pterygoid process and lower part of the anterior surface of the great wing of the sphenoid; internally, by the vertical plate of the palate."*

Neither this description nor any found in other textbooks on anatomy suggests any close relation of the nasal ganglion

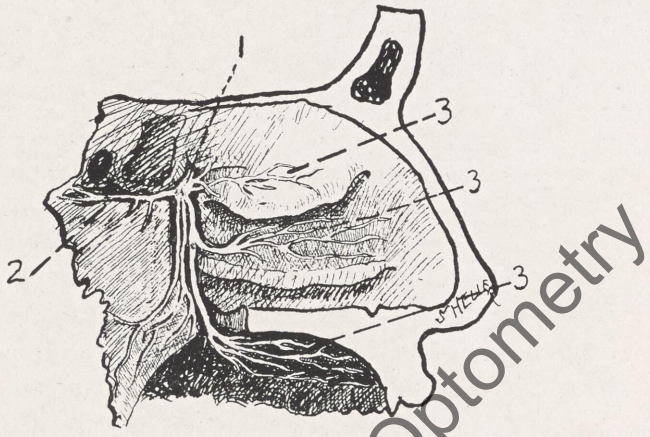

Fig. 50.—*1.* Nasal ganglion. *2.* Vidian nerve. *3.* Nasal and palatal branches. (After Quain.)

to the nose or the paranasal cells (sinuses); nor do the special treatises upon the nose make mention of such relation.† As a matter of fact, however, the nasal ganglion lies very close to the lateral bony wall of the nose, in which the sphenopalatine foramen occurs as a small deficiency at its upper posterior part. By actual measurement the nasal ganglion frequently lies as close as one or two millimeters from the nasal mucous membrane; it may lie as deep as seven or even nine millimeters. Krause, whose text was found after the preceding observations were made, states that there are sometimes two ganglia, one sus-

*This description is taken from Gray's Anatomy, 1896.

†This statement in 1918 was true. At present recognition must also be given to the excellent work of J. P. Schaeffer[3] who has arrived at similar conclusions.

Digitized by Illinois College of Optometry

pended on each sphenopalatine nerve. He also states that it sometimes projects through the sphenopalatine foramen to lie submucous to the nose.

The current descriptions of the sphenomaxillary fossa give the impression of its being surrounded by solid bones. This

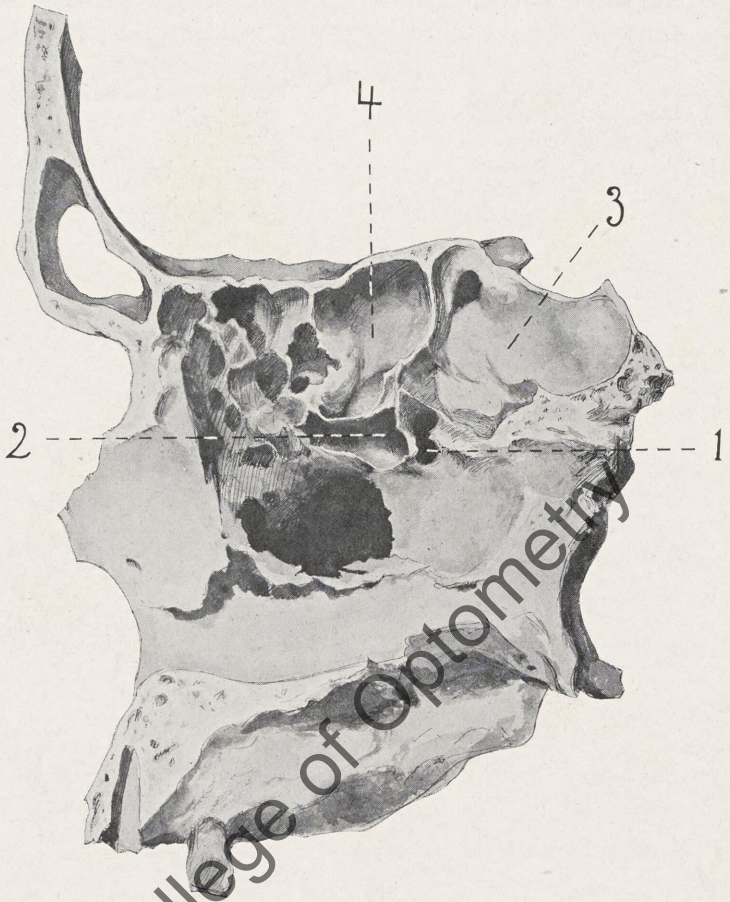

Fig. 51.—Showing sphenopalatine foramen *1* bounded above by sphenoidal sinus *3*, and in front by ethmoidal cells *2* and *4*. The sphenopalatine foramen is in the inner limit of the sphenomaxillary fossa.

also is misleading. More comprehensively, the description "formed above by the under surface of the body of the sphenoid and the orbital process of the palate bone" means that it is bounded above by the walls of the *sphenoidal sinus,* including the sphenoidal process of the palate bone closing it, and that

Digitized by Illinois College of Optometry

the *separating wall* is a *thin one.* The description "in front, by the superior maxillary bone," means that it is bounded in front by the wall of the *maxillary sinus* and that this wall too is of *thin* bone. The description "behind, by the anterior surface of the great wing of the sphenoid" means that this wall also is, in some cases, only a thin plate separating the fossa from a *downward prolongation* of the *sphenoidal sinus* into the

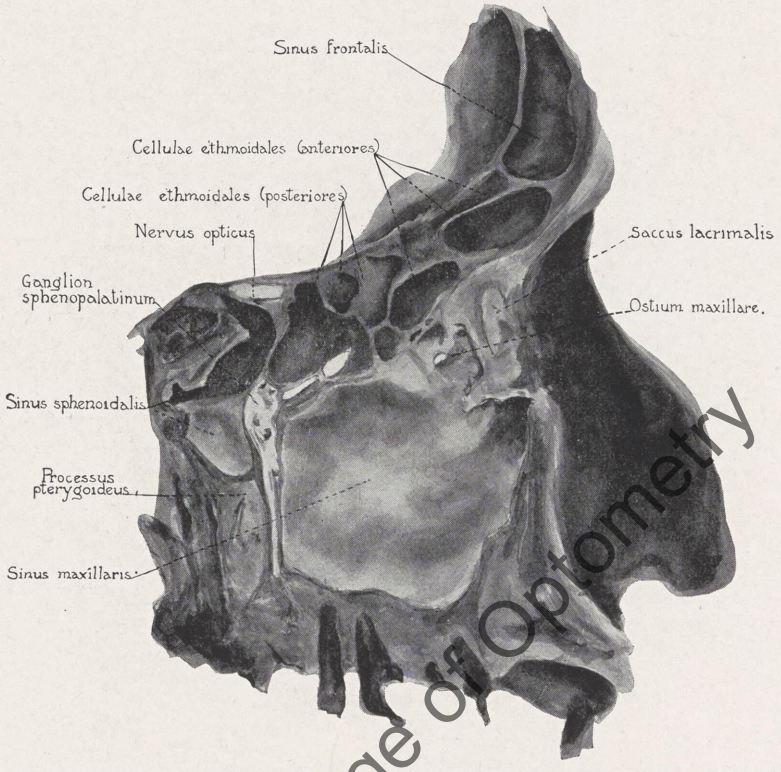

Fig. 52.—Sagittal section 7 mm. lateral to the sphenopalatine foramen. (Specimen decalcified in hydrochloric acid.)

pterygoid process to the bifurcation of the plates, and into *the great wing;* a condition which is not uncommon, although in the majority of cases the pterygoid process is of solid bone. J. P. Schaeffer[3] records the fact that the pterygoid process may be hollowed (pneumatized) by a post-ethmoidal cell.

The *outer* aspect of the sphenomaxillary fossa is then the *only one* that is not in intimate association with the cavity of the nose or the paranasal cells.

Digitized by Illinois College of Optometry

It seems *essential* that in a *comprehensive* description of these parts special emphasis should be laid upon their *intimate relations* to the nose and paranasal cells.

The variations of the paranasal cells ought also to be studied in detail: The sphenoidal sinus may form the entire upper boundary of the sphenomaxillary fossa. (Fig. 51.) The sphenoidal sinus may also form the posterior boundary of the

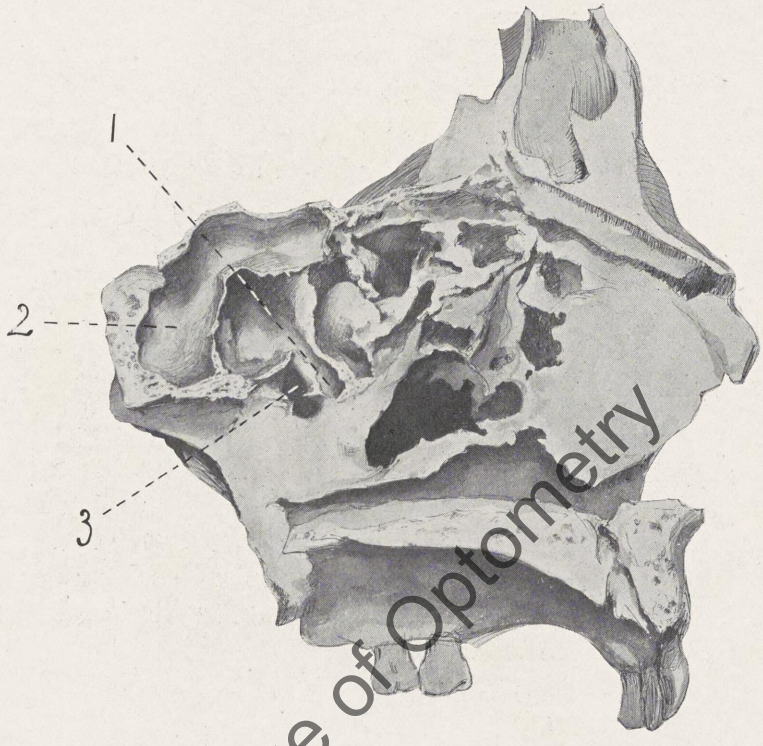

Fig. 53.—Showing left sphenoidal sinus *1*, prolonged downward in front to form the anterior wall of the sphenomaxillary fossa *3*. *2*. Right sphenoidal sinus.

sphenomaxillary fossa as a result of its being prolonged downward into the pterygoid process and great wing (Fig. 52). A post-ethmoidal cell may bound the anterior half of the upper part of the fossa (Fig. 51). The sphenoidal sinus may be extended downward and forward to form the upper half of the anterior boundary of the fossa (Fig. 53). *The wall of the nose* may curve so *sharply outward* as to form a part of the *anterior boundary* of the fossa.

Digitized by Illinois College of Optometry

The nasal ganglion lies high up in the sphenomaxillary fossa. It is apparently prolonged backward into the Vidian (pterygoid) nerve. (Quain, *Anatomy,* 1897.) (Fig. 54.) There is usually a marking upon the bone corresponding to this; a well-modeled funneling at the anterior end of the canal (Fig. 55).

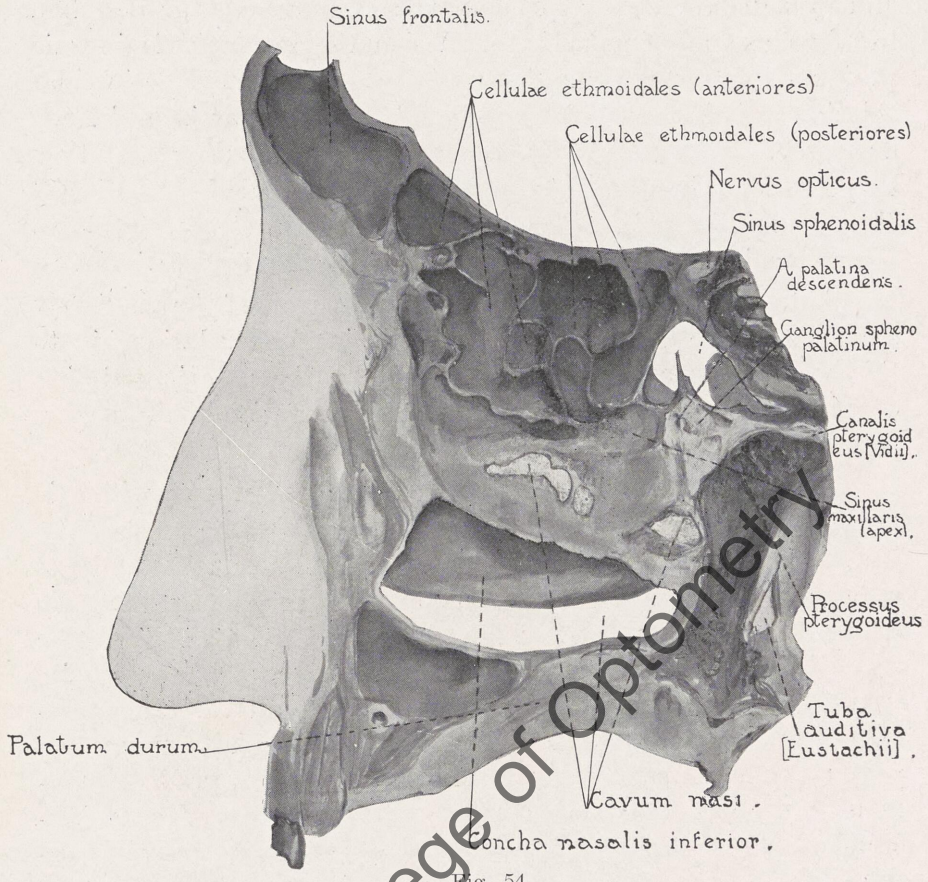

Fig. 54.

Relations of the Nasal Ganglion in the Sphenomaxillary Fossa.—The ganglion lies close to the top of the sphenomaxillary fossa. (All textbooks are agreed upon this point.) In front the ganglion is in relation to the arteria palatina descendens and arteria sphenopalatina and to the corresponding veins. These vessels, with some surrounding connective tissue, form a separation of 3 or 4 mm. from the wall of the maxillary sinus—the anterior boundary of the fossa.

Digitized by Illinois College of Optometry

The Relations of the Nasal Ganglion to the Walls of the Paranasal Cells.—When the upper boundary of the fossa is formed entirely by the sphenoidal sinus, the ganglion lies in close relation to the sphenoidal sinus. When the upper boundary of the fossa is made by the sphenoidal sinus in its posterior half and by a post-ethmoidal cell in its anterior half, the ganglion lies in close relation to both. When the sphenoidal sinus is prolonged downward and forward the ganglion will lie in close relation to it in front. When the sphenoidal sinus is prolonged downward into the pterygoid process, the ganglion will then lie posteriorly in close relation to the sphenoidal sinus. Fig. 53 shows a specimen in which the ganglion is in close relation to the sphenoidal sinus anteriorly, superiorly, and posteriorly.

Anteriorly the fossa is formed by the wall of the maxillary sinus. But the ganglion can never lie in close relationship to this wall because of the pad formed by the arteria palatina descendens and the arteria sphenopalatine with their accompanying veins and surrounding connective tissue (Fig. 56).

Arthur M. Alden,[1] however, has reported a case which is probably an exception to this rule. (The only one on record.) He had a patient with a typical lower half headache, and the only recognizable nasal lesion was an empyema of the maxillary sinus, for the treatment of which he performed a Caldwell-Luc operation. While he had the cell open, and was inspecting its interior, he observed that the most (almost all) of the pathological process within the cell was located at or on its uppermost posterior mesial portion. Here he found a high grade inflammatory process with well marked gross changes. The subsequent course of the case was uneventful recovery from the suppuration and the lower half headache.

In Dr. Alden's case the localization of the lesion was at the anterior boundary of the position of the nasal ganglion, ideally placed to irritate it if possible. This patient, however, had one (or both) of two things. Either he had an unusually small amount of tissue between the ganglion and the anterior boundary of the sphenomaxillary fossa, or he had a particularly virulent lesion at that site. From the fact that this case is so rare I am disposed to think the former to be the explanation of the

Digitized by Illinois College of Optometry

clinical picture. All rhinologists have seen virulent general inflammation of this cell without lower half headache.

J. I. Dowling states that he has often relieved nasal ganglion neurosis by operation on the maxillary sinus. He has also reported cases of phlyctenular keratitis relieved or cured by maxillary sinus irrigation even without pus. Besides these reported cases I am not familiar with this lesion as a frequent occurrence either in my private practice or in the service at the St. Louis Children's Hospital and the Clinic of the Washington University School of Medicine, neither am I familiar with the maxillary sinus being the etiological factor in phlyctenular keratitis.

The Relation of the Nasal Ganglion to the Lateral Wall of the Nose.—The sphenopalatine foramen is accurately placed at a point just posterior to and immediately above the posterior

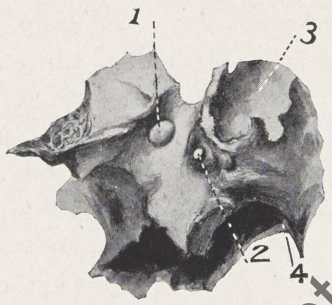

Fig. 55.—Showing anterior face of right pterygoid process. *1.* Foramen rotundum. *2.* Anterior outlet of Vidian canal. *3.* Right sphenoidal sinus. *4.* Right nasal fossa.

tip of the middle turbinate. I have seen only one specimen that varied from this rule (Fig. 58). (I have carefully examined many hundreds of specimens including the material in the National Museum, Washington, D. C.) No anatomist has described such a variation. The ganglion usually lies close to the plane of this foramen. (Fig. 57.)

The ganglion does not, however, always show the same relation to the foramen. I have found it as close as one or two millimeters from the general membrane of the nose, and as far as nine millimeters. I have found the variation in the position of the ganglion, whether higher or lower, to be very slight. Fig. 58 is a marked exception.

Digitized by Illinois College of Optometry

The sphenomaxillary fossa considered from this point of view is seen to resemble—is *tantamount* to—a paranasal cell. It is, however, not closed externally by nasal tissues and is filled by the before-mentioned structures with their accompanying connective tissue instead of air. Below it is closed by the apposition of its anterior and posterior walls.

Clinical Relations.—With such intimate anatomical association, clinical manifestations from the extension of inflamma-

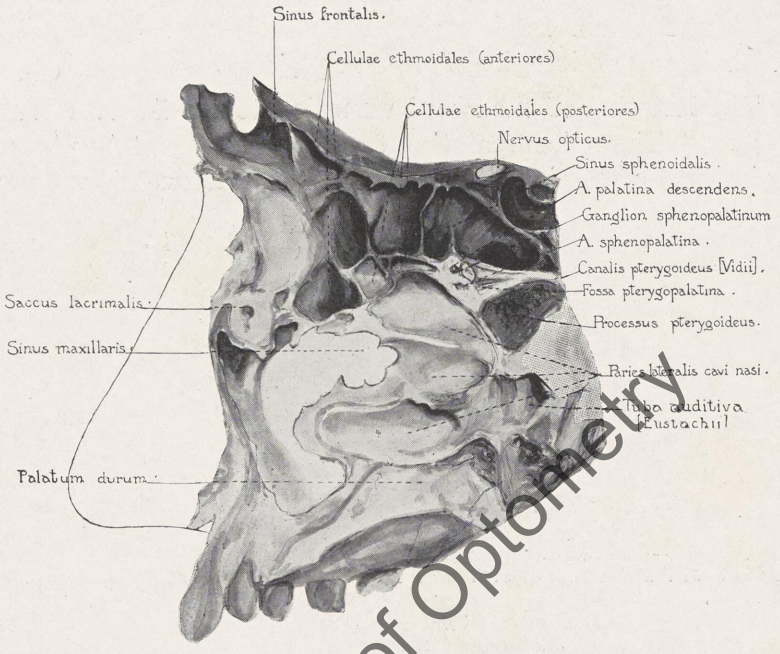

Fig. 56.—Sagittal section 3 mm. lateral to the sphenopalatine foramen, showing a dissection of the sphenopalatine fossa. (Specimen decalcified in hydrochloric acid.)

tion in the nasal fossa or its products would seem of almost necessary occurrence. The nasal ganglion is, in fact, in *quite as close relation to the nose and the paranasal* cells as is the optic nerve. It has long been recognized that inflammatory processes in the sphenoidal and post-ethmoidal sinuses extend to the optic nerve, and this fact has been demonstrated post-mortem by Birsch-Hirschfeld,[2] Uffenorde,[1] and others. Latterly de Kleijn and Gerlack have found at autopsy a sphenoidal sinus filled with pus containing an encapsulated diplococcus which

Digitized by Illinois College of Optometry

was also found in the membrane of the sinus, the bone of the optic canal, the sheath of the optic nerve and in the nerve. It was followed forward into the eyeball. I also have *seen* lesions on the *optic canal* in *life* by means of Holmes'[1] nasopharyngoscope (page 372), illustrating this fact in a most striking manner both at the time of opening the sphenoid and as subsequent phenomena in the course of the case. It is therefore altogether

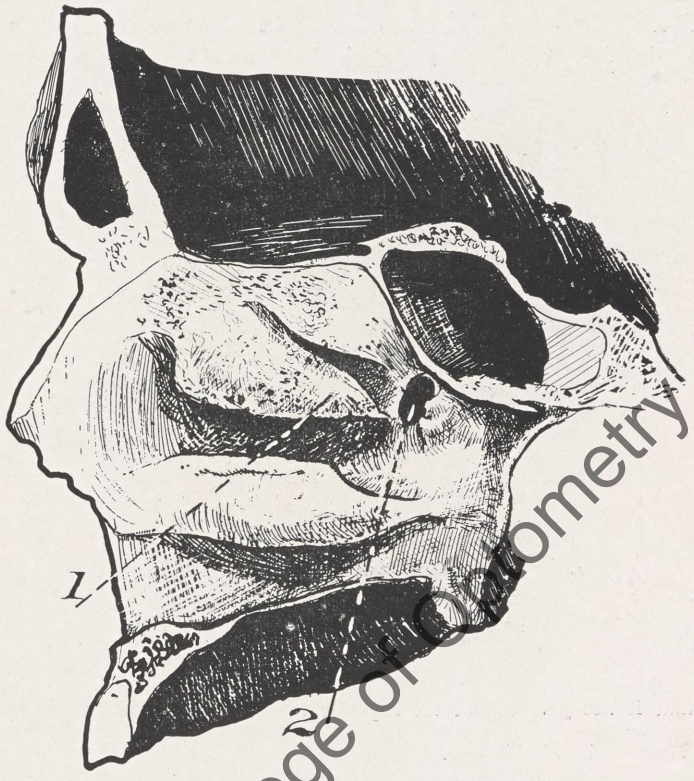

Fig. 57.—Showing *1* middle turbinate. *2*. Sphenopalatine foramen directly posterior to and slightly above posterior tip of middle turbinate.

reasonable to assume that these processes also pass over to the nasal ganglion, although the clinical picture is very much less evident than the blindness produced by involvement of the optic nerve.

According to my observations characteristic disturbances have followed post-ethmoidal and sphenoidal suppurative inflammations which cannot be explained otherwise than by as-

Digitized by Illinois College of Optometry

suming that the nasal ganglion has become involved by extension; some of these disturbances have been transitory, and some have persisted for many years. In other cases the conviction has been equally positive that the extension has been from the nose proper. Thus far, I have not seen anything that I could interpret as an extension from the maxillary sinus. From the anatomical relations of the nasal ganglion to the anterior boundary of the sphenomaxillary fossa, i. e., to the posterior wall of the maxillary sinus, I do not believe that it is at all likely to be involved by extension of an inflammatory process

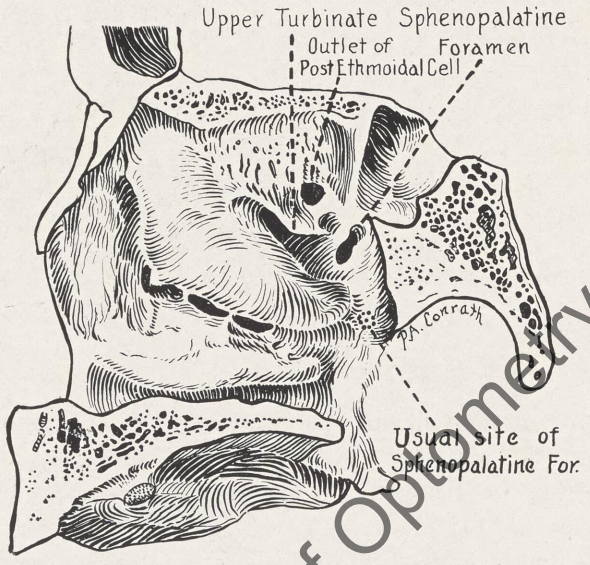

Fig. 58.—Showing an unusual placement of the sphenopalatine foramen. Observe that it lies just behind the superior turbinate. This is the only specimen that I have ever seen in which this was true, including the large collection of the National Museum in Washington.

from that sinus, inasmuch as the arteria palatina descendens and the arteria sphenopalatina, together with their accompanying veins and the surrounding connective tissue, lie between the ganglion behind and the wall of the maxillary sinus in front. This relation appears to be constant and, I believe, explains why clinical manifestations referable to the ganglion do not ordinarily follow inflammatory processes in the maxillary sinus. Furthermore, pus in the maxillary sinus will remain much below this level, which may possibly be another factor in the

Digitized by Illinois College of Optometry

explanation. Alden[1] recently reported a case, mentioned on page 88, which proves that ganglion involvement may follow maxillary sinus disease despite the anatomical position of the ganglion.

During 1907 I saw a number of cases of acute suppurative inflammation, of grippe origin, in the sphenoidal and post-ethmoidal cells, which were relieved of the suppuration in from three to four weeks, but the pain still remained and seemed neuralgic in nature. (Sometimes the neuralgic manifestations arose a few days after the inflammatory onset.) The peculiar dull pain of the suppurating sphenoid referred to the occiput, or the post-ethmoidal cells referred to the parietal eminence, usually preceded these neuralgic phenomena. In 1914 I[42] recognized a symptom-complex referable to the sympathetic autonomic elements of the ganglion. In a preliminary report,[40] based on ten cases, I described certain of these manifestations; now, after an observation of several hundred cases, it is possible to draw a more complete clinical picture.

"Lower Half Headache"

The Neuralgic Syndrome with the Usual Forerunner

A patient presenting all the features will tell of a coryza of lesser or greater severity—sometimes astonishingly slight and often forgotten, or, it may have produced a post-ethmoidal-sphenoidal empyema. (It has been my observation that many times patients are unconscious of coryzas, but still examination shows that an inflamed membrane is the cause of headache, usually sphenoidal.) A short time later, pain began at the root of the nose, in and about the eye, the upper jaw and teeth, sometimes also the lower jaw and teeth, and extended backward to the temple and about the zygoma to the ear, causing earache; emphasized at the mastoid, but always *severest at a point 5 cm. back* of that (which is almost always quite sensitve to pressure); thence reaching backward by way of the occiput and neck, it may extend to the shoulder blade and shoulder (less often to the axilla and breast), and in severe attacks to the arm, forearm, hand, and even the finger tips. (See cases 14, 15, 33 and 42.) This is the most frequent picture, but at times there may be

Digitized by Illinois College of Optometry

also a sense of "stiff" or "aching" throat; or of pain (oftener itching) in the hard palate; or pain inside the nasal fossae; or a feeling that the teeth are "too long"; or a perverse (metallic) sense of taste (parageusia) (rare) (Cases 35 and 36) or scotoma scintillans (rare) (Case 105) or salivation (rare). Itching of the shoulders and upper extremity has been observed. The sense of taste is slightly less acute over the anterior two-thirds of the tongue on the affected side. Rarely, in the beginning or at the height of the attack it is slightly more acute. The arch of the soft palate is higher on the affected side; the uvula and dimple which forms above it on gagging are deflected to the well side. A slight blunting of sensation is found in the nose and throat as far down as the tonsil on the affected side. There may be a sense of stuffy ears, which are easily inflated with but short relief. I have construed these as tubes which are not opened normally by the levator palati; and that this happens because the motor function from the ganglion is lessened at the time of the attack of pain. As the pain subsides this symptom disappears. Mild cases are described as a sense of tension in the face and stiffness or "rheumatism" in the shoulder and neck. A great degree of soreness or stiffness may remain in the neck and shoulder after the pain of a severe attack has been stopped by treatment, either by cocainization of the nasal ganglion or anodynes internally. There are numerous texts in the literature dealing extensively with stiff and sore neck in which the argument is made that they are myalgia or neuralgia or sternocleidomastoid rheumatism (Aswadurow, Sjöstrom). I believe these cases to be primarily nasal ganglion neuralgia. At the time of description the other parts of the picture were for the most part no longer present. This question will be more fully discussed in Chapter VII.

The Sympathetic Syndrome.—The above described picture is sometimes supplemented by a sympathetic syndrome very wide in its distribution and wondrously complex, a prominent part being vasomotor and secretory phenomena. And sometimes it happens that these are the *only* symptoms of disturbance in the nasal ganglion. I think, however, that the sympathetic syndrome occurs less often than the painful syndrome. But a sharp division is often impossible because the sympa-

Digitized by Illinois College of Optometry

thetic syndrdome is often mixed with the neuralgic syndrome. They may alternate in the same patient (see Case 9). The same etiology is found.

Inflammation of more or less severity in the district, usually has preceded the vasomotor-secretory phenomena. They may be aroused by a slight coryza that has had little time for development, and appear with explosive effect, out of proportion to the pathological lesion (apparently). The patient in health is for the first time, regardless of the season of the year, seized with severe and protracted sneezing accompanied by much nasal congestion and thin hot secretion, so profuse at times as to have him resort to a towel for use as a handkerchief. With the great congestion of the nasal fossae is found great sensitiveness of the internal nose (Case 48), with marked redness (congestion) and swelling of the external nose, and soon thereafter, may appear more or less roughing of the skin from the secretion and the wiping it necessitates. In addition to these symptoms, the eyes are greatly reddened (congestion of the conjunctiva) (Cases 52, 55) and bathed in tears of a profusion corresponding to the nasal secretion, accompanied by dilatation of the pupil and the appearance of staring. The lids are wide open, giving the appearance of prominent eyes. (One patient had a slight exophthalmos, Case 104.) They are involved almost if not quite simultaneously with the nose. A sense of itching or burning, or a feeling of wind blowing into them accompanies the lacrimation, together with a feeling of discomfort of a peculiar kind which seems independent of the secretion and congestion; and there may be the greatest photophobia or sense of intense light when *no light at all is present.* Work requiring near vision is usually very difficult or not possible under these conditions. Sometimes these symptoms are accompanied by dyspnea with dry râles (asthma). (Cases 44, 45, 46 and 47.)

This description in the main is at once recognized by rhinologists as "the terrible or terrific cold" which has been described with great emphasis by patients from time to time. For a number of years I have thought that these were symptoms on the part of the sympathetic which supplies the nasal ganglion, and felt that cocaine could be used to control them. Various other thoughts prevented me from drawing conclusions

Digitized by Illinois College of Optometry

from cases of longer standing (vasomotor rhinitis, hay fever, paroxysmal sneezing, rhinitis nervosa). During the recent past, however, I have had these cases so acute and so severe that they seemed perfect for the experiment. The nasal ganglion was cocainized usually from its internal aspect, that is, the sphenopalatine foramen—the side from which the Vidian nerve enters. One-half of one drop saturated watery solution (90%) was applied, sometimes once only, and sometimes repeated. The effect was to quickly stop the secretion in the nose and eyes and bring them back to normal appearance. The swollen, red nose (rosacea) (Case 48), and the puffed, red, disabled, staring, tearing eyes became normal, and likewise the nasal fossae; the photophobia ceased and the pupils contracted.

Further experience revealed that these cases in their behavior to cocaine were not unlike the painful ones arising from the ganglion. Cocainization (once) was curative for those that were provoked by a slight inflammatory condition. Those arising in the wake of more pronounced change—post-ethmoidal-sphenoidal inflammations—but of short duration, often yielded to a few applications repeated from day to day. (Cases 50, 52, 55.) Two per cent silver nitrate and 2 per cent mercurochrome are helpful in older cases. Severe, long-standing cases were sometimes not helped by anything short of injection and then very little or not at all by one injection. They required reinjection. These cases have often lost the superficial appearances shown by the more recent ones. A considerable percentage of the ordinary coryzas is of this type (sympathetic). Deep infection of the membrane which leads to suppuration of the sinuses is of course not to be classed with these cases. When the sympathetic attributes (vasomotor, secretory, etc.), are once added to the picture they are very apt to recur more or less marked in subsequent coryzas.

When the disease lasts a little longer, the paroxysms begin to appear irregularly and often settle down into the morning sneezing of "rhinitis nervosa." The clinical course of a given case may be of the purely sympathetic type, but upon questioning closely, it is very often found that a low grade ganglion neuralgic complement exists (lower half headache), which the patient often refuses to have connected with his nasal disturb-

Digitized by Illinois College of Optometry

ances. He maintains that his head, neck, shoulder, etc., pains, are "rheumatism," or "stiff muscles" or "neuritis" or some one of a dozen explanations which are absolutely satisfactory to him and about which he does not want to have his mind changed. Following these cases further, it appears that the syndrome becomes subdivided and betrays itself as single symptoms; e. g., eyeache, earache, toothache, neckache, etc. So it happens that the sympathetic symptom-complex may present the single symptom—sneezing—or thin secretion, or the eye disturbances which simulate a low grade conjunctivitis with asthenopia; and a few times I have seen a red external nose (rosacea) of this origin.

From continued experience with this class of cases I believe it possible to have any one of the symptoms appear as an isolated phenomenon. In 1922 I[21] called attention to a number of such phenomena, namely, glossodynia (Cases 34, 35), otalgia (Case 60), nausea (Case 58), paraguesia (Cases 35, 36), vertigo (Cases 56, 57), scotoma (Case 105), photophobia (Cases 101, 104), rhinorrhea (Case 51), and asthma (Cases 44, 45, 46, 47). In addition to these phenomena there are others that are controllable through the nasal ganglion and in which there are no pathological changes demonstrable in the ganglion district, namely, earache of inflammatory origin,[33] the control of external cricoidynia,[14] of pain in the mandible,[34] of lower jaw toothache, of earache secondary to cancer of the larynx, of the pain of laryngeal tuberculosis of ophthalmic migraine,[25] also abdominal pain, diarrhea[30] and nodular headache[1] (Case 26).

It is not possible at present to explain the various nerve manifestations produced by inflammation in these parts; i. e., why one case suffers from the neuralgic part of the syndrome only and why another under the same macroscopic appearances suffers only the sympathetic syndrome, and why they may alternate in the same patient. I believe that others suffer only the motor disturbances, but I am not sufficiently assured of this to make a positive statement to that effect.

The only speculation that seems probable to me is that the toxins of the inflammatory lesions that clinically appear identical, are variable, probably corresponding to different infections, some of which have not been identified bacteriologically. Selective action of drugs and stain is well known. I see no reason

Digitized by Illinois College of Optometry

why toxins should not have a selective action. Were this admitted, explanation of the interchanging clinical pictures becomes easily understandable. One toxin may act on the involuntary fibers only, another on the sensory fibers only, including the afferent elements of the facial, and possibly another only on the motor fibers. I have applied ragweed pollen extract to the nasal ganglion district of a hay fever patient and produced violent sneezing and asthma, but no headache. The constitutional condition of the patient under these conditions unquestionably plays a prominent part in such actions. Sensitization may be a part of the selective action. I have seen this patient in many headaches of inflammatory origin in the post-ethmoidal-sphenoidal district, and in the hay fever season, but once I saw the same macroscopic lesion produce the syndrome of hay fever with asthma in the month of February without headache. Anesthetizing the nasal ganglion for this patient uniformly stops the asthma or headache regardless of the season.

The more unusual phenomena are even more strikingly out of the line if inductive philosophy, i. e., that injection of the nasal ganglion should cure a most pronounced red and enlarged external nose, a most pronounced writer's cramp (Case 38), a most pronounced blepharospasm (Cases 105, 106, 107, 108), a most obstinate, recurrent superficial corneal ulceration (Case 71); and equally striking has been the almost kaleidoscopic change—betterment of some of the severest disorders of the uveal tract (Case 70) immediately following complete anesthesia of the nasal ganglion. That the severest pain of photophobia, glaucoma, functional hyperesthesia of the ciliary muscle (Sluder[10]), iritis, corneal ulcers, phlyctenular keratitis, intersititial keratitis —may be stopped by anesthesia of the nasal ganglion, frequently with immediate betterment, is to me almost at once striking and strange.[29] According to present thought, the only explanation for this is that it is the involuntary system (sympathetic or cranial autonomic) by way of the nasal ganglion that conveys the pain sense to the occiput and neck, from these lesions, and that the influence upon the eye lesions is also exerted through the involuntary system; and that it is done by a nerve blocking at that point. Stopping pain influences the lesion for the better. The fact that the pain of glaucoma could be stopped by anesthet-

Digitized by Illinois College of Optometry

izing the nasal ganglion was discovered by A. E. Ewing.[2] H. Ed Miller and W. H. Luedde[3] proved that injection of the ganglion lowered the intraocular tension of glaucoma, and that the effect was transitory. M. H. Post and I have verified this. The course of glaucoma may or may not be influenced by treatment of the nasal ganglion. No clear statement can be made on this point at present. (See cases 59 and 98.)

It is generally admitted that the functions of the involuntary nervous system, among others, are vasomotor and secretory. Sensory attributes have also been proved for it. Buch states that the impulses that travel over these (sensory) fibers do not under ordinary circumstances give rise to sensations, but expend themselves in the production of visceral reflexes. Pathologically they give rise to pain. Anatomically the fibers of the cervical sympathetic from the nasal ganglion pass upward or downward by way of the Vidian and carotid plexus to the cervical sympathetic and its ganglia and give branches to the cervical nerves and proceed finally to the lower cervical ganglion which is in intimate connection and often fused with the first thoracic. These ganglia are anatomically in association with, or allied to, the nerves which in addition to supplying the neck, also make up the brachial plexus, and supply the upper extremity. Accelerator fibers for the heart and vasomotor fibers for the lungs also pass through these ganglia (Fig. 155).

Asthma of nasal origin may conveniently be referred to at this time because of the anatomical facts just mentioned. In 1919 I[6] reported some cases and speculated on the nervous pathway by which the impulse traveled. The literature on asthma is very extensive, bearing on all factors that have an apparent influence in its production, one of which is nasal. There are many instances recorded in which the correction of some nasal abnormality has been followed by relief of asthma, e. g., the removal of polyps, the drainage of a suppurating maxillary sinus, the exenteration of an abnormal ethmoid, the correction of a defected septum, the removal of a spur and probably the correction of any nasal abnormality. In my experience, however, the lesion that has produced asthma as a complication has been the post-ethmoidal-sphenoidal, either hyperplastic or suppurative.

Digitized by Illinois College of Optometry

I do not, however, challenge in any way the observations and results reported by others. Experience varies. One of the best statements concerning asthma as a nasal reflex is to be found in H. Lambert Lack's monograph *Diseases of the Nose,* London, 1905. He thinks that nothing in the literature bears on the mechanism of nasal asthma.

In the post-ethmoidal-sphenoidal district is found a ganglion of the involuntary nervous system more superficial than any other ganglion of this system. It is the only one that anatomically is easily accessible for treatment or experiment. Experiment (in my experience) has succeeded in the control of nasal asthma by cocainizing the nasal ganglion or the trunks supplying it. Cocainization of other parts of the nose has failed. I can, however, think of cocainization of the peripheral branches of the ganglion under some circumstances as being successful.

In thinking of the way such a result is obtained I have indulged in some speculation which will probably be forever impossible of proof.

The nose by way of the nasal ganglion has an involuntary nervous supply from the cranial autonomic and the sympathetic systems. Albert H. Kuntz has shown that the nasal ganglion is of bulbar origin developing on the tip of what becomes the great superficial petrosal nerve. Aside from this bulbar anatomic supply, it has a sympathetic supply from the cervical sympathetic. These fibers come from the superior cervical ganglion by way of the carotid plexus and the great deep petrosal nerve which joins the great superficial petrosal to become the Vidian and enter the ganglion on its posterior inner side. The cervical sympathetic is composed of the lower, middle and upper cervical ganglia with the nerves supplying them, connecting them and the branches. The origin of the nerves of the cervical sympathetic is from the second, third and fourth or fifth thoracic nerves (Sherington). The fibers for the head are relayed in the upper cervical ganglion, that is, the fibers, whose cell bodies are in the spinal cord, pass up to the upper cervical ganglion, being preganglionic neurons. There they synapse about the cells of the ganglion, the axons of which pass upward to the nose and cranium being post-ganglionic neurons. In this sympathetic trunk is a variety of fibers, functionally considered

Digitized by Illinois College of Optometry

to wit, pupillodilator fibers which pass to the eyeball by way of the semilunar ganglion and long ciliary nerves; motor fibers to the involuntary muscles of the orbit and nonstriped part of the levator palpebrae; vasomotor fibers to the head (vasoconstricted and vasodilator); secretory fibers to the salivary glands; pilomotor fibers to the face and neck; vasomotor fibers to the lungs and accelerator fibers to the heart; fibers to the sweat glands of the head, neck and upper limbs.

The vasomotor fibers to the lungs and accelerator fibers to the heart are relayed in the middle and lower cervical ganglia. All other fibers are relayed in the upper cervical ganglion. (Fig. 155.)

In a speculative effort to explain the mechanism of nasal asthma, I have assumed an anatomical variation in the neurons of the sympathetic and afferent attributes for the sympathetic. The preganglionic neurons for the head are relayed in the upper cervical ganglion. Here their axons synapse about the cells of the ganglion whose axons pass upward as post-ganglionic neurons, some of which reach the nasal ganglion. Vasomotor fibers for the lungs and accelerator fibers for the heart are relayed in the lower and middle cervical ganglia. One can conceive of the fibers for the head also being relayed in the lower and middle ganglia as an anatomical variation. Such variations are known in other parts of the body. If afferent properties exist in the sympathetic an impulse started by irritation or inflammation of the nasal ganglion may then be transferred by synapse to the cells of the lower and middle ganglia, whose axons are for the supply of the lungs and heart. As speculation this could explain the relief of nasal asthma by cocainization of the nasal ganglion and the production of asthma by irritation of the ganglion environment (post-ethmoidal-sphenoidal). I have succeeded with both of these experiments.

I have not been able to identify tachycardia as being of nasal origin. Bruno-Goldschmidt-Osmund, however, has made this observation.

The anatomical and physiological problems of the involuntary nerves are very complex, and a *clinician* may well hesitate approaching them; but it would seem that the knowledge of the present on this subject permits the thought that it is

Digitized by Illinois College of Optometry

a lesion of the involuntary elements of the nasal ganglion that explains not only these vasomotor secretory phenomena, but also the pain referred into the neck, shoulders, arm, etc., the Vidian neuralgia; and that these referred pains probably come to pass by virtue of the involuntary fibers which arborize about cells (Thane, Van Gehuchten, Dogiel, Retziens) in the spinal ganglia of the nerves which make, eventually, the supply of the neck and upper extremity. Also, the thought arises that it is the anatomical connection of accelerator fibers for the heart and vasomotor fibers for the lungs with the ganglia through which the cervical sympathetic passes (lower cervical and first thoracic) that explains some of the cases of asthma of nasal origin; and that the path of the impulses is from the nasal ganglion through Vidian, upper, middle and lower cervical and first thoracic ganglia, through the last two of which pass the heart and lung fibers.

Much more physiological fact is needed before such conclusions can be asserted.

I have been unable to find any statement of what influence is exerted over nerve fibers in their passage through a ganglion with whose cells they have no other relation. Moreover, the question may arise whether such a state of things exists physiologically or anatomically; i. e., whether there is not always some connection when the fibers pass through a ganglion. Some influence must be assumed to exist for the above hypothesis. It would also appear to a clinician to exist.

If the cells of the nasal ganglion are as resistant as those of the semilunar ganglion, it explains how they may for some time resist in an inflamed environment; but when once attacked they may in the same manner resist treatment. So it might be explained that intractable Vidian neuralgia is not unrelated to the intractable vasomotor-secretory phenomena, inasmuch as they are often associated and are alike resistant to treatment. In this connection it should be recalled that the *vasomotor-secretory* phenomena of the nose may be excited from (1) the nerve-endings (2) the *neuralgia and sympathetic symptoms* from the nasal *ganglion*, or (3) the Vidian nerve *trunk* within the *floor* of the *sphenoidal sinus*. In the first instance the trunk injection of Otto J. Stein[3] succeeds; in the second instance the

Digitized by Illinois College of Optometry

ganglion injection may succeed, or need repeating; in the third instance the disorder must be attacked from within the sinus, when it may succeed in even the worst cases.

Buch made the observation that the sympathetic in health was not especially sensitive, but that it becomes very sensitive if the animal is worried or the nerve becomes congested. Buch accords with Ranson's[3] statement that the impulses which travel over these (sensory) fibers do not under ordinary circumstances give rise to sensations but expend themselves in visceral reflexes. These facts readily explain how these cases may relapse from fatigue, anxiety, apprehension, fright, anger, or slight systemic toxemias, inasmuch as the environment of the ganglion and nerve tissues may remain slightly inflamed for almost any length of time, and pass under the generic term "catarrh."

I have stated that I thought that the control of glaucoma pain from the nasal ganglion was a nerve blocking, and I believe that this is true with the control of the other eye pains mentioned above. The thought now arises that it is the involuntary fibers which run through the nasal ganglion to the Vidian, etc., that transmit the pain posteriorly in the painful eye troubles. (Hiram Byrd[3] does not agree with this idea. See Chapter VII.)

Therapeutically, it has seemed advantageous to stop the pain and photophobia of some of the eye diseases at the nasal ganglion, not for the comfort of the patient only, but also because some cases have been turned thereby in their course for immediate improvement of what had been a more or less stubborn condition (iritis, glaucoma, corneal ulcer, interstitial keratitis, conjunctivitis) (Sluder[21]), which may argue possibly a trophic influence. (See cases 68, 69, 70, 71, 72, 73.)

Cauterization of the membrane over the nasal ganglion (strong silver nitrate or acetic acid) has in some instances prolonged the helpful influence; and some were injected with phenol alcohol.

In one patient suffering severe photophobia with severe pain in the lower half of the head and neck (lower half headache) from a traumatic ulcer of the cornea, full cocainization of the ganglion stopped the photophobia and lower half headache completely, and left only the sense of irritation produced by the cinder upon its arrival on the cornea, which was slight. The

Digitized by Illinois College of Optometry

sense of first irritation remained, carried by the ophthalmic nerve, and the "deep and heavy pain" passed through the nasal ganglion and was stopped at that point.

W. M. C. Bryan has made a most interesting and instructive observation which bears upon the transmission pathway for this pain. He had a patient afflicted with a herpes of the ophthalmic and maxillary divisions of the trigeminus. The pain was intense, part of it being great pain in the eyeball aside from the pain in the distribution of those nerves. Cocainization of the nasal ganglion stopped the pain in the maxillary distribution and *in the eyeball.* Intrasphenoidal cocainization (lateral wall) stopped the pain in the ophthalmic nerve distribution but did not stop the pain in the eyeball. The ophthalmic nerve is often in contact with the lateral wall of the body of the sphenoid which is hollowed by the sphenoidal cell. Cocaine passes through the wall (see page 148). This case proves, as far as clinical proof is possible, that the great pain in the eyeball was associated with the pain of maxillary nerve distribution and not the pain of ophthalmic nerve distribution.

Close scrutiny is required to separate some of the eye disturbances which are referred from the ganglion, from some eye diseases proper.

In several pronounced cases of asthma which remained after the hay fever season, cocainization of the ganglion stopped the dyspnea and it did not return.

In four other cases secondary to post-ethmoidal-sphenoidal inflammation in mid-winter, of greater or lesser severity, cocainization of the ganglion of one side either stopped or greatly lessened the sibilant râles in the lung of that side, and relieved the sense of oppression on that side; and in one case of right-sided sphenoidal empyema, the râles and sense of oppression were on that side only, and were stopped by cocainization of the ganglion.

I believe now that it is irritation of the sympathetic fibers at the nasal ganglion that explains the dilatation of one pupil at the time of coryza, rather than blunting of the third nerve function, as I previously thought.

The argument outlined above seems to me applicable in the explanation of pain of cardiac origin (angina pectoris) be-

Digitized by Illinois College of Optometry

ing referred into the arm; i. e., originating in the heart, the impulse passes by the sympathetic upward to the lower cervical and first thoracic ganglia, and then to the spinal ganglia of some of the nerves of the brachial plexus.

Cocainization of the nasal ganglion in four cases of autumnal hay fever stopped the lacrimation and burning or itching eyes. The effect was permanent in one case, and lasted one to seven days in the others. (In these observations I had the assistance of H. E. Miller and C. A. Gundelach.)

Rhinorrhea and *sneezing* with *frequent coryzas,* with *asthma* and *fever,* but with little or *no headache* are seen in children, as concomitant of *post-ethmoidal-sphenoidal* inflammations and, I believe, are *another* phase of the picture described above.

It seems to me that, clinically, there are several types of coryzas, and among these I am disposed to class rose colds, hay fever and horse, etc., fevers produced, probably, by as many varieties of causative agents; and that their actions are selective, one or more being peculiar in that they attack the sympathetic nerve elements in the nose and, furthermore, the vasomotor secretory elements often totally independent of the pain-producing elements of the sympathetic. Sensitization is apparently the factor that determines the manifestations in the particular case.

We have frequently seen the coryza manifest by dryness without nasal obstruction, which suggests paralysis of secretion. Bacterial cultures made by clinicians, from the nose, at the present time, fail to differentiate these cases.

These differences may be explicable along the lines of sensitization (as these ideas now stand); i. e., that everyone is probably sensitized to or for some extraneous agent which is then for *him* pernicious.

As is well known, some individuals are sensitized to or for egg albumen, others for strawberry, others for apple, etc.: others for horse serum, others for the pollen of some grasses, others for golden-rod and ragweed. The last three classes are those who develop horse asthma and spring and fall hay fever.

J. L. Goodale's text in 1914 records his observations (with

Digitized by Illinois College of Optometry

case reports), which seem to me to promise a better understanding of the above-enumerated problems.

W. H. Haskin read a text to the American Laryngological, Rhinological and Otological Society, 1913, and showed a most exquisite dissection, in which attention was called (with demonstration) to the widespread anatomical connections of, and the recognized physiological phenomena connected with the involuntary nervous system.

In 1924 R. J. Payne made a most interesting report on the results of treatment of hay fever by alcohol injection of the nasal ganglion. He used 95 per cent alcohol and 5 per cent phenol. The technique of injection was the same as that described in this text. Forty-three patients were treated during the attack of hay fever. The results varied from an amelioration, such as to cause the patient to suffer but little discomfort, to complete relief. In three cases only was there complete failure to produce any relief whatsoever.

H. H. Martin has had success in the treatment of neuralgic cases by injection of the ganglion.

A most comprehensive review of the literature on the nasal ganglion syndrome has been made by Burger. He refers to recent publications of about thirty-five authors. Particular reference is made to the various classifications of the nasal ganglion syndromes and the numerous nerve connections with other ganglia. He also makes note of the various methods of treatment, especially the methods of injection of the nasal ganglion. Several interesting phenomena in connection with the nasal ganglion were mentioned. Halphen reported a case of herpes zoster of the ophthalmic nerve in which the pain was controlled by cocainization and alcohol injection of the ganglion. In Mink's experiments on the electrical stimulation of the ganglion symptoms of increased nasal discharge, increased local temperature, swelling of the mucous membrane and redness of the conjunctiva were noted. There was vasodilatation and no vasoconstriction.

For many years Otto J. Stein[1, 2] has employed alcohol injection for the treatment of hay fever and hyperesthetic rhinitis. He has devised his own technique which is a peripheral injection of the anterior ethmoidal nerve at its exit through the anterior

Digitized by Illinois College of Optometry

ethmoidal foramen and the branches of the sphenopalatine ganglion as they emerge from the sphenopalatine foramen. He uses a straight needle for the anterior injection and a slightly curved one for the posterior. He is well satisfied with the method and has been able to get good results. He has not made any reference to using this technique in cases of lower half headache and its variations.

I suggest for those interested in these phenomena a perusal of Langley's text on the sympathetic nervous system in Schafer's *Textbook of Physiology,* J. Parsons Schaeffer's *The Nose, Paranasal Sinuses, Nasolacrimal Passageways, and Olfactory Organ in Man,* C. Judson Herrick's[1] *Introduction to Neurology* and L. R. Müller's *Die Lebensnerven,* second edition. These volumes give bibliographies that will conduct further inquiry to occupy your leisure.

Reverchon and Worms reported an interesting case of atrophic rhinitis of ozena type following a fracture of the zygomatic region with projection of bony particles into the depth of the pterygomaxillary fossa. In my experience nothing of this sort has occurred in the course of many hundreds of injections of the nasal ganglion for therapeutic purposes.

DIAGNOSIS

The diagnosis of nasal ganglion neuralgia has called into consideration phenomena that heretofore have been inexplicable, an understanding of which I think I now have.

The above-mentioned syndrome may be produced by lesions of the nerve trunks which supply the ganglion, namely, the maxillary and the Vidian nerves. It is supplied with sensory fibers by the maxillary. The Vidian is composed of the great superficial and the great deep petrosals. The great superficial petrosal comes from the geniculate ganglion, bearing motor fibers, sensory and autonomic, from the seventh, and taste fibers which have arisen in the anterior two-thirds of the tongue and are to reach the brain by the fifth nerve; it also carries bulbar autonomic fibers; the great deep petrosal is a sympathetic nerve branch of the carotid plexus. Both the maxillary and the Vidian trunks (Figs. 90 and 93) frequently lie in very close association with the sphenoidal sinus. They may be separated

Digitized by Illinois College of Optometry

from the cavity in the body of the sphenoid by only an egg-shell thickness of bone; and this may be a fact as early as the third year of life for the second division of the fifth, and the seventh year for the Vidian. Each year of life presents the same possibilities, from childhood to maturity. I learned this from an inspection of the matchless material, property of Warren B. Davis, Keen Research Fellow of the Jefferson Medical College, Philadelphia, and published[17] it with his consent. This material consists of 145 sections of the Caucasian head from two months fetal life to maturity (twenty-five years) uninterrupted, several specimens for each year (except the eleventh—only one) showing the changes of each year. Therefore, when inflammation exists in the cavity which occupies the body of the sphenoid (the sphenoidal sinus or a post-ethmoidal cell) it may readily involve the associated nerve trunks, either by its extension, or by its toxin passing through the thin separating bony wall. In 1912 I[27] found in some patients that cocaine readily passed through this wall and paralyzed one or sometimes all the branches of the fifth nerve. A lesion involving the nerve trunks central to the point of union of these trunks can reproduce or simulate the syndrome arising from a lesion of such a point of union (nasal ganglion). There exist, however, at this point of union, ganglion cells. It is not a mere coalition of fibers. What part clinically, these multipolar cells may play, is as yet unknown; but the clinical fact remains that certain sphenoidal inflammatory cases simulate completely the typical neuralgic and sympathetic phenomena arising in the nasal ganglion.

In consideration of the diagnosis of the affections of the sphenoidal sinus and the nasal ganglion, there are certain other lesions giving rise to similar symptoms, which should be considered in the differential diagnosis. Loyal E. Davis reports a small group of three cases which he classifies as lesions of the paratrigeminal area. (See Fig. 59.) In the first case there was a paralysis of the right sympathetic with contraction of the pupil, and pain over the area of distribution of the ophthalmic and maxillary divisions of the fifth nerve. Cocainization of the nasal ganglion had no effect. Peripheral injection of the nerves gave no relief of pain. There was no dilatation of

Digitized by Illinois College of Optometry

the pupil from cocaine and the ciliospinal reflex was absent. In the second case the patient had pain in all the divisions of the fifth nerve, paralysis of the oculomotor nerve and dilatation of the pupil. At autopsy an aneurism of the carotid was found pressing upon these nerves. In the third case there was pain in the left eye and over the branches of the fifth nerve, contraction of the pupil, slight impairment of the ocular movements and paresis of the masseter and pterygoid muscles. Autopsy revealed an endothelioma between the Gasserman ganglion and the hypophysis.

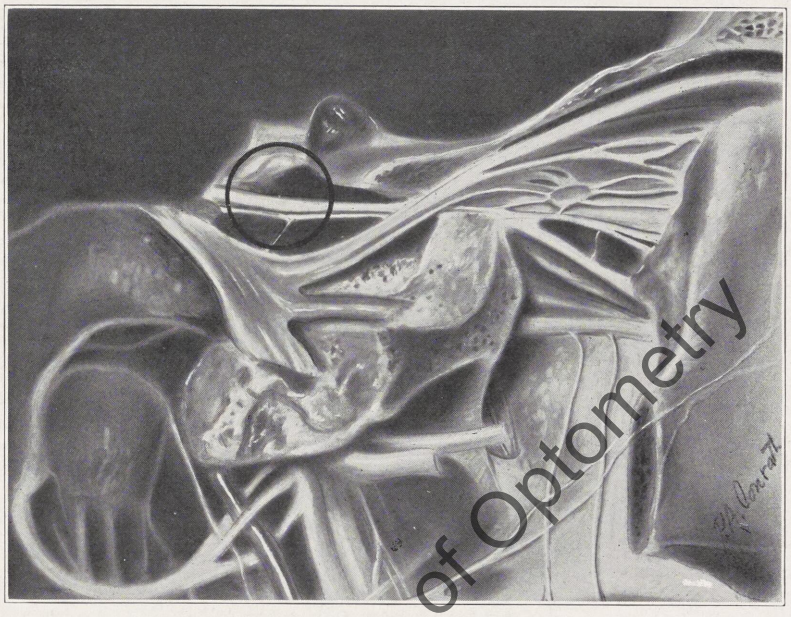

Fig. 59.—Anatomic model showing Gasserian ganglion, internal carotid artery, carotid sympathetic plexus and related structures. The circle encloses the paratrigeminal area. (Redrawn from Loyal E. Davis, Jour. Am. Med. Assn., February 10, 1923.)

In this connection the report of Shelden on tumors involving the Gasserian ganglion is also worthy of consideration. The chief symptom in these cases is pain over the area of distribution of the fifth nerve. While the pain is quite severe it is not similar to that of tic douloureux because it is more constant and not excited by eating, talking, etc. In addition to pain there are changes in the touch, temperature and pain sensibility. Shelden also calls attention to the fact that tumors

Digitized by Illinois College of Optometry

of the Gasserian ganglion may be stimulated by malignant tumors of the nasopharynx. In the latter instance the tumor may involve either the peripheral branches of the fifth nerve or extend into the cranial cavity and involve the Gasserian ganglion.

There is also another pain syndrome which is indeed worthy of mention and that is glossopharyngeal neuralgia. In 1923 J. B. Doyle described four cases of neuralgia of this type. The pain area is confined to the lateral wall of the pharynx posterior to the tonsillar region. From this region it radiates to the ear, mostly in the tragus and area anterior to it. Sometimes the pain is referred to the region posterior to the angle of the jaw. In all of its characteristics the pain is the same type as that occurring in trifacial neuralgia, differing only in the area of distribution. It is excited by eating, talking, etc., is paroxysmal and of short duration. A definite trigger area in the lateral and posterior wall of the pharynx is usually present.

In one of Doyle's cases of glossopharyngeal neuralgia an operation had been previously done on the Gasserian ganglion for the relief of pain. In this patient he was able to outline the area of distribution of anesthesia to touch, temperature and pain over the branches of the fifth nerve supplying the nose, palate, mouth and tongue. Later an operation was performed on the glossopharyngeal nerve and the same tests were applied to the area of distribution of this nerve, over the soft palate, tonsil and pharynx. From this investigation he was able to demonstrate that the afferent fibers of the nasal ganglion concerned with the innervation of the nasopharynx are not derived from the trigeminal nerve. This is a rather convincing argument that the sensory supply of the nasopharynx is derived from the facial nerve through the nasal ganglion. I have seen only one case of glossopharyngeal neuralgia. This one, however, was easily recognized and typical in every respect.

Obviously there is always some difficulty in deciding between posterior pain of the lower half headache and the pain of cervical osteoarthritis. An x-ray picture may be of help at this time, but it is not always so.

The differential diagnosis may be made by the following facts:

Digitized by Illinois College of Optometry

1. Cocainization of the nasal ganglion stops the pain of a lesion in the ganglion proper.

2. Cocainization of the nasal ganglion does not in any degree stop the pain created by the more central lesion of the nerve trunks, maxillary and Vidian, secondary to sphenoidal inflammation. These points had, as a rule, better be proved on several occasions before injection is done. *I believe these points have been overlooked or neglected by some surgeons who have complained that their results were not as good as mine.*

3. On the other hand, intrasphenoidal application of pain-reducing remedies, such as cocaine, will under these conditions stop the pain—that is, a local anesthesthetic applied central to the ganglion is effective.

In addition to these points of difference, there is usually a congestion and thickening (hyperplastic post-ethmoiditis) at the site of the sphenopalatine foramen when the nasal ganglion is the starting point for the neuralgia. There is also a small number of cases that are always controllable by cocaine applied to the nasal ganglion or intrasphenoidal cocainization that I have not been able to "cure" by anything known at present.

PROGNOSIS

The prognosis of nasal ganglion neuralgia is beset by several perplexities on which I have speculated. Frequently in severe cases that had been relieved by injection of alcohol, the benefit proved so transitory as to arouse the inquiry: Was it worth while? In contrast with these, however, are others of high grade which were easily cured by simple applications of cocaine, mercurochrome, or silver to the inflamed sphenopalatine foramen district, or by one injection. Possibly all such variations could be satisfactorily explained where post-mortem material is frequently available in these cases as is the diseased lung, liver or heart. Possibly an exact knowledge of the anatomy of the ganglion in man (which is not known) would be helpful also. Müller and Dahl have made observations that are most enlightening and possibly final. Their findings are very difficult to explain at present. I feel, however, that I have a better understanding of some of these points now from further clinical

Digitized by Illinois College of Optometry

experience and a knowledge of work on collateral lines by May, of London, although animal experiment, or post-mortem observation of my own is still wanting. The best treatises on anatomy give only a few words of description to its histology. The gray matter of the ganglion does not involve all of the sphenopalatine branches of the maxillary nerve, but is placed at the back part at the point of juncture of the Vidian nerve, so that many if not all of the fibers of the sphenopalatine nerves proceeding to the nose and palate pass to their destination without being incorporated with the ganglion mass.

The fact that herpes has never been seen as a part of this syndrome would seem to bear out this point, for herpes is never produced by lesions of the sensory nerve trunks; but only by lesions of the sensory cells. The ganglion cells, therefore, would seem to be a part of its sympathetic and autonomic attributes, which are constituted by the Vidian nerve. It seems true from clinical experience, however, that the Vidian nerve carries fibers which transmit the sense of pain also. Certain noses have been propitious for cocainization of the tissues internal to the assumed position of the ganglion with the effect of stopping entirely the pain of posterior distribution; and then, when the applicator was placed external to the assumed position of the ganglion the pain of anterior maxillary distribution stopped. When placed in the center, it would stop both anterior and posterior pains. In other words, it would seem that the trunks of the nerves supplying the ganglion in these cases could be cocainized separately. This has seemed true also for injection and electrical (faradic) stimulation. Alcohol injected on the Vidian side of the ganglion has produced great pain of posterior distribution; injected on the maxillary side it caused the anterior pain. The needle in these positions was attached to the faradic current, the other pole in the hand, with the same results. This was true for some cases, but the production of the posterior pain failed in some others.

The work of Dr. Otto May seems to me to explain some of the transitory results of injection. He proved experimentally that the cells of the Gasserian ganglion in the goat, cat and dog are not at all readily destroyed by alcohol; that they are quite resistant to its action even though the gan-

Digitized by Illinois College of Optometry

glion was surgically exposed and the injection put directly into its substance. He also proved that the nerve fibers are much more vulnerable to alcohol than the cells; but that the injection must be made exactly into the nerve trunk. When the alcohol was put merely around the nerve, its effect, although marked, was transitory—the nerve quickly recovered its function. Lannois and Berial have proved that the anatomical effect of the clinical injection of alcohol into the nerve trunks is very slight. G. M. Dorrance states that experiments on dogs showed destruction of cells (Gasserian ganglion) wherever the alcohol reached. (Conclusions from laboratory experiments sometimes differ.)

So it would seem that inasmuch as the ganglion is small (5 mm.) and difficult of access, we may assume that the transitory results have followed the instillation of alcohol into its environment rather than into its substance; and that the highly satisfactory results have followed the exact instillation of the alcohol into its midst, or into the trunks supplying it; and that the results may not be permanent even under these circumstances, because these tissues are so difficult of destruction. (Whatever caused the pain in the original cell, one may suppose, may cause it in the regenerated cell.) The clinical value of the injection, however, must be admitted. And, on the other hand, the severe cases from which the patients have recovered so satisfactorily from surface applications to the membrane covering the sphenopalatine foramen and its immediate surrounding (whereby an inflammation was allayed), we may assume to have been produced by irritants to the cells and fibers without their actual structural involvement, their power of resistance being great, as shown by Dr. May. In this I am assuming these cells and fibers to be alike with those observed by Dr. May. These assumptions may likewise explain why the complete clinical picture has so seldom been observed in a single case. The complete picture would require the complete involvement of all the cells and fibers of the ganglion alike, which in accordance with the above assumption would not be apt to happen.

The nasal ganglion neuralgia that recurs at long intervals secondary to a suppurative post-ethmoiditis I believe is ex-

Digitized by Illinois College of Optometry

plained by the fact that a pad of about 0.5 cm. lies between the post-ethmoidal or upper anterior wall of the sphenomaxillary fossa and the nasal ganglion. The establishment of the pain at long intervals (3 to 12 months) has been, almost uniformly, by a coryza recognizable in this district. I interpret this as a condition which gives freedom from pain in times when there is no acute inflammation, by virtue of the thick pad which separates the ganglion from the inflamed cells. At the time of an acute inflammation in the cells enough toxins are made to spread through the pad and affect the ganglion. I have seen this form a number of times cause the picture of a *complete ophthalmic migraine,* recurrent at 3 to 18 months' intervals.

A nasal ganglion neuralgia that arises secondary to a hyperplastic post-ethmoidal sphenoiditis, without pus, is very much more apt to recur at much shorter intervals; indeed it may be present more or less constantly. There is no separating pad between the anterior face of the sphenoid and the ganglion. Only a small amount of connective tissue is present here. The inflammatory process or its toxins have only a small separation to traverse to reach the ganglion.

Focal infection may play a part in lower half headache, just as acute indigestion may sometimes produce it. This corresponds with cases of sphenoidal headache and eye lesions that recover after tonsillectomy. I have seen what seemed to be sphenoidal headache in young patients recover after that procedure. I have, however, seen it fail in the majority of such cases. I have never had the fortune to see eye lesions cured by tonsillectomy, but I do not challenge the correctness of this statement made from time to time in various journals. That infected teeth may cause eye lesions is well known. My friend, Geo. E. Shambaugh, is disposed to emphasize the rôle of focal infection in lower half headache. I once saw a case that appeared to be a marked subacute post-ethmoidal-sphenoidal inflammation that seemed to be the cause of the headache. Later, the patient told me that an infected tooth had been found and removed with the cure of the headache. Eight years later the patient told me that relief was transitory. He still had headache. Three years ago I sent a patient with what I took to be a sphenoiditis with much headache to one of my colleagues in

Digitized by Illinois College of Optometry

a distant city. He removed a bit of lymphoid tissue ⅓ cm. in diameter from the tonsillar fossa. It had been left in, after the operation of tonsillectomy which was performed some years before, or it had reformed later. In a letter he told me that she was cured by this. Two years ago the patient said that she was better for a little while but was then "as bad as ever." Last year someone opened her sphenoid, with relief for one year. These points serve merely to emphasize the necessity of discrimination in the treatment of these cases just as is necessary in all other lines of practice.

TREATMENT

In the treatment of these cases various remedies and several surgical means have been employed. Applications were made to the region of the sphenopalatine foramen of 2 per cent solution of silver nitrate, 0.4 per cent solution gaseous formaldehyde, 0.5 per cent phenol with 0.1 per cent iodine as a wash. (One per cent mercurochrome serves better than formaldehyde.) In the more severe and stubborn cases injections of phenol alcohol were used and in the worst, the patients were operated upon (intranasally) with the intention of removing the ganglion. But treatment has heretofore had only passing mention. I feel that it should be taken up here in detail.

Anatomical Considerations

The treatment of these neuralgias has always been beset by difficulties which are occasioned by the anatomy of these parts. The simple painting of the region of the sphenopalatine foramen will often be found difficult because of an irregularity on the septum, or the configuration of the lower turbinate, or both. Certainly, in a nose which presents a straight septum, a wide caliber nasal fossa, and a straight lower turbinate there can be no difficulty in reaching accurately the region of the sphenopalatine foramen. In such a nose, a needle bent at a right angle 0.5 or 0.66 cm. from its end may be introduced along the septum, to a point 0.33 cm. posterior to and slightly above the posterior tip of the middle turbinate; and may then be turned to point outward which would bring its point to the

Digitized by Illinois College of Optometry

membrane covering the sphenopalatine foramen. This could readily be punctured, thereby bringing the needle's point directly into the sphenomaxillary fossa at the site of the nasal ganglion.

This would seemingly be the simplest and best method of injecting medicaments into the ganglion. But even were this

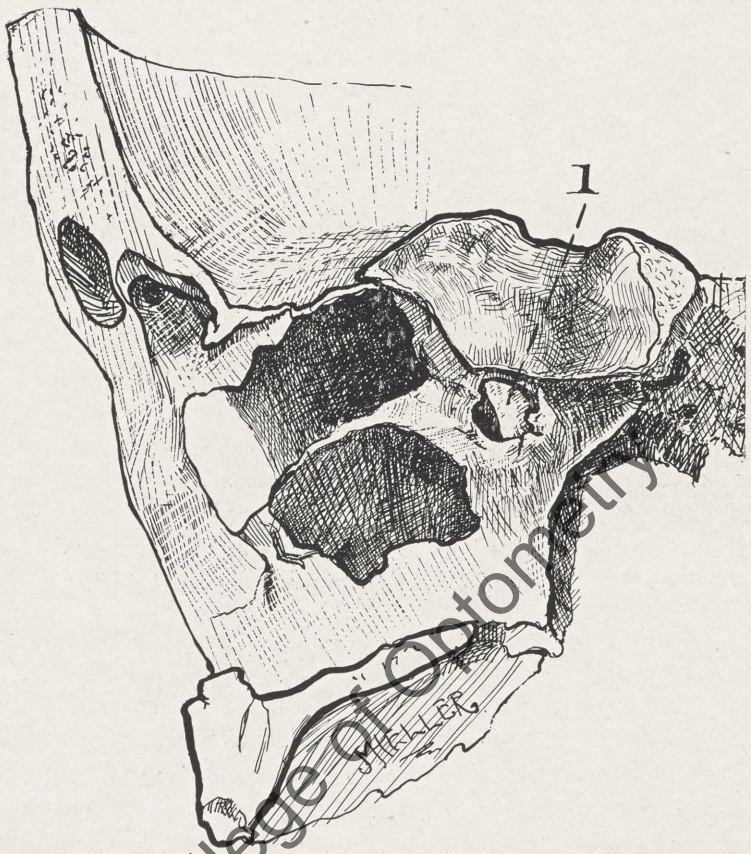

Fig. 60.—Showing pterygoid process *1* projecting forward beyond the posterior limit of sphenopalatine foramen.

always a possible technique, it would still fail at times because the sphenopalatine foramen is sometimes placed posterior to the anterior surface of the pterygoid process (Fig. 60) opening as it were into the Vidian canal rather than the sphenomaxillary fossa. (Compare Fig. 61.) Such a pterygoid process is V-shaped, apex forward. Injection under these conditions would

Digitized by Illinois College of Optometry

be into the Vidian nerve and not into the ganglion. It is for these reasons that I call attention to the method of injection by means of the straight needle, which may be done in practically all noses, however irregular or narrow, and, under control, is almost infallible in its accuracy. The control consists in measurement of how far back of the posterior tip of the middle turbinate the ganglion lies, irrelevant to the

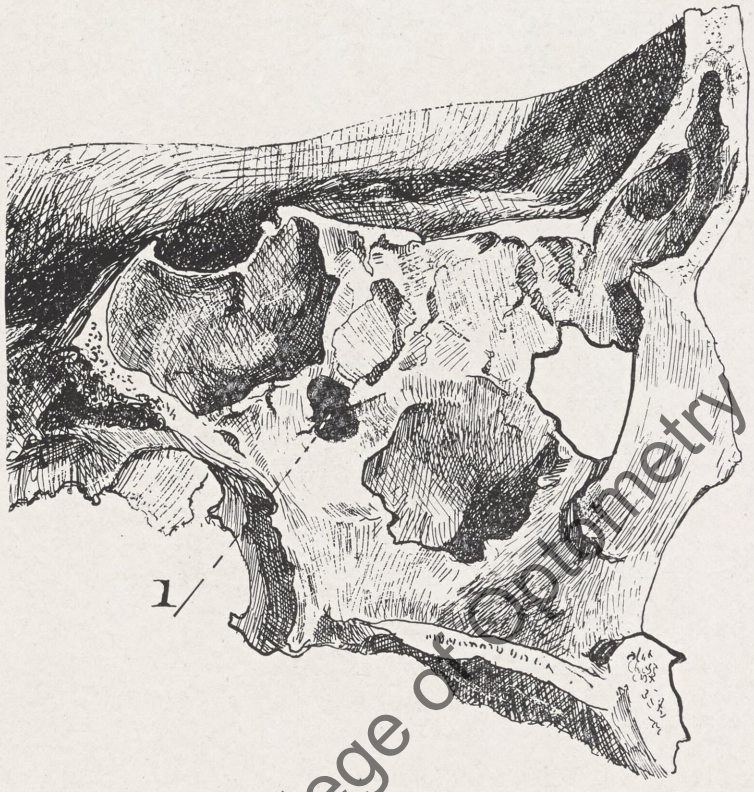

Fig. 61.—Showing usual sphenopalatine foramen *(1)*. The pterygoid process is behind it.

pterygoid process. The sphenomaxillary fossa is constantly reached about at its center, 0.33 cm. back of the posterior tip of middle turbinate; and it is this fact that I utilize in the therapeutic injection. Should the surgeon rely on the buttress of a solid pterygoid process to stop his needle when it is being pushed backward, as might seem perfectly feasible under the rule of the anatomy of the pterygoid process, he will find

Digitized by Illinois College of Optometry

himself disappointed frequently because the pterygoid process is hollowed out by a prolongation of the sphenoidal sinus downward into it as far as the bifurcation of the plates. The needle then crosses the sphenomaxillary fossa and penetrates a thin film of bone to enter the sphenoidal sinus to meet with firm resistance only in the posterior wall of the sinus, or possibly not even there. It might readily enter the cranial cavity. The injection will then be into the sphenoidal sinus or cranial cavity. Then too, the sphenoidal sinus is sometimes set so far down in the body of the sphenoid that its lower aspect lies

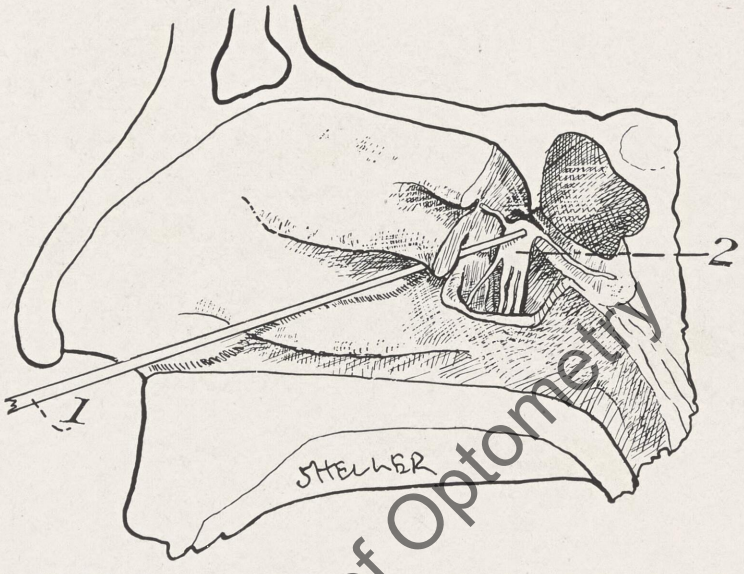

Fig. 62.—Showing correct placing of the needle *(1)*. *(2)*, Nasal ganglion. (After Loeb.)

below the line of the needle thrust. (Fig. 64.) Under these settings the needle enters the main cavity of the sphenoid as soon as it crosses the sphenomaxillary fossa.

The relation of the sphenopalatine foramen to the posterior tip of the middle turbinate is one of the most *constant* in the nose. Once I found the sphenopalatine foramen just posterior to the upper turbinate (Fig. 58). This must be exceedingly rare. Even though the anterior aspect of the pterygoid process be V-shaped and be relatively forward of the sphenopalatine foramen it disturbs this relation little or none.

Digitized by Illinois College of Optometry

The posterior tip of the middle turbinate always marks the anterior limit of the sphenopalatine foramen. The sphenomaxillary fossa must, of course, needs lie lateral to the plane of the sphenopalatine foramen. These relations being borne in mind, it must appear that a straight needle introduced into the nose from the nostril to pass under the posterior tip of the middle turbinate at its origin from the lateral wall, in a direction backward and upward and slightly outward, must pass out of the nasal fossa into the sphenomaxillary fossa and

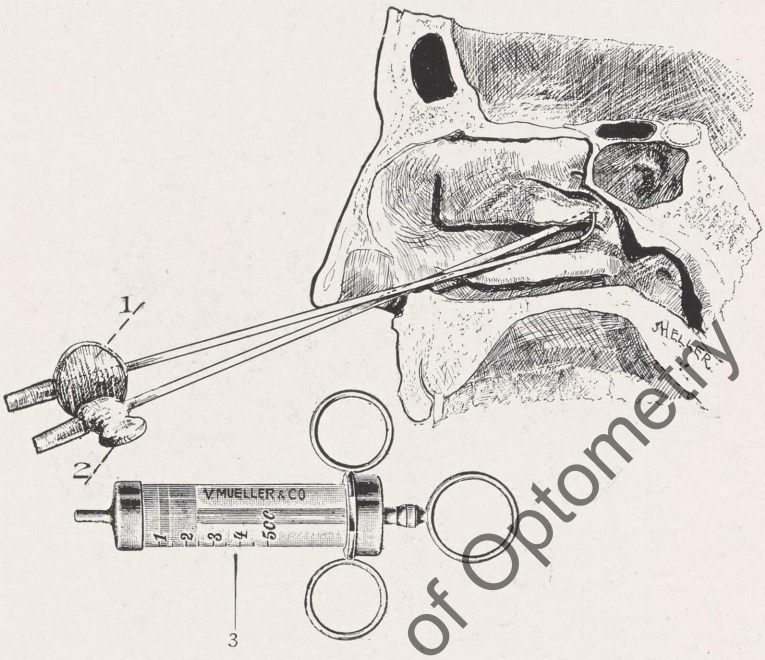

Fig. 63.—Showing both straight and curved needles* *(1-2)* correctly placed. *3.* A satisfactory Record syringe.

enter the nasal ganglion or its immediate vicinity. The distance from the point of entrance of the needle so placed and ganglion tissue is almost invariably 0.66 cm.

The lateral wall of the nose plays an important part in this technique and its variations should be borne in mind, to wit:

1. In the middle meatus the lateral wall sometimes extends abruptly outward and slightly forward, from the posterior tip

*May be purchased from V. Mueller and Company, Chicago, Ill.

Digitized by Illinois College of Optometry

of the middle turbinate, even to such a degree that it forms the anterior limit of the sphenomaxillary fossa, excluding the posterior wall of the maxillary sinus from participation in these boundaries. When this is true, a very careful estimate must be made of the origin of the middle turbinate at its posterior tip, because such a pouching outward (concavity) of the lateral wall permits the tip of the needle to be placed as far outward (lateral) as the line of the foramen rotundum. Pushed back-

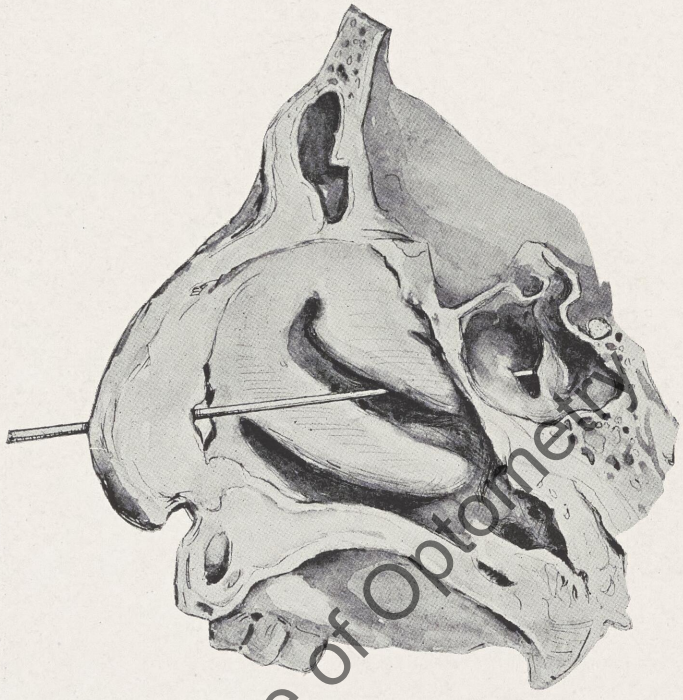

Fig. 64.—Showing nasal ganglion needle having passed across the sphenomaxillary fossa and then through the thin wall of a low set sphenoidal sinus. (In this picture the needle is shown at a point slightly forward of the correct point for the injection of the ganglion in order to exaggerate the error.)

ward under these circumstances, the needle would reach a point lateral to the ganglion. Such a wall is, however, not difficult to estimate and is readily punctured, usually because the needle approaches it at almost a right angle.

2. The lateral wall in the middle meatus is sometimes straight and smooth and of very hard bone. The point of the needle placed under the tip of the turbinate attached to such

Digitized by Illinois College of Optometry

a wall may often be pushed backward without penetrating the wall. The tip of the turbinate will be punctured and the point of the needle pass submucous backward and upward to slip into the opening of the sphenopalatine foramen and if carried farther backward will enter the Vidian canal, which is on a line internal to the ganglion. This wall may indeed be so straight, hard and smooth as to defy all attempts to pierce it

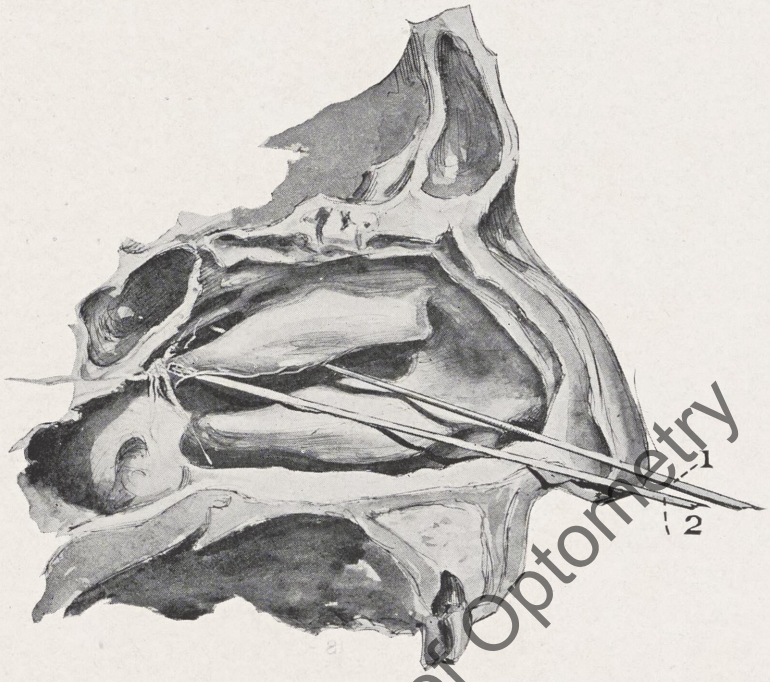

Fig. 65.—*1*, Showing needle transfixing the middle turbinate. It has been placed too far forward. The needle *2* shows the correct placing.

with a straight needle introduced from the nostril. The curved needle passed around the posterior tip of the middle turbinate through the sphenopalatine foramen is better in these cases.

3. Very rarely is the lateral wall convex.

4. The lateral wall in the upper meatus of the nose is usually on a plane internal to that of the middle meatus; but not always. It sometimes dips sharply outward, leaving the middle turbinate a very prominently marked thin film of the bone; posteriorly, however, it proceeds inward finally to come to be on the same plane as the middle meatus, one meatus above

Digitized by Illinois College of Optometry

and the other below the crista ethmoidalis as it ends on the anterior semicircle of the sphenopalatine foramen. (Compare with Fig. 65.)

This foramen is constantly immediately posterior to, with its center slightly above, the posterior limit of the origin of the middle turbinate from the crista ethmoidalis (Figs. 57 and 61). The crista ethmoidalis of the perpendicular plate of the palate bone almost always extends slightly into the sphenopalatine foramen, subdividing its anterior semicircle into an upper two-thirds or three-fourths and a lower third or fourth. There is usually a like marking on the posterior semicircle. In forty-seven heads this rule was broken once when the entire sphenopalatine foramen was placed 2 mm. above the crista. The diameter of the sphenopalatine foramen varies; but this seems to make little or no difference in this technique. The internal maxillary artery is in the sphenomaxillary fossa.

Four times I have had hemorrhage at the time of injection and once three days after. Three times it followed the use of the straight needle and was readily controlled by a gauze tampon pressed under the posterior tip of the middle turbinate at the place the needle entered. Once it followed the use of the curved needle and was a little more difficult to control. It did not require a posterior pack. Recently in the service of the nose and throat department of Washington University Medical School a hemorrhage followed ligation of the common carotid artery. This is the only dangerous hemorrhage known to me that has followed this technique. This possibility should be remembered.

Instrumentarium

For the injection of the nasal ganglion I use a simple straight steel needle 1 mm. in diameter. This is of considerable strength; and fastened in a heavy crossbar enables the surgeon to secure it in a strong grasp and put great pressure on it. My former associates, Drs. A. C. Gundelach, H. E. Miller, and W. E. Sauer, have suggested (and employed) a needle with a trocar and flange or ring from 0.5 to 0.66 cm. from its point to prevent too deep placement or insertion. Familiarity with this technique I believe will render the flange unnecessary. I al-

Digitized by Illinois College of Optometry

ways have at hand a curved tip needle also, because sometimes the lateral wall of the nose is so hard that it cannot be punctured by the straight needle. The curved tip enables one to curl around the tip of the turbinate and enter the fossa through the sphenopalatine foramen. It seems to me a less satisfactory means of approaching the ganglion than the straight needle.

Technique

The ganglion is cocainized by an applicator carrying one drop saturated (90%) watery solution cocaine hydrochlorate placed under the tip of the middle turbinate for five minutes. It is then moved to lie over the sphenopalatine foramen just posterior to the posterior tip of the middle turbinate and allowed to remain there five minutes. The combined application under and posterior to the tip of the middle turbinate is ten minutes, one applicator carrying the one drop being moved from one place to the other. Injection under insufficient anesthesia is very painful. Nitrous oxide may be used in addition to cocaine.

From the preceding description it is evident that a straight needle introduced through the nostril in a direction backward, upward and slightly outward, approaching the lateral wall of the nose at a point in the middle meatus marked by the origin of the posterior tip of the bony middle turbinate, arrives almost at once on the anterior wall of the sphenomaxillary fossa. Should its point now be pushed backward 0.66 cm. it will usually enter the sphenopalatine ganglion or its immediate vicinity (Fig. 62). Experiment on the cadaver has proved, however that it is better to enter the point of the needle 2 mm. anterior to the posterior tip of the middle turbinate. Pushed backward from this point it proceeds in a direction slightly more upward and more outward than it would from the point farther back, and thereby it strikes more accurately the region of the ganglion.

It may appear that the correct placing and insertion of the needle is a bit of technique of easy and certain execution. It has not, however, proved so in my hands. A number of specimens operated on show the possible failures: (1) The Vidian

Digitized by Illinois College of Optometry

canal may be injected because the lateral wall of the nose is very hard and smooth. The tip of the needle will not penetrate it, but slides over it to the outlet of the Vidian canal. When it is pushed backward it passes under the tip of the middle turbinate and crosses the sphenopalatine foramen to enter the anterior outlet of the Vidian canal. A perfect application to the Vidian nerve may then be made. (2) The wall of the middle meatus may dip abruptly outward from the sphenopalatine foramen before it begins to extend forward; and the wall of the upper *meatus* may be of similar curvature. In such a

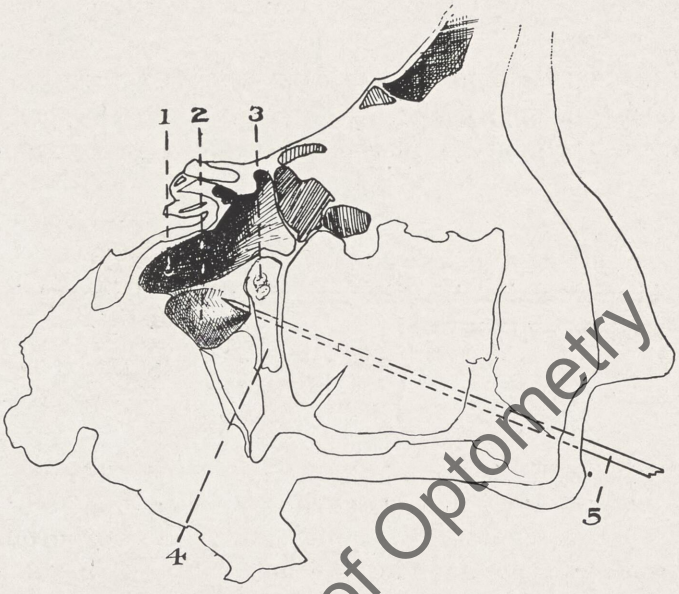

Fig. 66.—Showing needle (point) having passed across the sphenomaxillary fossa *4* to be free in a prolongation of the sphenoidal sinus *2* prolonged downward into the pterygoid process. *1*. The general cavity of the sphenoid. *3*. The nasal ganglion. *5*. The needle. This drawing is from a sagittal section just lateral to the Vidian canal seen from without.

nose, the needle may of course be placed correctly and arrive at the proper point in the sphenopalatine ganglion. If, however, it is placed a little too far behind and below, it will, when pushed backward, pass under the tip of the turbinate and cross the sphenopalatine foramen, as stated above, to enter the Vidian canal. And should it be placed slightly too far forward it will readily transfix the thin film of bone representing the middle turbinate. Its point, when pushed 0.66 cm. backward, will lie

Digitized by Illinois College of Optometry

free in the upper meatus (Fig. 65). Injection in the first instance will be into the Vidian nerve and in the second instance into the free upper meatus. In the latter circumstance, the injected solution will flow immediately backward and downward into the pharynx, assuming the operation to be performed in the erect posture. (3) A needle carried too far back may cross the sphenomaxillary fossa to enter the cavity of the sphenoid (Case 16), which may be set rather low in the body of the sphenoid bone (Fig. 64). (4) A needle pushed too far back may cross the sphenomaxillary fossa to enter a prolongation of the sphenoidal sinus downward into the pterygoid process (Fig. 66).

The lower turbinate frequently interferes with an easy and accurate placing of the needle point. This happens readily when the turbinate is placed somewhat higher rather than

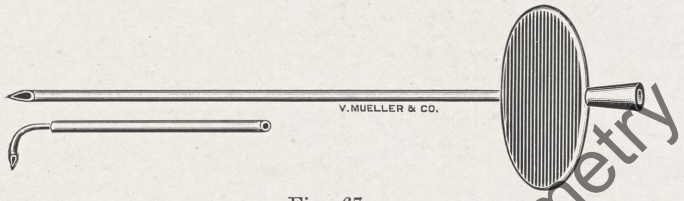

Fig. 67.

lower on the lateral wall. Under such conditions, the tip of the nose must be raised well up before a straight line may pass over the upper convexity of the body of the lower turbinate to reach the desired point under the posterior tip of the middle turbinate; and sometimes even then, considerable downward pressure will have to be exerted on the lower turbinate by the needle as it passes backward, in order to permit it to reach its destination.

Irregularities on the septum may interfere with the passing of the needle backward. They are apt, however, to be individual for that particular nose. The tubercle of the septum lies above the line sought by the needle.

I prefer the simple straight needle (Fig. 67) to be inserted under slight or great pressure, as the case may be. Under slight pressure it is very easy to measure 0.66 cm. distance insertion; but when it requires great pressure, it is by no means

Digitized by Illinois College of Optometry

easy to estimate this distance. For this reason I prefer to withdraw the needle when I think I have gone the right depth. While the needle is out of the nose, I examine it to see that it has not been plugged with bone—that it is open—and reinsert it into the opening from which it has been withdrawn. On reinsertion the correct distance may be measured exactly, because it requires no strength or pressure to replace it. One-half c.c. 5 per cent phenol in 95 per cent alcohol is then injected. The addition of methylene blue to saturation is an advantageous addition to the solution. Should the placing of the needle be anywhere that permits the solution to escape into the nasal fossa it shows at once as intense blue in the throat. A second solution of saturated fuchsin may then be used which will show red in the already blue stained throat in case the second placing of the needle should also be imperfect. The urine may be colored by these dyes.

It is my practice to rest the hypothenar eminence of my hand on the patient's chin, placing the other arm around the patient's head as soon as the point is in position. In this way strong and controlled pressure may be put on the needle. It is desirable that it should not jump across the sphenomaxillary fossa, but proceed backward cautiously. Should the wall be hard and straight and not possible of penetration by pressure thus applied, the needle may be taken firmly by the crossbar mentioned above, and thereby rotated to and fro through a semicircle from side to side, using it as a hand drill to penetrate the bone. The lateral wall may possibly be too hard to be penetrated this way. Should the bone be too hard to penetrate by a straight needle, a curved-tip needle may be employed curving from below upward and outward just back of the posterior tip of the middle turbinate. (Fig. 63.) It is usually not difficult to pass the needle through the sphenopalatine foramen in this way. E. M. Holmes[2] uses his nasopharyngoscope to direct the placing of the curved needle. A machine drill or burr may be employed (see above) to remove the lateral wall for access to the ganglion. It is not, however, to be recommended as it may injure the large arteries found here.

As mentioned above, I (1908[40]) advocated the injection of the nasal ganglion with a straight needle under the posterior

Digitized by Illinois College of Optometry

tip of the middle turbinate. At that time I realized that the posterior palatine canal was another approach to the ganglion, but I did not consider it as good as the nasal approach. It seemed to me that it was more likely to strike lateral to the ganglion. Later, the posterior palatine canal method was advocated by my friend, Dr. Simon L. Ruskin,[2] and was welcomed

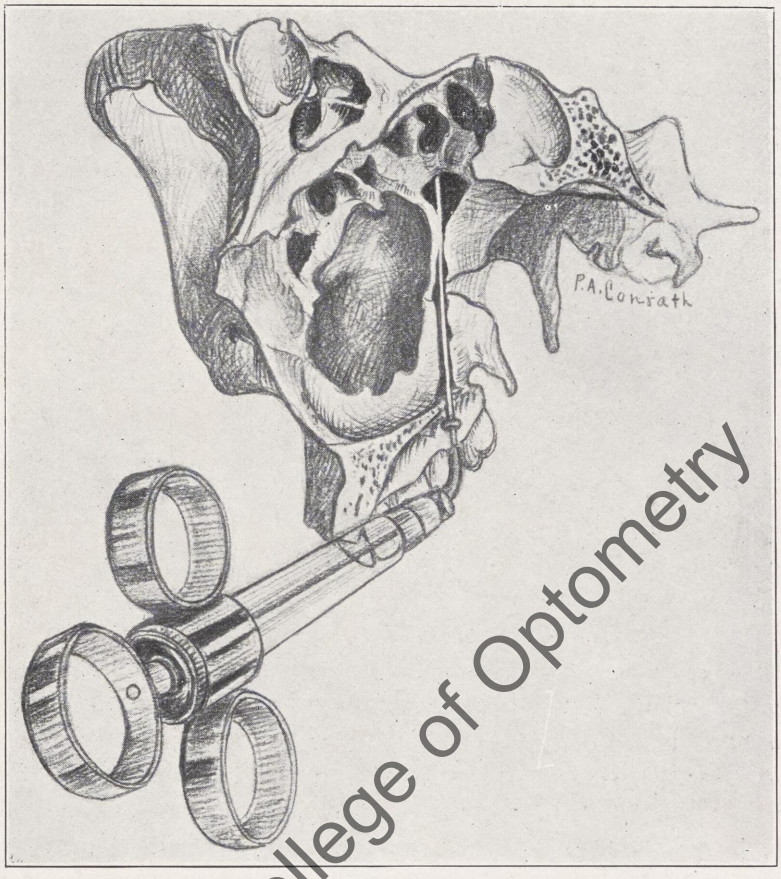

Fig. 68.—Showing a specimen in which the needle has passed through the posterior palatine canal to arrive automatically on the face of the sphenoid where the nasal ganglion lies. In this specimen there could not be an accident—the needle could not go any other place.

by many rhinologists who thought it was simpler than the nasal approach and more easily performed. I, too, admitted the simplicity of the approach and at once began to try it. I very soon found, however, that the needle, which was supposed to stop

Digitized by Illinois College of Optometry

automatically on the face of the sphenoid (Fig. 68) and thereby strike automatically into the ganglion, did not always do so. The needle passed upward and did not stop at the buttress of

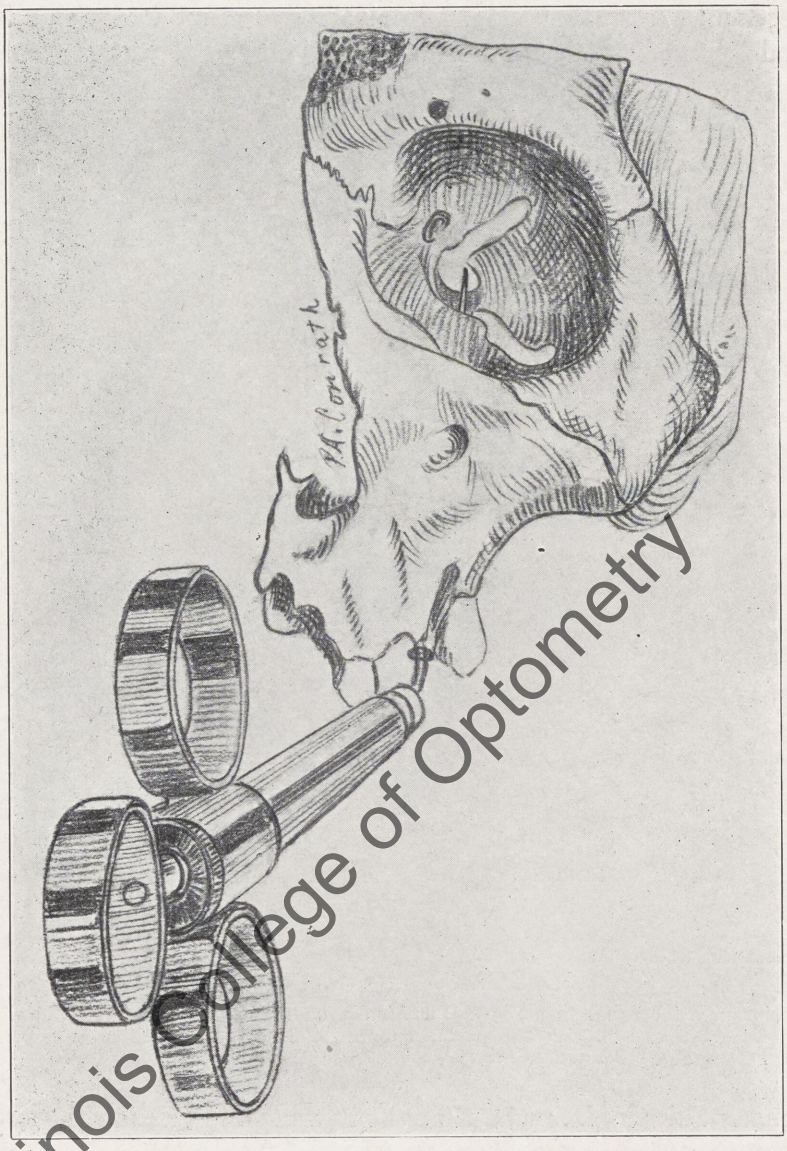

Fig. 69.—Specimen showing needle having passed through the posterior palatine canal and deflected slightly outward. It has passed through the inferior orbital fissure upwards into the superior orbital fissure where the point is seen. Front view.

Digitized by Illinois College of Optometry

bone. I realized that I had passed beyond the level of the ganglion and I withdrew the needle without injecting any fluid. A little later I tried it on the skull that I show you here (Fig. 69) to see where the needle went under such circumstances. It is obvious at once that if the needle passes slightly lateral, it enters the orbit through the infraorbital fissure and readily passes into the supraorbital fissure where it meets the third, fourth, fifth and sixth nerves and ophthalmic vein, which at this point is the beginning of the cavernous sinus, and is in very close proximity to the optic canal where it meets the optic nerve. If the posterior palatine canal is right for the injection, the needle very readily reaches the face of the sphenoid. If, however, the canal curves slightly outward, the needle is directed into the infraorbital fissure and into the orbit and it does not reach the face of the sphenoid at a point corresponding to the nasal ganglion, that is, between the Vidian canal internally and the foramen rotundum externally. The same holds true if the posterior palatine canal is of wide caliber. This also permits a deflection of the needle outward.

It may be said that the proper method for utilizing the posterior palatine canal is one of measurement. The needle should not be inserted beyond a certain depth, but in as much as the nose varies from two to three inches from floor to roof it is obvious that any point of measurement is inaccurate. Observations have also shown that the length of the canal varies in skulls that seem to be pretty nearly the same.

The method of approach beyond the posterior tip of the middle turbinate has long been before you. I have a drawing here to remind you of it (Fig. 62). It, too, is not infallible as was shown a number of years ago (Fig. 66). As is well known, the anatomy varies in practically every nose and it takes an experienced rhinologist to be at all certain of injecting the ganglion from under the tip of the middle turbinate (Fig. 62). From my extended experience I believe that the approach through the sphenopalatine foramen is probably less difficult and more trustworthy than from under the tip of the turbinate. Moreover, the bone under the turbinate is very often so hard that it cannot be pierced by the needle used for this purpose. As I have previously mentioned, the question may arise, Why not drill a

Digitized by Illinois College of Optometry

small hole through this bone and reach it that way? When one recalls, however, that the internal maxillary artery is in intimate association with the ganglion and the whole pterygomaxillary fossa is small, one hesitates to drill into it.

It has been my experience that bleeding from puncture with the straight needle under the turbinate is very readily controlled by a small pack inserted to the bleeding point by a straight applicator. I know of one case, however, in which all methods failed and the carotid had to be ligated. The number of bleedings in my experience have been very few. When bleeding occurs from puncture through the sphenopalatine foramen it is very much more difficult to control and usually requires a postnasal plug drawn forcefully into place. It is my belief that the rarity of bleeding in injected cases makes the question almost negligible. I believe that any accident through the posterior palatine canal would be fraught with infinitely greater disaster. Ruskin uses a needle 4½ cm. in length. He advocates 3½ to 4 cm. insertion.

I have already spoken of applications of silver nitrate solution and formaldehyde (one per cent mercurochrome is better) made to the membrane covering the sphenopalatine foramen (which is usually inflamed). Often this suffices to stop the pain. When it does not, I recommend that the ganglion be injected with a 5 per cent phenol solution in 95 per cent alcohol. Formerly, I injected approximately two or three drops of this solution, and very often it sufficed; but the number of failures seemed to me unnecessarily large. For this reason, I have gradually increased the amount of the injection to 0.5 c.c. This larger amount is more successful, possibly for the reason that the ganglion is small and probably frequently missed. Alcohol alone, as advocated by Schlosser in 1893, used in these parts is intensely painful. For this reason I have added 5 per cent phenol[5] to it, which renders it painless in small injections—three or four drops. In 0.5 c.c. amounts it is usually followed by a slight sense of pain, which the patient recognizes as different from his neuralgia, and which lasts from two hours to three days. I have used 5 per cent phenol in water with less satisfactory results than the alcohol combination. Few untoward consequences have followed this procedure. On one occasion (Sluder and Ewing[1])

Digitized by Illinois College of Optometry

when the tissues of the sphenomaxillary fossa were evidently very loose, the alcohol passed outward and upward to reach the abducens in the sphenoidal fissure, paralyzing it. It recovered completely in three months. Dr. Joseph C. Beck had a similar experience with a patient who later consulted me. In this patient, however, the oculomotor was paralyzed. This led me to believe that the anatomy of the sphenoidal fissure varied.[4]

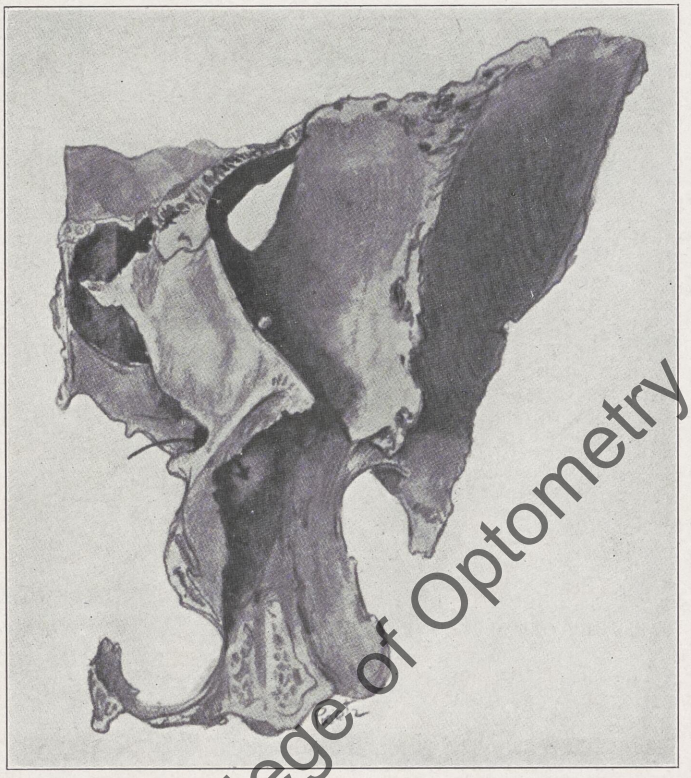

Fig. 70.—Bony environments of sphenopalatine foramen and sphenoidal fissure, demonstrating their relations and the distance between them. The foramen rotundum also appears.

Investigation showed that the abducens is not always the lowermost nerve in the fissure; the oculomotor may be lowermost. Figs. 70 to 75 show the anatomy of the sphenoidal fissure.

As a result of much post-graduate teaching in the past ten years I have concluded that the curved needle had better be used by beginners despite the fact that should hemorrhage oc-

Digitized by Illinois College of Optometry

cur it is harder to control than from the straight needle. In the hands of one who is not sure of the post-nasal anatomy it is possible for the straight needle to be seriously misplaced, which is not true of the curved needle. This is most particularly true where the landmark, i. e., the posterior tip of the middle turbinate, has been removed in operations on the ethmoid. This fact was brought forcibly to our attention at our clinic recently. A graduate student who was otherwise well trained lost his bearings under these conditions. The straight needle entered at a point above and forward of the right point and passed too far

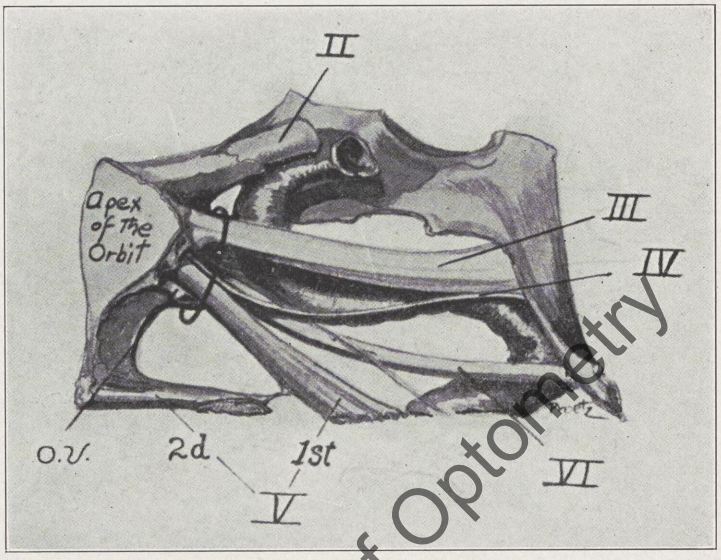

Fig. 71.—Semidiagrammatic representation of the contents of the sphenoidal fissure, showing their relations to one another, both in the fissure and in the cavernous sinus. Left side. The sixth nerve as it passes through the sphenoidal fissure here lies mesial to the fourth and the first division of the fifth above the ophthalmic vein. Note the position of the internal carotid with relation to the other structures.

outward. The alcohol reached the sphenoidal fissure and paralyzed the oculomotor and abducens and some of it reached the optic nerve. Much loss of vision followed. All nerves recovered with, however, some narrowing of the visual field. This disaster could scarcely have followed the use of the curved needle. It could not have penetrated the lateral wall except through the sphenopalatine foramen. One feels about over the district with the point of the needle. When it reaches the

Digitized by Illinois College of Optometry

sphenopalatine foramen it passes outward. There is no other foramen in these parts that permits the point of the needle to pass in the lateral direction.

The treatment as already described has been highly satisfactory in the great majority of cases. The injection, however, in old and severe cases must be repeated, possibly as often as ten times, *usually, however, not more than three.* Rarely there recurs, in severe cases, a considerable degree of pain, after from four to six weeks of comfort. In these cases, a rather strange phenomenon sometimes appears; namely, that cocaine applied to the region of the ganglion is at once painful, and the deeper

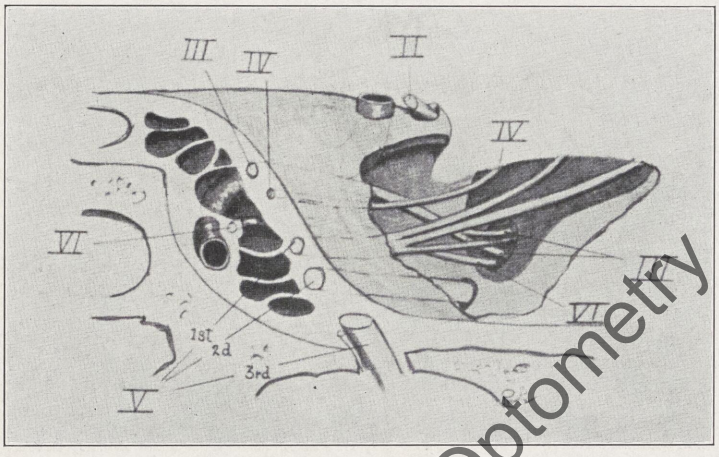

Fig. 72.—Relations of the structures in the cavernous sinus and the sphenoidal fissure as depicted in Cunningham's Anatomy.

the cocainization the more so it becomes. And, on the other hand, irritants such as stronger solutions of silver nitrate are soothing. I have seen five cases of this type. This phase was transitory. In old severe cases, I believe the difficulty of obtaining lasting relief is explained by the fact that the ganglion is surrounded by the changes of a hyperplastic post-ethmoidal sphenoiditis.

The investigations of Müller and Dahl which were unfortunately not known to me in 1918, are most interesting and apparently tell a story of the greatest importance in the pathology of tissues involved in this district with much valuable information bearing on the clinical side of them. They found a

Digitized by Illinois College of Optometry

great difference in the histological condition between the nasal ganglia of man and the same ganglia of animals. They examined forty ganglia from man, all of which showed degeneration. They stained badly and they appeared smaller and shrunken. This, however, was not true in the newborn or in animals. They suggest that the nasal ganglia may be degenerating along with the olfactory sense in man. If the ganglia are normal in the newborn and are found degenerated in maturity it seems to me that some subsequent influence in life has produced that change. It would be instructive to know whether the hyperplastic post-ethmoidal-sphenoidal lesion was not present in all of the specimens they examined. That lesion, as I know, is recognizable

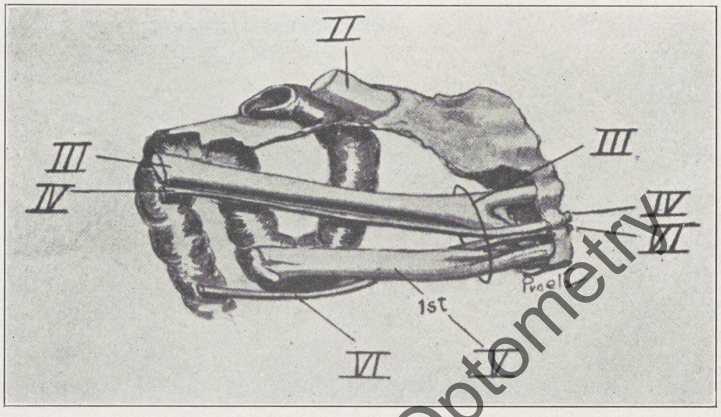

Fig. 73.—Contents of the sphenoidal fissure right side. In this case the sixth nerve passing through the cavernous sinus mesial to, and at a lower level than the first division of the fifth, ascends still mesial to it and traverses the sphenoidal fissure above it and in conjunction with the fourth. Note the variation in plane and degree of tortuosity of the internal carotid as compared with Fig. 71.

so often (with or without symptoms) that the remark of Doctor Jonathan Wright concerning it is most pertinent in this connection (see page 230). I know that the hyperplastic post-ethmoidal-sphenoidal lesion is present to a degree of frequency that could it be put as a percentage, it would astonish us all, however familiar we may be with that region. Persons can, however, be found in whom it does not exist. But as a rule they must be selected from those who have not had nasal troubles and have not been afflicted with headaches. They may be found in all ages and both sexes.

Digitized by Illinois College of Optometry

The hyperplastic lesion involves the soft parts as well as the bone. It probably begins in the soft parts.

For a long time I have felt that the old and "stubborn" ganglion cases are the result of the ganglion being imbedded in the hyperplastic lesion, which may readily explain the changes found by Müller and Dahl. I have repeatedly seen the involution of the hyperplasia follow the alcoholic injection of this region and have construed the good clinical results in these cases to this fact quite as much or more than to the effect of the alcohol upon the ganglion cells and that many of the disappointments (clinically) follow where this involution did not take place. May showed that the effect of alcohol upon the semilunar ganglia cells was transitory.

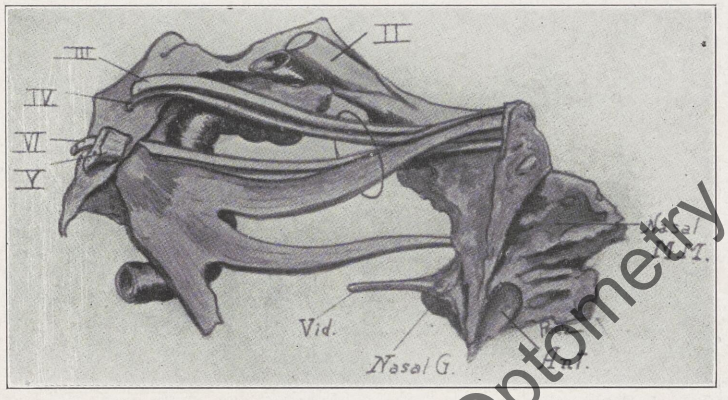

Fig. 74.—The contents of the sphenoidal fissure, showing their relations to one another and to the nasal ganglion and the Vidian nerve. The intimate relation of the ganglion to the posterior superior extremity of the maxillary sinus is also shown.

Lateral view of structures on the right side.

It is unfortunate that the observations of Müller and Dahl are not accompanied by case histories.

The above argument may seem plausible as far as it goes. It seems untenable, however, from the fact that they found the same to be true of the cells of the otic ganglion which is situated close under the foramen ovale and far removed from nasal tissues, deeply imbedded in the soft parts. Only rarely does the sphenoidal cell extend laterally to the foramen ovale. Müller and Dahl think their findings argue an involution in these ganglia corresponding to that of the sense of smell in man.

Digitized by Illinois College of Optometry

In the hyperplastic lesion it is not uncommon to find upon opening the cells, that they contain polyps where no evidence of their presence existed in the nose. Inasmuch as the sphenomaxillary fossa is so like a paranasal cell (page 83), it is most plausible to assume that changes occur in it as a result of the hyperplastic changes that surround it on all sides, save the external aspect. A ganglion imbedded in this tissue of low grade chronic inflammation, it would seem, must be irritated by it. Injection of this fossa with phenol-alcohol often has the effect of reducing the hyperplastic changes.

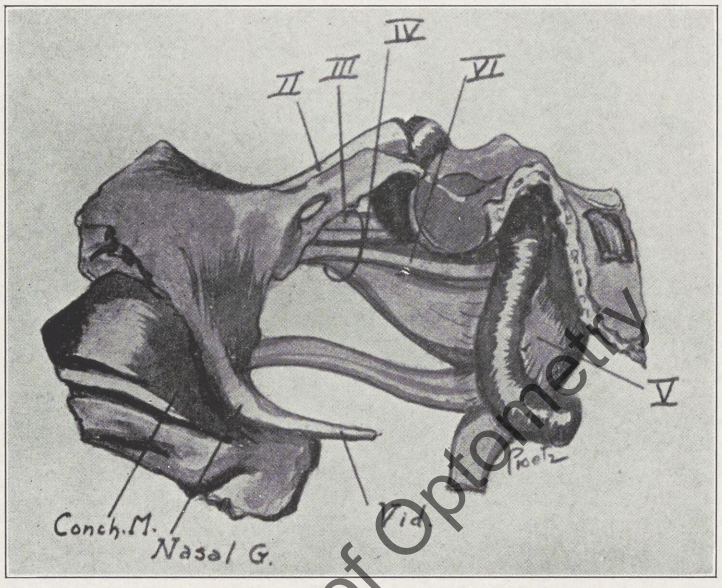

Fig. 75.—The same dissection shown in Fig. 74, but viewed from the mesial side. The relations of the concha medialis, the nasal ganglion and the contents of the sphenoidal fissure are shown.

Each injection should be followed by some lessening of the patient's suffering. It may be repeated as often as needs be, allowing an increasing span of time between each, i. e., the second two or three weeks after the first, the third from four to six weeks after the second, increasing the span then to six weeks each time. I suggest this, because the reaction following the instillation of the phenol-alcohol becomes more severe the oftener it is done. *In severe cases of this class the patients suffer a terrible affliction; the surgeon is put at his wits' end*

Digitized by Illinois College of Optometry

for judgment, perseverance and skill. These facts cannot be too greatly emphasized. Particularly difficult of judgment are cases where anesthesia of the ganglion stops the pain, but in which there is, in addition, a considerable hyperplastic sphenoiditis, in frail, nervous patients. The surgeon hesitates to perform the radical sphenoidal operation because of the low resistance of the patient. Patient efforts by injection usually succeed. The shock of the injection is very much less than the sphenoidal operation, but these cases usually require more perseverance because the sphenoiditis may reestablish the pain by virtue of the maxillary and Vidian nerves passing through the bone before reaching the ganglion. This class of cases will be considered again with more detail in the chapter on Hyperplastic Sphenoiditis.

After having made a large number of alcohol-phenol injections of the nasal ganglion my interest has become aroused in learning the probable depth of penetration or the distance of infiltration of the nerve sheaths. To this end I engaged the services of Dr. B. J. McMahon, Instructor in the Department of Oto-Laryngology at the Washington University School of Medicine, who very kindly performed the following experiments.

In a series of three dogs the supraorbital and infraorbital nerves were injected with 0.3 c.c. of saturated solution of methylene blue in 95 per cent alcohol and 5 per cent phenol. Under ether anesthesia the supraorbital nerve was injected at a point immediately medial to a small tubercle at the junction of the internal and middle thirds of the supraorbital ridge. The nerve was found at this point by dissection later. The infraorbital nerve was injected through the infraorbital canal. After 10 minutes the dogs were killed with ether. Dogs 1 and 2 were dissected immediately and Dog 3 after 24 hours.

In the first two experiments with supraorbital nerve injection the solution was found in the loose areolar tissue of the orbital fossa immediately adjacent to the supraorbital nerve. The needle apparently failed to penetrate the sheath. In the third experiment the results were the same except that the solution had slightly penetrated the nerve sheath on one side.

In the experiments for the infraorbital nerve the injection was made after dissecting down to the nerve in one instance;

Digitized by Illinois College of Optometry

in the others the injection was made through the skin. It was found that where the needle had pierced the nerve sheath the solution infiltrated for a distance of about one-half inch.

The technical difficulties encountered were as follows: (1) As a result of the absence of the supraorbital notch, the exact location of the nerve could not be determined by superficial examination. (2) The supraorbital nerve was imbedded in loose areolar tissue, with no way of preventing it from rolling from under the point of the needle when injection was attempted.

These experiments lead us to assume that in injection of the nasal ganglion the solution does not penetrate to the pain and involuntary centers but travels for only a short distance along the nerve sheaths or remains in the sphenomaxillary fossa.

About fifteen years ago I injected the nasal ganglion in a number of specimens simulating in every way the veritable performance in life. I used a suspension of Prussian blue (ferrocyanide of iron) in alcohol. Specimens were then decalcified in dilute hydrochloric acid and sectioned. The Prussian blue was found uniformly limited to the pterygomaxillary fossa.

Aside from references included in this chapter a number of other authors have given some of their experiences, to wit: E. A. Abernethy, C. T. Uren, J. C. Braswell, Fred Fisher, Jr., H. A. Etheridge, Louis Baer, J. Ramadier, G. Coulet, M. H. Hood, H. C. Miller, L. S. Gaudet, J. D. Cook, M. B. Boebinger, A. K. Wilson, Niel Maclay, J. A. Buchanan, R. Mégeville, L. K. Gundrum.[2]

Digitized by Illinois College of Optometry

CHAPTER VI

HYPERPLASTIC SPHENOIDITIS AND ITS CLINICAL RELATIONS TO THE ENVIRONING NERVES, TO WIT: N. OPTICUS, N. OCULOMOTORIUS, N. TROCHLEARIS, N. TRIGEMINUS, N. ABDUCENS AND N. CANALIS PTERYGOIDEI (VIDII), AND NASAL GANGLION*

Although hyperplastic changes within the nasal fossae have been described by many writers and although special attention has been given to the study and description of this mor-

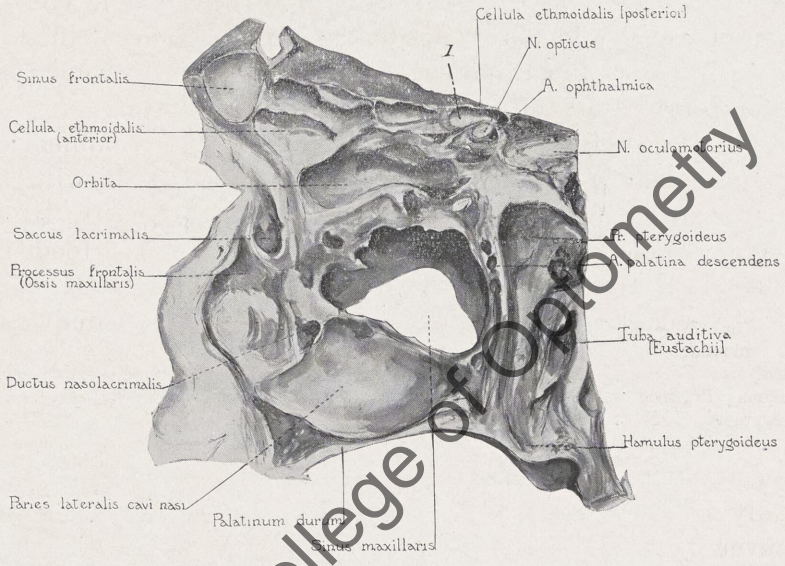

Fig. 76—Left sagittal section 3 mm. lateral to sphenopalatine foramen showing post-ethmoidal cell *1*, above and beyond optic nerve. Viewed from without inward.

bid process in the ethmoidal district, no mention or study of this process in the sphenoidal district existed until 1915 when I presented it to the American Laryngological Association.[20] To me it seems a matter of the *greatest importance* and *far-*

*The first allusion to this subject by me was in an article read before the American Laryngological Association, 1912.[27]

Digitized by Illinois College of Optometry

reaching possibilities because of the *intimate association* of the many *nerve trunks in the region of the body of the sphenoid.*

In 1912 I[27, 46] presented the anatomy of this district in a way differing from the extant descriptions in all particulars. These observations were confirmed by Dr. Ladislaus Onodi[2] working by a different method. Fig. 77 illustrates the dissection method employed by him. We worked independently and unknown to each other. (He did not, however, observe the Vidian nerve at that time.)

Familiarity with this anatomical detail is necessary for the purposes of this essay.

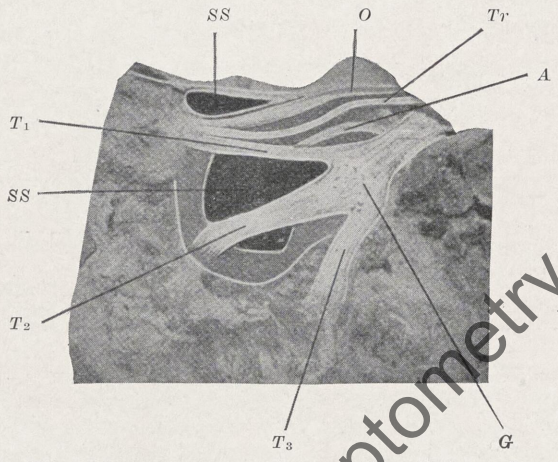

Fig. 77.—The thin transparent bony wall of the sphenoidal sinus has been removed. *SS*, Sphenoidal Sinus; *G*, Gasserian ganglion; T_1, first division of trigeminus; T_2, second division of trigeminus; T_3, third division of trigeminus; *A*, abducens; *Tr*, trochlearis; *O*, ocuolmotorius. (Actual size.) (From L. Onodi, Arch. f. Laryngol., 1912, xxvi.)

Anatomical Relations.—The body of the sphenoid bone is usually hollowed out by the sphenoidal sinus. This cell may, however (rarely), be rudimentary and occupy a very small space in the lower anterior part of the body, which is otherwise hollowed out by a post-ethmoidal cell, or the body may be more or less evenly divided by these cells. It is of the cell which hollows the body of the sphenoid that I write, regardless of whether it be the sphenoidal sinus proper or a post-ethmoidal cell or both.

The body of the sphenoid is covered above and laterally by the dura mater, with the cavernous sinus between its exter-

Digitized by Illinois College of Optometry

nal and internal surfaces (in it), occupying a position for the most part above and lateral to the body. The optic canal is situated at the upper outer anterior part of the body of the sphenoid. Its inner part is always in association with either the sphenoidal sinus or a post-ethmoidal cell. (A. Onodi, Loeb,[1]

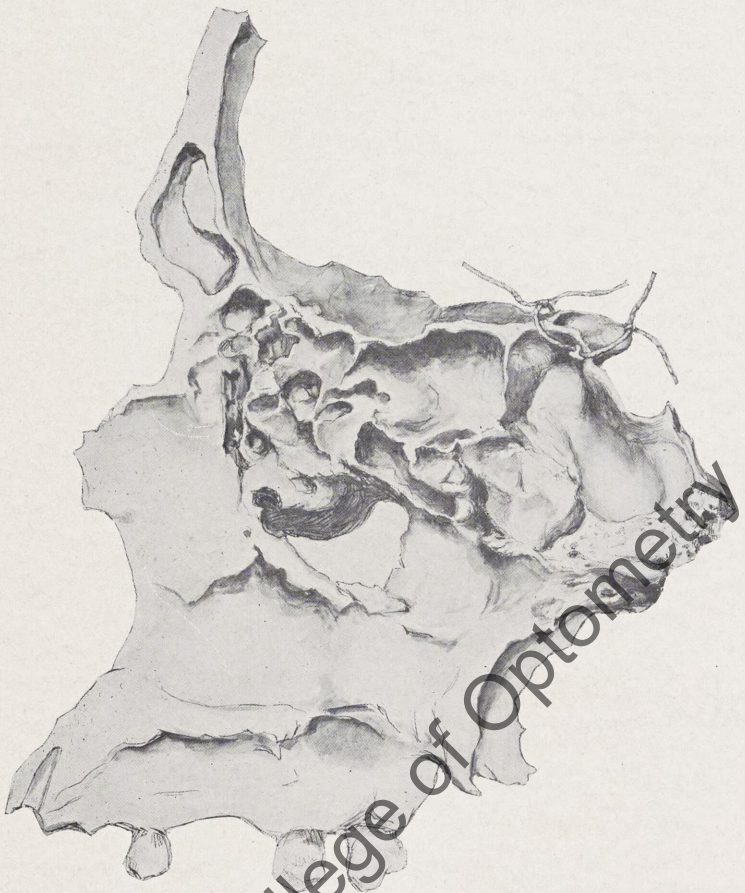

Fig. 78.—Showing prolongation of sphenoidal sinus around optic canal. The ligatures are passed under the optic canal and anterior clinoid process.

Westlake.) And not infrequently these cells send a prolongation outward to extend more or less around the canal from above or below (rarely completely around) (Figs. 76, 78 and 79). The optic nerve is in no way associated with the cavernous sinus. All the other nerves in this district, i. e., third, fourth, first and second divisions of fifth and sixth are in association with

Digitized by Illinois College of Optometry

it. Within the cavernous sinus are found the internal carotid artery and the third, fourth, and sixth cranial nerves, with the first division of the fifth lying in the lower part of its lateral wall. The impression given in the treatises on anatomy is, usually, that those nerves are rather widely separated from the sphenoidal sinus, as shown in Figs. 80, 81, 82, 83 and 84. The

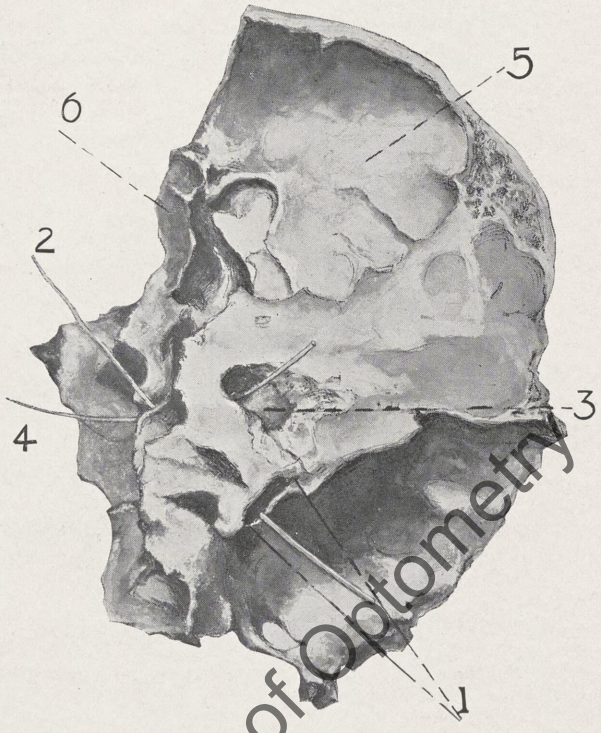

Fig. 79.—Anterior and middle fossae of skull seen from above. *1.* Lesser wing of the sphenoid cut open just lateral to the anterior clinoid process to show bristle *2* passed from the sphenoidal sinus under the optic canal *3*. *4*. Bristle from a post-ethmoidal cell. The extent and association of this cell with the optic canal is shown by the removal of the cranial plate exposing the optic canal *3* for 1 cm. *5*. Floor of very large frontal sinus, the cranial plate of which is removed. *6*. Ethmoidal cells.

second and third divisions of the fifth and the Vidian nerves are usually represented as well removed from the cell; that is, separated by a considerable thickness of bone (Fig. 80). The fact is, the third division of the fifth nerve is the only one that is not at times in close association with this cell; that is, separated from it by a very thin layer of bone; and even this nerve

Digitized by Illinois College of Optometry

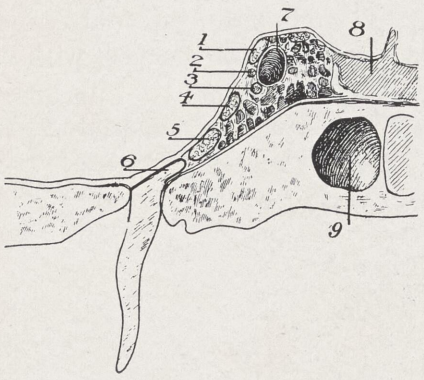

Fig. 80.—Showing an older representation of the sphenoidal sinus and the cavernous sinus. *1.* N. oculomotorius. *2.* N. trochlearis. *3.* N. abducens. *4.* N. ophthalmus. *5.* N. maxillaris. *6.* Styloid process of temporal bone. *7.* Art. carotis int. *8.* Hypophysis. *9.* Sphenoidal Sinus. (After Merkel.)

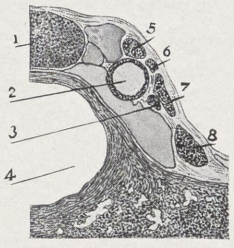

Fig. 81.—Cross transverse section of the cavernous sinus. *1.* Hypophysis. *2.* Internal carotid artery. *3.* N. abducens. *4.* Sphenoidal cell. *5.* N. oculomotorius. *6.* N. trochlearis. *7.* N. ophthalmicus. *8.* N. Maxillaris. (After Quain.)

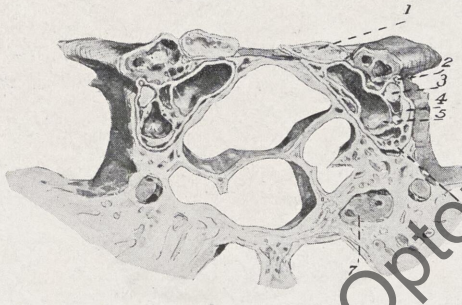

Fig. 82.—The usual cavernous sinus with large cross section and great length. Shows wide separation of all cranial nerves from body of sphenoid. *1.* N. opticus. *2.* N. trochlearis. *3.* N. oculomotorius. *4.* N. ophthalmicus. *5.* N abducens. *6* Cavernous sinus. *7.* Vidian canal.

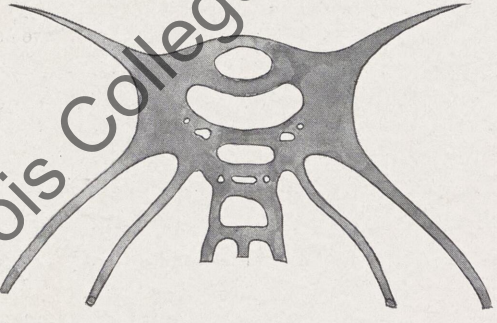

Fig. 83.—Cavernous sinus district. (After Rouber and Kapsch.)

Digitized by Illinois College of Optometry

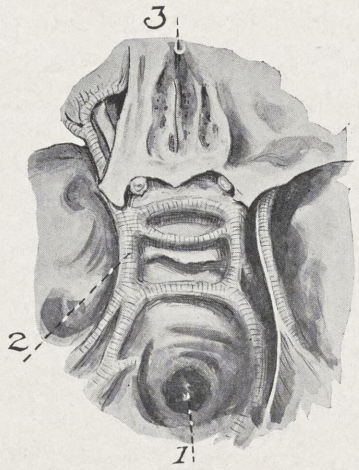

Fig. 84.—Cavernous sinus district. *1.* Foramen magnum. 2. Cavernous sinus. *3.* Crista galli. (After Piersol.)

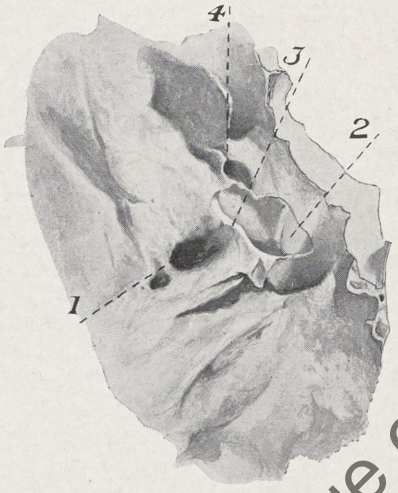

Fig. 85.—Left middle fossa of skull, viewed from above and to the left showing foramen ovale separated from sphenoidal sinus *2* by thin bone *3*. (The third division of the fifth passes through the foramen ovale.) *4.* Foramen rotundum.

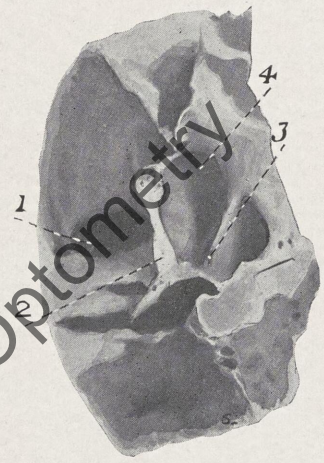

Fig. 86.—Same specimen as Fig. 60 viewed from above and to the right. *1.* Foramen rotundum. *2.* Bone separating sphenoidal cell *4*, from foramen rotundum. *3.* Vidian canal dehiscent at point of indicator.

is sometimes also in rather close association with it (Figs. 85, 86 and 87). The sixth, so far as I have found, in the cavernous sinus, is uniformly placed on the lateral aspect of the carotid and always removed from this bony wall. Thus far I have been writing of a sphenoidal sinus which is limited to the body

Digitized by Illinois College of Optometry

of the sphenoid. Should it be extended into the greater wings, the sixth nerve may come into close association with it in the sphenoidal fissure below (Sluder[4]) (Fig. 87). Should the sphenoidal sinus be prolonged backward to the clivus of Blumenbach (Fig. 87), the sixth nerve will be in very close association with it as it passes under the dura mater. This was first pointed out by Ladislaus Onodi.[2]

The fact which determines the relations of these nerve trunks to the sphenoidal sinus is the *size of the cavernous sinus*

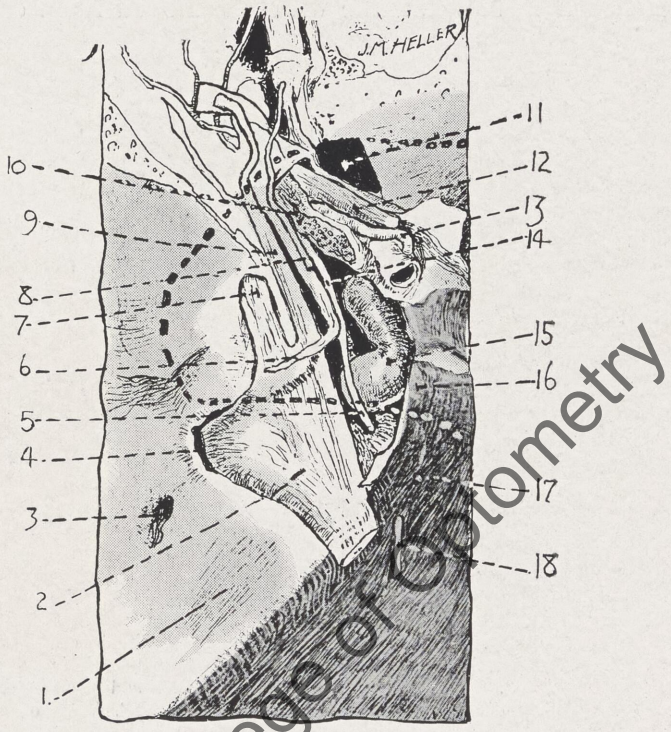

Fig. 87.—Top view of left sphenoidal district dissected. *1.* Petrous part of temporal bone. *2.* Semilunar (Gasserian) ganglion. *3.* Foramen spinosum. *4.* Foramen ovale with mandibular nerve in it. Inside the sphenoidal cell the bone surrounding the foramen ovale containing the mandibular nerve is marked as a canal 5 mm. long, separated in a semicircular exposure from the sphenoidal cell by bone 1 mm. thick. *5.* Abducent nerve. *6.* Oculomotor nerve. *7.* Maxillary nerve entering foramen rotundum. *8.* Trochlear nerve. *9.* Ophthalmic nerve. *10.* Inner limit of sphenoidal fissure. *11.* Opening dissected into sphenoidal sinus. *12.* Optic nerve. *13.* Ophthalmic artery. *14.* Abducent nerve. *15.* Internal carotid artery. *16.* Posterior ethmoid process. *17.* Clivus of Blumenbach. *18.* Abducent nerve. Dotted line shows outline of sphenoidal sinus. It is separated from the overlying structures by a wall of bone, eggshell thin, including those in the sphenoidal fissure. The inner two-thirds of the semilunar ganglion for almost one-half its length are also included in this close association.

Digitized by Illinois College of Optometry

rather than the size of the sphenoidal sinus. If the cavernous sinus is large in length and cross section, these nerve trunks will be far removed from contact with the body of the sphenoid and the sinus within it. On the other hand, if the cavernous sinus is small in length or cross section, these nerve trunks may be closely associated with a sphenoidal sinus limited to the body of the sphenoid bone. Nerves in the canals, to wit, the optic, maxillary and Vidian, are not under this control.

Obviously, a small sphenoidal sinus in the center of the body of the sphenoid bone will be widely removed from contact with

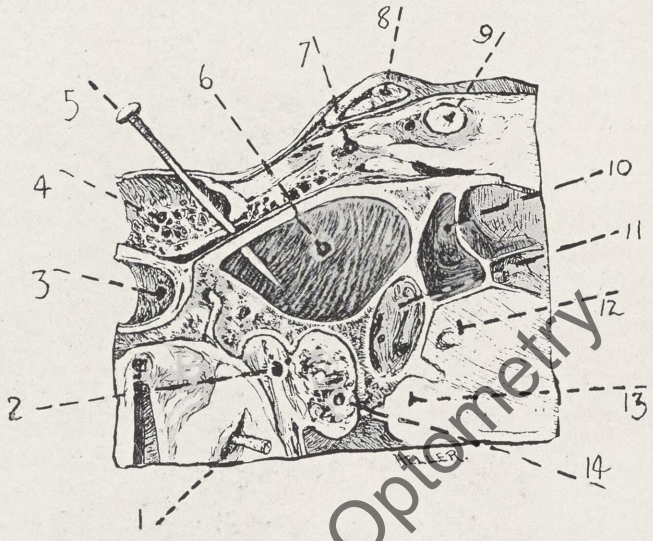

Fig. 88.—Shows a sagittal section of left side through the ophthalmic nerve. *1.* Eustachian tube with bristle in its lumen. *2.* Tensor palati muscle. *3.* Part of internal carotid artery. *4.* Semilunar ganglion in Meckel's cave. *5.* Pin passed through wall of sphenoid. *6.* Sphenoidal sinus. *7.* Ophthalmic nerve. *8.* Lesser wing of sphenoid. *9.* Optic nerve. *10.* Post-ethmoidal cell. *11.* Pterygomaxillary fossa. *12.* Opening dissected into maxillary antrum. *13.* Wall of nose. *14.* Internal pterygoid muscle.

these nerve trunks, regardless of whether the cavernous sinus is large or small (Fig. 80). A sphenoidal sinus of large extent, prolonged backward and outward, may readily closely approach the third division of the fifth nerve in the foramen ovale (Fig. 85). Dr. H. P. Mosher has loaned me two specimens in which the sinus extended to a close association with the semilunar ganglion. I too have found such specimens and here report two of them in detail.[39] (Figs. 87, 88 and 89.)

Digitized by Illinois College of Optometry

The semilunar ganglion is at present thought of as so far removed from the sphenoidal sinus that they have not been associated in the minds of the anatomists or clinicians. The internal carotid artery usually rises on the lateral aspect of the body of the sphenoid and the semilunar ganglion is usually lateral and posterior to the ascending artery. This, however, is not always true. The position of the artery seems to have a large part in determining these relations.

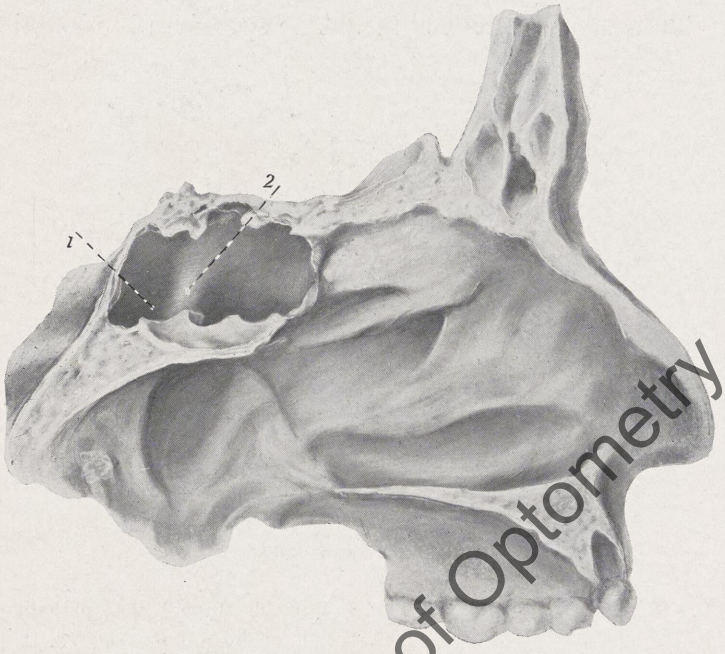

Fig. 89.—Sphenoidal cell. *2*. Columnar marking of the internal carotid artery. Note that the sphenoidal cell extends far lateral to this. At the place *1* it extends to the region of the Gasserian ganglion.

I present drawings of two specimens showing an intimate relation of the sphenoidal sinus to the semilunar ganglion, or parts of it. Fig. 87 shows a dissection of the cavernous sinus, semilunar ganglion and sphenoidal fissure viewed from above. The sphenoidal sinus lying beneath these structures is shown in dotted line. The thickness of bone separating the cavity of the sphenoid from these structures is eggshell thin. The internal two-thirds of the ganglion are exposed to the uppermost part of the sphenoidal cell and the external third is exposed at

Digitized by Illinois College of Optometry

a slightly greater depth as the nerve tissues approach the foramen ovale. The mandibular nerve in the foramen ovale is exposed for 10 mm. to an eggshell bone separation from the sphenoidal cell.

In the sphenoidal fissure the oculomotor, abducent and ophthalmic nerves are exposed to an eggshell separation from the sphenoidal cell. The trochlearis alone is not in this contact because it lies on top of the oculomotor.

Fig. 88 shows a sagittal section through the oculomotor nerve within the cavernous sinus. The specimen is viewed from

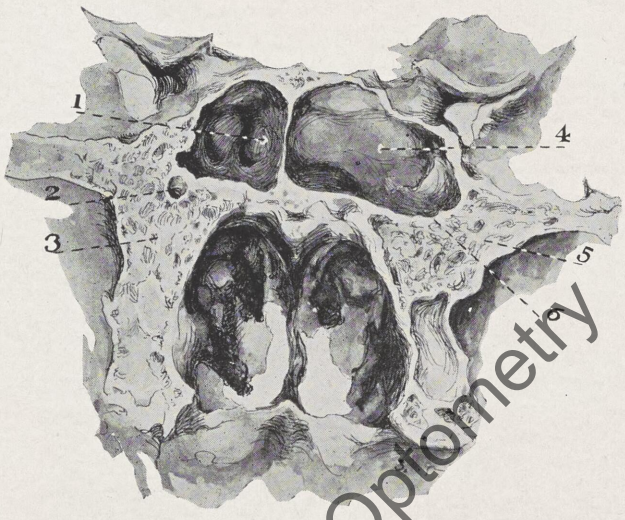

Fig. 90.—Showing Vidian exposed in right sphenoidal sinus. Cross section through the pterygoid processes. *1.* Left sphenoidal cell. *2.* Vidian canal. *3.* Pterygoid process. *4.* Right sphenoidal cell. *5.* Pterygoid process. *6.* A groove marking the Vidian canal. Its upper part is missing.

within outward. In this specimen the Gasserian ganglion is exposed on its anterior limit for 10 mm. to an eggshell thin bone separation from the sphenoidal sinus at the origins of the ophthalmic and maxillary divisions. The sphenoidal cell measured 1.50 cm. sagittally, 4.50 cm. vertically, 5.50 cm. transversely.

In 1912 I[7] proved the permeability of the wall of the sphenoidal sinus to small amounts of cocaine. Following this observation, with its lesson, into these anatomical associations seems to me to offer an explanation of the herpes which develops in the wake of sphenoidal infections or which arises in some

Digitized by Illinois College of Optometry

patients from ordinary coryzas (irritation of the sensory ganglion cells being necessary for the development of herpes), and to explain why semilunar ganglion neuralgias and tic douloureux of sphenoidal origin sometimes recover as a more or less acute or subacute lesion and at other times require a ganglion removal or a posterior root section, i. e., sometimes the sphenoidal lesion can be controlled and at other times it cannot (Sluder[44]).

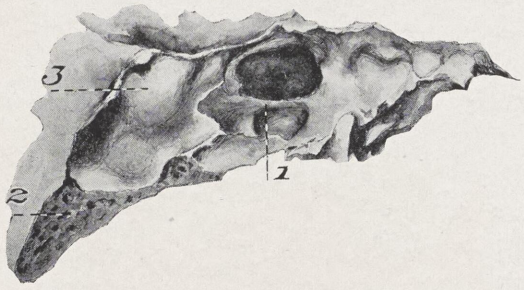

Fig. 91.—*1.* Left Vidian canal deficient at point of indicator. *2.* Basilar process of occiput. *3.* Septum sphenoidale.

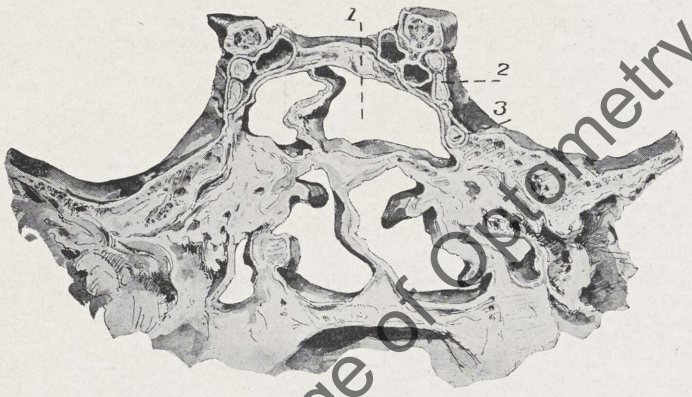

Fig. 92.—*1.* Right sphenoidal cell. *2.* 1st division of fifth nerve. *3.* 2nd division of fifth nerve.

A sinus extending downward approaches the Vidian nerve. In fact, the upper side of the bony case of the Vidian canal is often partly deficient under these circumstances (Fig. 90). The excavation may also extend below the level of the canal and leave it stalking through the sphenoidal sinus like an ancient aqueduct, over the plain, connected with the bone below by a paper-like support (Fig. 91). Or it may be protected on one side of, and exposed on the floor of the sinus of the other

Digitized by Illinois College of Optometry

side of the skull (Fig. 90). The sphenoidal sinus extended laterally soon reaches the foramen rotundum and may then surround one-half of its circumference, bringing the second division of the fifth at this point, and for some distance posterior to it, into very close association with it (Figs. 92 and 93). The third and fourth nerves are in close association with the ante-

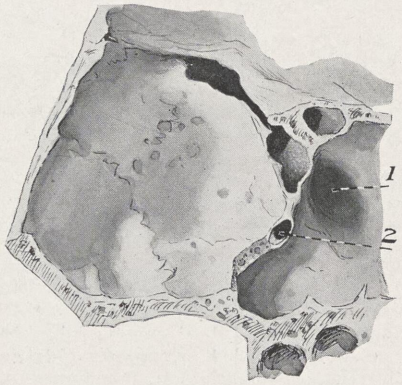

Fig. 93.—Showing paper-thin separation of maxillary nerve in foramen rotundum from sphenoidal sinus. *1.* Sphenoidal sinus. *2.* Foramen rotundum.

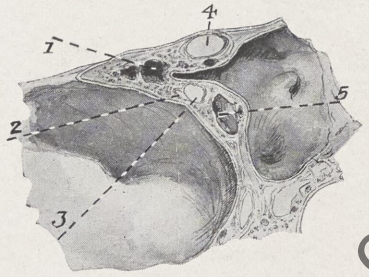

Fig. 94.—Cross section just anterior to anterior clinoid process. *1.* Lesser wing of sphenoid. *2.* N. trochlearis. *3.* N. oculomotorius. *4.* N. opticus. *5.* Anterior beginning of cavernous sinus.

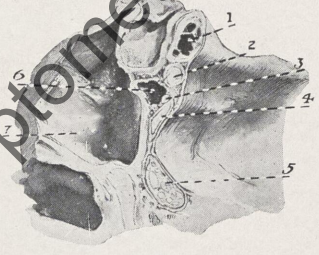

Fig. 95.—Cross section. *1.* Anterior clinoid process right. *2.* N. oculomotorius. *3.* N. trochlearis. *4.* N. ophthalmicus. *5.* N. maxillaris. *6.* Anterior beginning of cavernous sinus. *7.* Middle fossa of skull.

rior clinoid process or lesser wing of the sphenoid, which are not infrequently hollowed out by a prolongation of the sphenoidal sinus or (from in front) by an extension from a post-ethmoidal cell, thereby bringing these nerves also into close association with these cells (Fig. 94). The first division of the fifth comes into close association with the sphenoidal sinus ante-

Digitized by Illinois College of Optometry

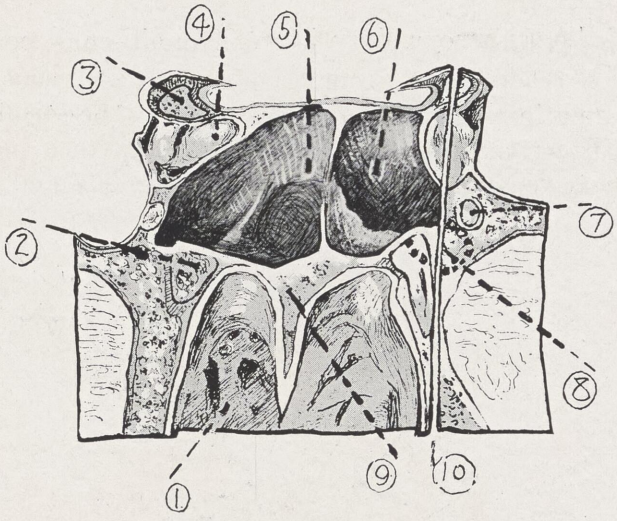

Fig. 96.—Cross section of sphenoidal body through anterior clinoid processes posterior to optic canals, seen from in front. *1.* Remnant of pharyngeal tonsil. *2.* Anterior outlet of Vidian canal with Vidian nerve. *3.* Anterior clinoid process. *4.* Internal carotid artery in the cavernous sinus making its upturn. *5.* Right sphenoidal sinus. *6.* Left sphenoidal sinus. *7.* Foramen rotundum with maxillary nerve. *8.* Dotted line showing the prolongation of sphenoidal sinus outward at a place posterior to line of transverse cut showing how it approaches the foramen rotundum. *9.* Sphenoid-vomer junction. *10.* Line of sagittal cut, the outer portion of which is shown in Fig. 97.

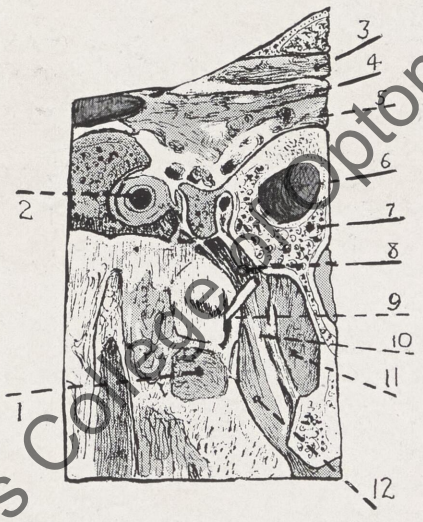

Fig. 97.—Lateral part of sagittal section through line *10* of Fig. 96. *1.* External pterygoid muscle. *2.* Internal carotid artery. *3.* Oculomotor nerve. *4.* Ophthalmic nerve. *5.* Cavernous sinus. *6.* Lateral limit of sphenoidal sinus. *7.* Bony wall of sphenoidal sinus. *8.* Tensor palati muscle. *9.* Eustachian tube with bristle in its lumen. *10.* Tensor palati. *11.* Internal pterygoid muscle. *12.* Levator palati muscle.

Digitized by Illinois College of Optometry

riorly, if the cavernous sinus is small in either direction (Figs. 92 and 95).

The relations of the eustachian tube to the sphenoidal sinus were described by me in 1916.[38] In the usual skull the tube at all points is far (1.50 cm.) removed from the sphenoidal sinus.

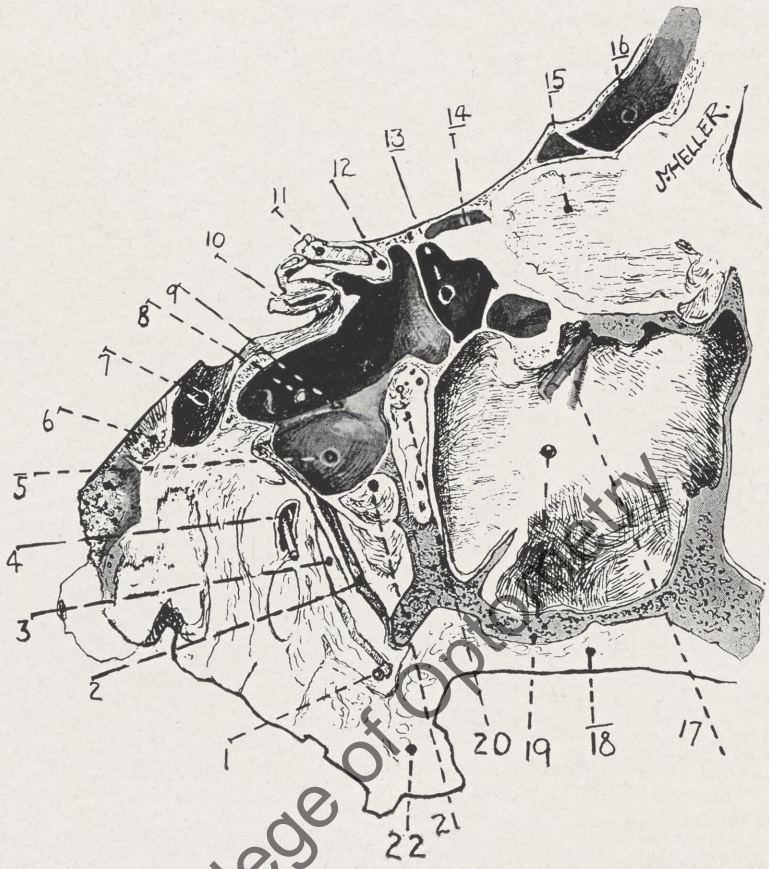

Fig. 98.—Sagittal section between the foramen rotundum and Vidian canal right side, viewed from without inward. *1.* Hamular process. *2.* Tensor palati muscle. *3.* Levator palati. *4.* Eustachian tube with bristle in its lumen. *5.* Sphenoidal sinus prolonged downward into pterygoid process to bifurcation of the plates. *6.* Clivus of Blumenbach. *7.* Groove for carotid artery. *8.* Nasal (internal) part of sphenoidal sinus. *9.* Vidian canal crossing the sinus. *10.* Internal carotid. *11.* Optic nerve. *12.* Lesser wing of sphenoid. *13.* Post-ethmoidal cell. *14.* Superior rectus. *15.* Orbital fat. *16.* Frontal sinus. *17.* Bristle passed from maxillary antrum through its outlet into middle meatus of nose. *18.* Hard palate. *19.* Maxillary antrum (nasal wall seen from without). *20.* Nasal ganglion. *21.* Internal pterygoid muscle. *22.* Soft palate. The optic canal in this specimen is surrounded two-thirds of its circumference by sphenoidal sinus for 10 mm. of its length. Observe close association of eustachian tube to sphenoidal sinus.

Digitized by Illinois College of Optometry

Fig. 96 shows a transverse section through a sphenoid which seems to me to represent average sized sphenoidal cells. The right measures 2.25 cm. transversely, 2 cm. vertically, and 2 cm. sagittally. The left measures 2 cm. transversely, 1 cm. vertically, and 2 cm. sagittally. Fig. 97 shows a sagittal section of the same specimen just internal to the foramen rotundum. The eustachian tube (with bristle in its lumen) is seen to be 1.5 cm. removed from the nearest approach of the sphenoidal cell. Such relations preclude that a prejudicial effect is exercised on the tube by an inflammatory process in the sphenoid.

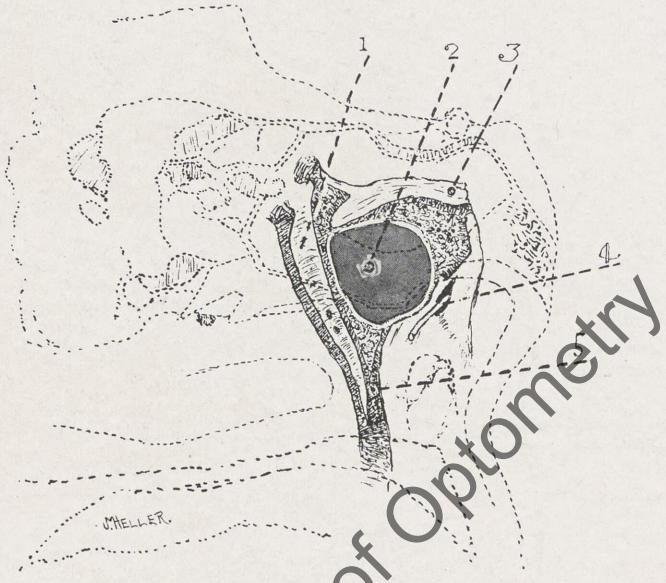

Fig 99.—Sagittal section of specimen shown in Fig. 100 through the maxillary nerve. *1.* Pterygomaxillary fossæ. *2.* Sphenoidal sinus prolonged into pterygoid process to the bifurcation of the plates. *3.* Maxillary nerve. *4.* Eustachian tube with bristle in its lumen. *5.* Pterygoid process. The dotted line of Fig. 5 is shown as superimposed. Observe the very close association of eustachian tube *4* with bristle in its lumen with the sphenoidal sinus *2*.

When the sphenoidal cell is prolonged downward into the pterygoid process it approaches the eustachian tube more or less, and it may come to such close association as to be separated by an eggshell thickness of bone (Figs. 98, 99 and 100). This comes about through two factors, first the thickness of the bone of the pterygoid process is absent, and secondly the origin of the tensor palati is not from the uppermost limit of the plate.

Digitized by Illinois College of Optometry

Should the tensor palati arise high on the plate the thickness of the muscle will enter in between the tube and the bone of the sinus wall (Fig. 101). Should, however, the tensor extend a lesser distance upward on the plate the tube comes into closer relation and in some specimens is in contact with the eggshell-thick wall of the sinus (see Figs. 98, 99 and 100).

Figs. 102 to 106 illustrate by x-ray the extension of the sphenoid into the pterygoid process. Figs. 107 and 108 show x-ray plates of large sphenoids often seen in practice but of no

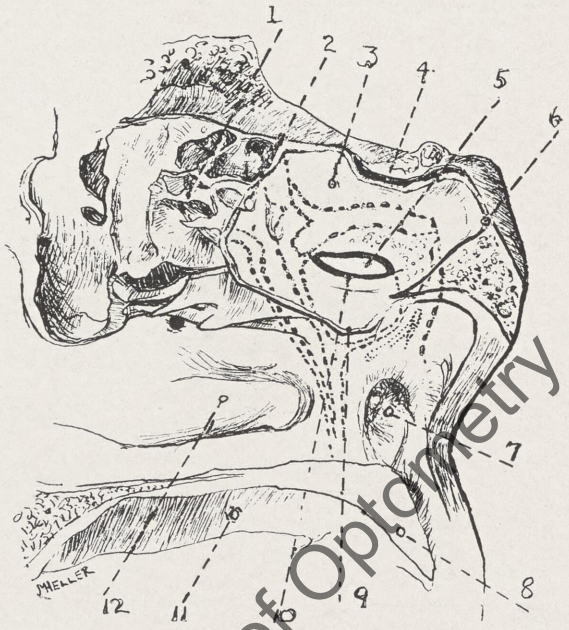

Fig. 100.—Showing the nasal (internal) surface of specimen shown in Fig. 99. *1.* Post-ethmoidal cells. *2.* Anterior limit of sphenoidal sinus. *3.* Sphenoidal sinus. *4.* Upper limit of sphenoidal sinus. *5.* Looking into lateral part of sinus. *6.* Posterior limit of sphenoidal sinus. *7.* Eustachian tube mouth. *8.* Soft palate. *9.* Lower limit of sphenoidal sinus. *10.* Vidian canal. *11.* Hard palate. *12.* Lower turbinate. The dotted line of Fig. 99 is shown in the depths.

especial significance. Figs. 109 and 110 represent the same sphenoid as shown in Fig. 108 filled with iodized oil.

Piersol (*Human Anatomy,* 1907, p. 1503) states that the glands of the membrane lining the tube pierce the depths to perforate the clefts in the cartilage extending into the surrounding connective tissue.

In 1912 I proved[27] the permeability of the thin sphenoidal

Digitized by Illinois College of Optometry

wall by an intrasphenoidal application of cocaine, paralyzing the entire fifth nerve. (See Case 17.) Such permeability it seems to me would allow an irritation in the tubes in such a case as Figs. 99, 100 and 101 as long as the sphenoidal inflammation continued. I believe this to be the explanation of some surprisingly fine results for abandoned cases of low grade deafness following post-ethmoidal-sphenoidal surgery.[45] (See Case 111.) I have previously thought these cases to have been crippled Vidian nerves from sphenoidal sinus inflammation—the great superficial petrosal nerve from the geniculate ganglion of the seventh (part of the Vidian) being the motor supply to

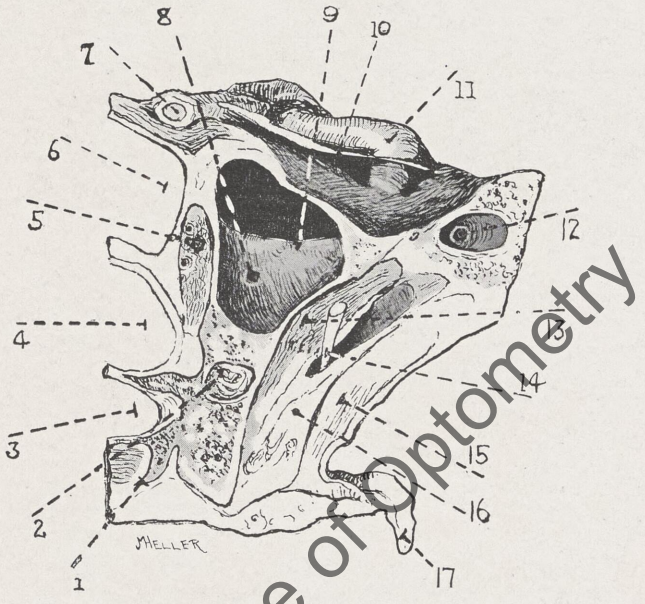

Fig. 101.—Sagittal section between foramen rotundum and Vidian canal, viewed from without. *1.* Hamular process. *2.* Internal pterygoid muscle. *3.* Lower meatus. *4.* Middle meatus. *5.* Nasal ganglion. *6.* Upper meatus. *7.* Optic nerve. *8.* Sphenoidal sinus. *9.* Vidian canal. *10.* Abducent nerve. *11.* Internal carotid artery. *12.* Internal carotid. *13.* Tensor palati muscle. *14.* Eustachian tube with bristle in its lumen. *15.* Palatopharyngeus muscle. *16.* Levator palati. *17.* Soft palate.

Observe 12 mm. separation of eustachian tube *14* from sphenoidal sinus *8* despite the prolongation of the latter into the pterygoid process to the bifurcation of the plates. In this case the tensor palati rises high and separates them.

the tensor and levator palati—they being thereby unable to perform their full functions so that these muscles did not open the tube properly.

Digitized by Illinois College of Optometry

I believe both explanations are correct in the two types of cases respectively.

Clinical Relations.—Clinically the inflammatory diseases of the paranasal cells vary greatly. Each has, however, some semblance of constancy in its behavior, at least as far as symptoms with signs go, with the exception of the sphenoid. As is

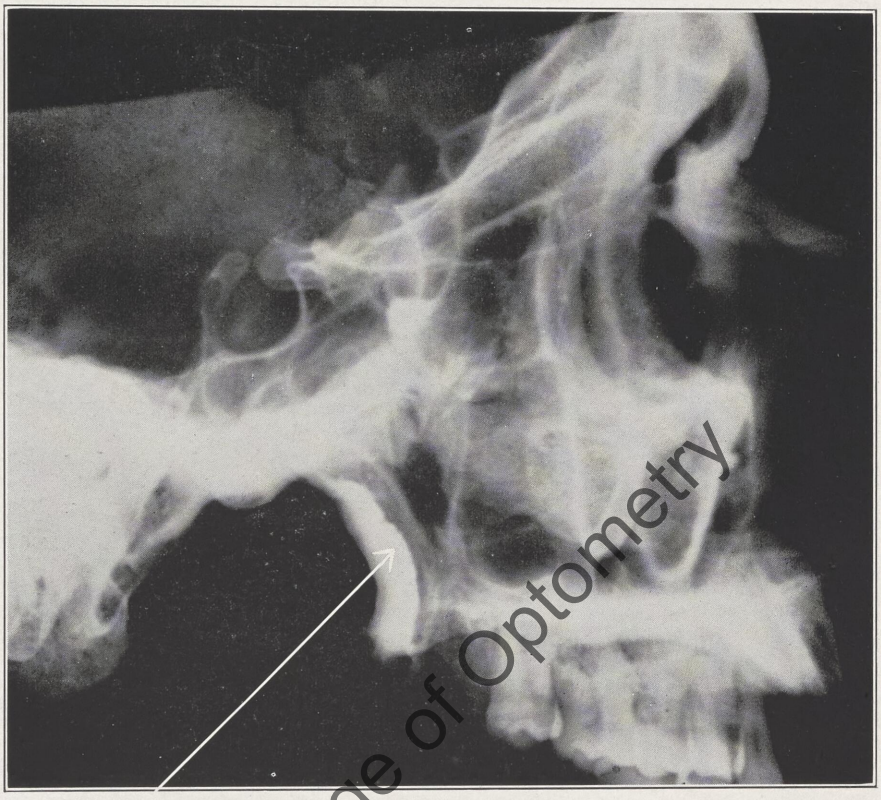

Fig. 102.—Shows lateral view of a dry specimen in which the space between the plates of the pterygoid process has been filled with barium paste.

known to us, it is no uncommon thing to see a sphenoidal empyema give rise not only to its own characteristic symptoms, but to simulate the pains produced by all the other sinuses. Pain of a frontal sinus inflammation may be simulated by a sphenoidal inflammation—the differential diagnosis being made by the absence of pus from the frontal, with no tenderness of its floor—"Ewing's sign"—as well as a negative finding on the

Digitized by Illinois College of Optometry

x-ray picture. Pain of anterior ethmoidal neuralgia may be simulated by a sphenoidal sinus inflammation. Cocainization of the anterior ethmoidal nerve stops this pain but does not influence the pain caused by the sphenoid. (See differential diagnosis.) The pain of a maxillary antrum inflammation may be differentiated by a negative antrum puncture as well as a negative x-ray picture. Absence of pus in or from the ethmoid

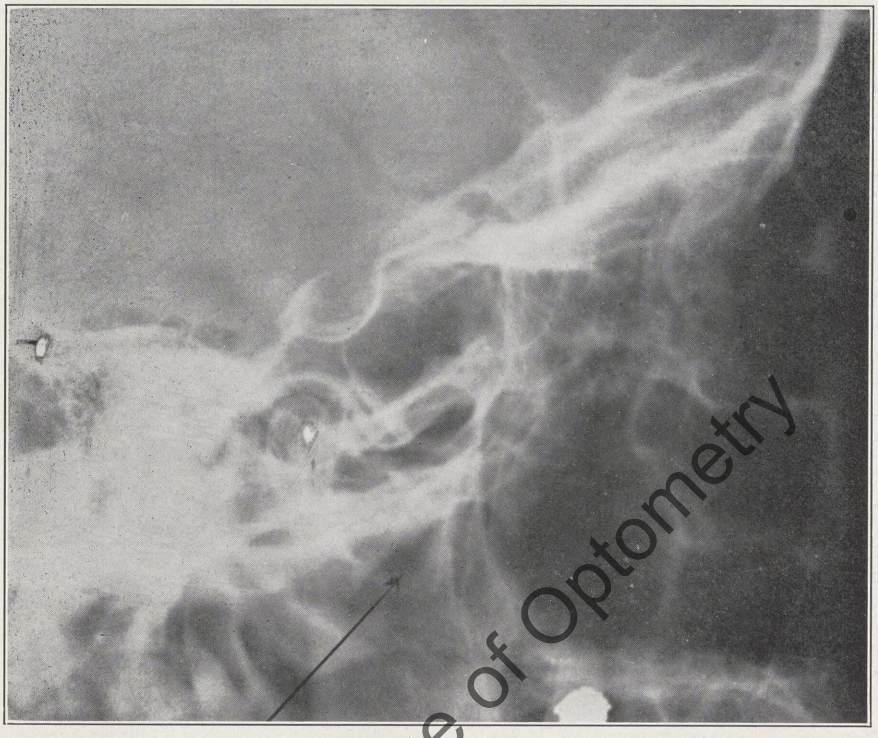

Fig. 103.—Shows the lateral view of a sphenoid which extends downward into the pterygoid process as indicated by the arrow. Lines showing this dipping may be readily recognized on the original plate.

would exclude the ethmoidal cells. These symptoms, when produced by the sphenoid, are, however, more apt to be nocturnal than diurnal.

It seems to me there are two pictures produced by inflammatory disease of the sphenoidal sinus. The primary simple one is that produced by the pressure from an obstructed outflow of pus. I have construed this as the explanation of the somewhat

Digitized by Illinois College of Optometry

"dull," "heavy" pain in the back of the head described by these patients. (Case 103.) The more complex one, simulating the pains which are ordinarily produced by the other sinuses, can only be explained by assuming that the associated nerve trunks have become involved either by the inflammatory process

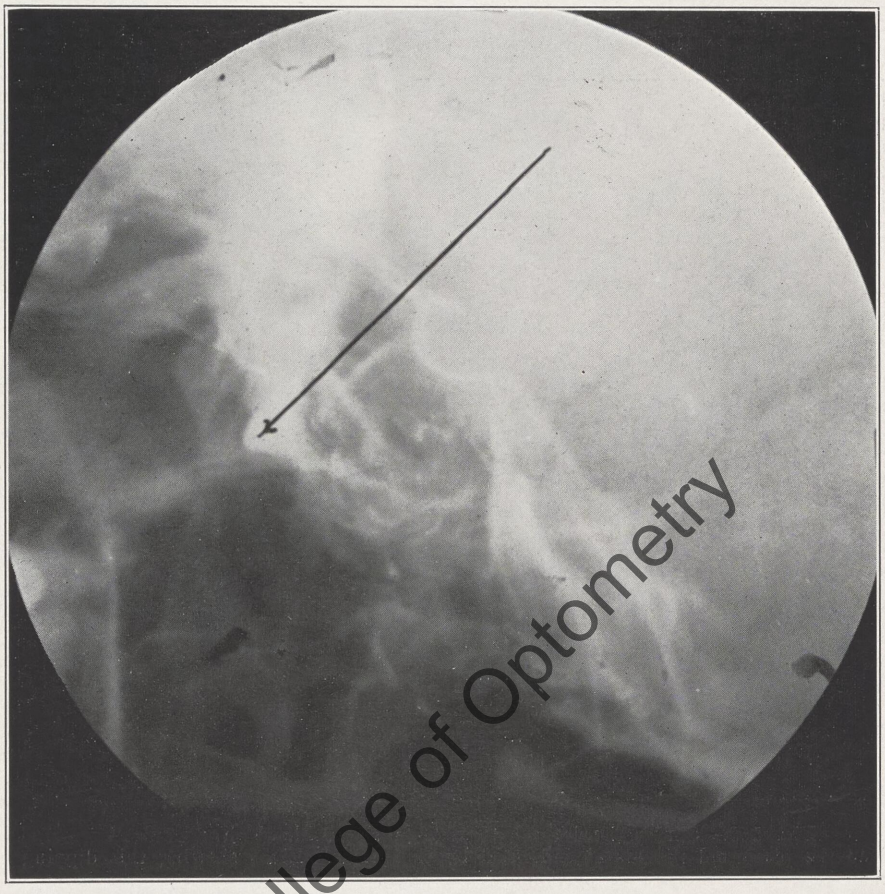

Fig. 104.—The same case as shown in Fig. 103. This sphenoid has been partly filled with iodized oil which is readily seen extending downward into the prolongation into the pterygoid process as shown by the arrow.

or by its toxins. This assumption applied to the third nerve may explain also the dilated pupil seen in some of these cases (74, 75, 76, 77, 94, 95, 96), when the ophthalmologist or neurologist can assign no reason for it; and the asthenopia that is sometimes met with when no reason may be found in the eye or nose,

Digitized by Illinois College of Optometry

otherwise. Some of these cases show a paresis of the superior oblique.

From the above described anatomy, in which the sphenoidal sinus is separated from the nerve trunks by thin divisions of bone, such an extension of inflammation might easily occur. In an effort to prove the accessibility of these nerve trunks I

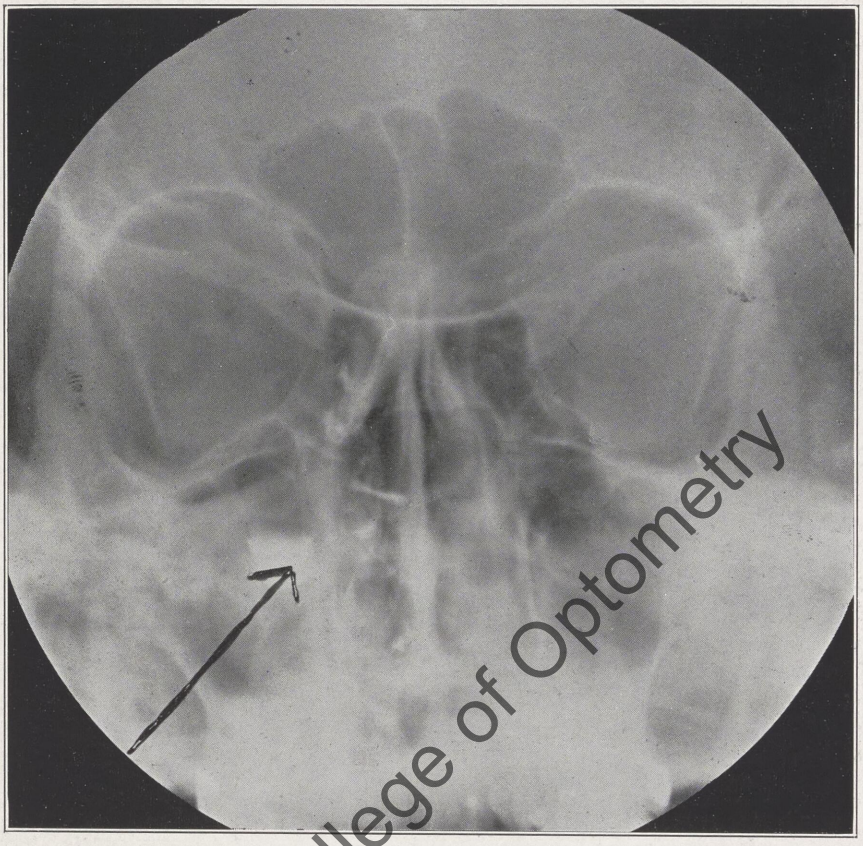

Fig. 105.—Shows anteroposterior view of Fig. 104. The iodized oil in the pterygoid process is readily recognized as shown by the arrow.

have often painted the cavity of the sphenoid in a stripe from above downward and outward with a very small applicator bearing about one-half to one drop saturated watery solution of cocaine (90%) and paralyzed one or all three divisions of the fifth for tactile sensation and pain, accompanied by a marked sense of stiffness of the lower jaw on that side. (Case 17.) A

Digitized by Illinois College of Optometry

needle could be passed through the skin supplied by these nerves and fail to evoke sensation. In these cases the separating wall must have been a very thin one, thereby permitting the cocaine to pass quickly and easily through to the nerve trunks. I have also, for therapeutic purposes, filled the sphenoid with oil so-

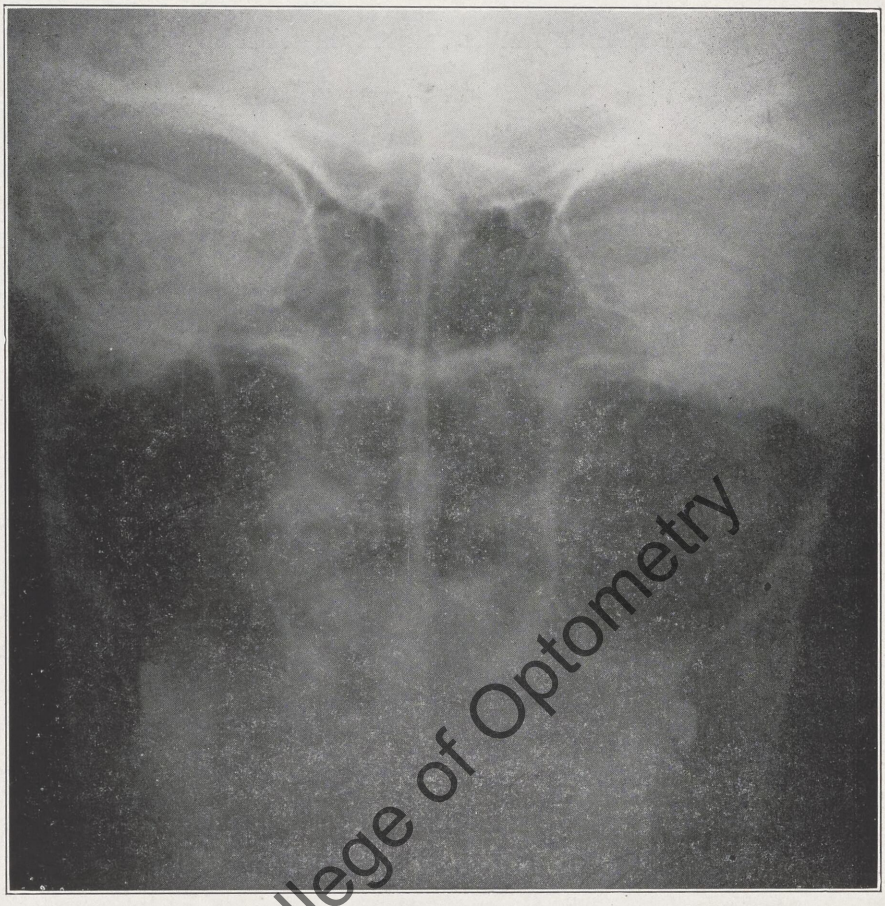

Fig. 106.—Shows the same case as Fig. 105 without the iodized oil. No mark in this picture reveals the prolongation to the pterygoid.

lutions—1 per cent phenol, 2 per cent menthol, 5 per cent and 10 per cent oil of wintergreen and 1 per cent cocaine alkaloid—and found that they all produce a well-defined analgesia of the second and sometimes the first and the third divisions of the fifth, accompanied by very little or no tactile anesthesia. It

Digitized by Illinois College of Optometry

therefore seems to me reasonable to assume, when the diagnosis is sphenoidal empyema and the symptom is pain in the brow, that it is inflammation or irritation of the first division of the fifth by the process within the sinus which causes this symptom. When the symptom is pain in the upper jaw and teeth, or temple, it seems reasonable to assume the second division of the fifth has become involved. When the symptom is pain in the

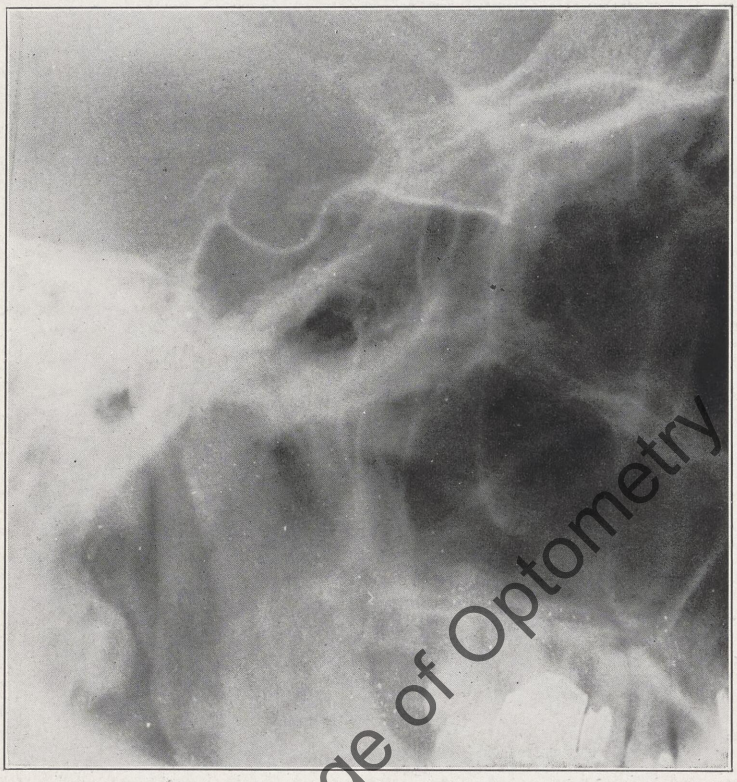

Fig. 107.—Shows an ordinary lateral view of a large sphenoid. It is one without any especial significance, often seen in the routine of practice.

lower jaw and teeth, accompanied by a sense of stiffness in the jaw on that side, it may be assumed that the third division has become involved and probably in the foramen ovale. (Cases 18, 19, 20, 21.)

In rare cases of post-ethmoiditis in which the cells extend to the roof of the orbit the pain extends to the eye and temporal region and is most severe and intense. These cases are difficult

Digitized by Illinois College of Optometry

to manage because the cells cannot be reached surgically; indeed, it was very difficult to identify them with the x-ray.

The behavior of certain sphenoidal empyemata has interested me much for several years. These are cases in which the pains and aches have continued unchanged, despite wide open-

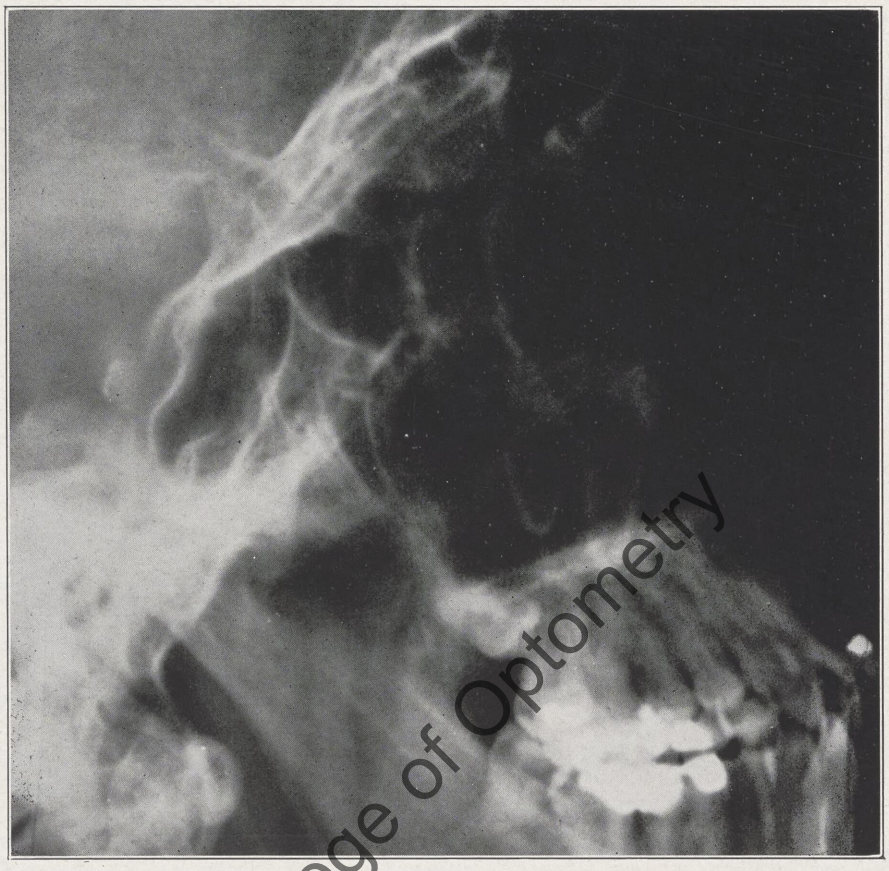

Fig. 108.—Shows the lateral view of a sphenoid which extends downward and backward. It has no especial significance.

ing of the cavities and cessation of all pus or signs of local disease. It is my habit to perform a radical post-ethmoidal-sphenoidal operation (see page 246). It seems to me the most comprehensive treatment. Some of these cases, however, although recovering from the suppurative inflammation, and later from all signs and symptoms, have frequently subsequently de-

Digitized by Illinois College of Optometry

veloped headache and behaved as cases of vulgar migraine. Dr. M. A. Bliss has seen a number of these cases in consultation, and has sent some of them to me and has agreed in the diagnosis of migraine. I have felt that in this class of cases which have simulated and borne the name of migraine, the origin of the pain was a local one. These are of similar symp-

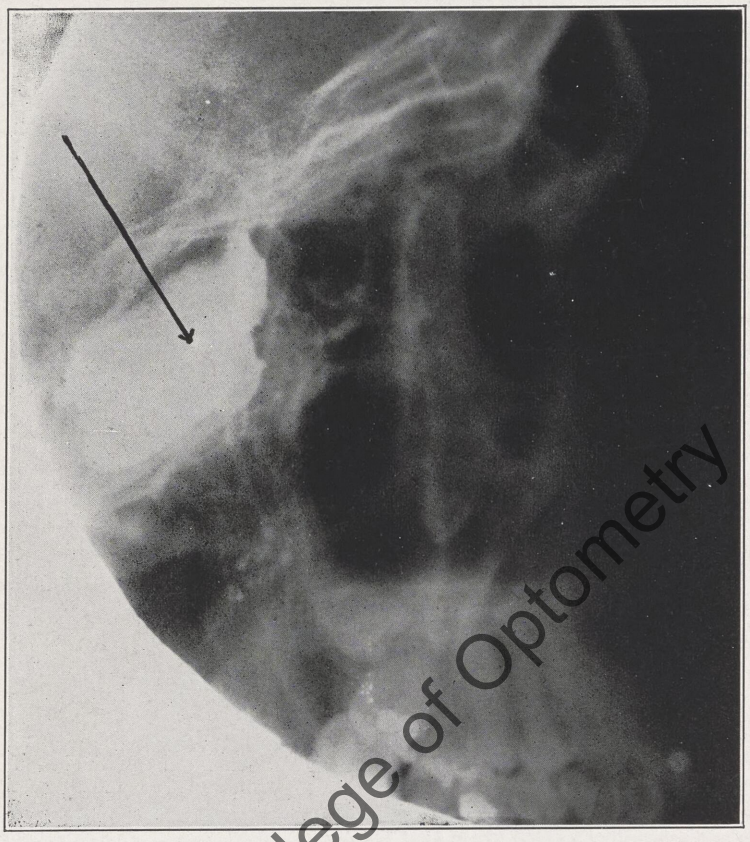

Fig. 109.—The same sphenoid as that shown in Fig. 108 filled with iodized oil as indicated by the arrow.

tom-complex to those of toxic origin. The distribution of the pain has been that suggesting as its origin the first division of the fifth, as well as the second division, sometimes, or the third division, and combined at times with the posterior pain, which I have attributed to the irritation of the Vidian. In 1913[13] I mentioned that in the injection of the nasal ganglion with

Digitized by Illinois College of Optometry

alcohol, when the needle was placed too far internal, the pain produced by the alcohol was projected backward and into the shoulder, etc., and when placed too far external the pain was referred to the upper jaw; that is, when the side of the ganglion upon which the Vidian enters was injected, the pain was referred posteriorly, whereas with the side upon which the second division entered, the pain was referred to the upper jaw. When the alcohol was placed in the ganglion direct, the pain was referred in both directions. The relative position of the

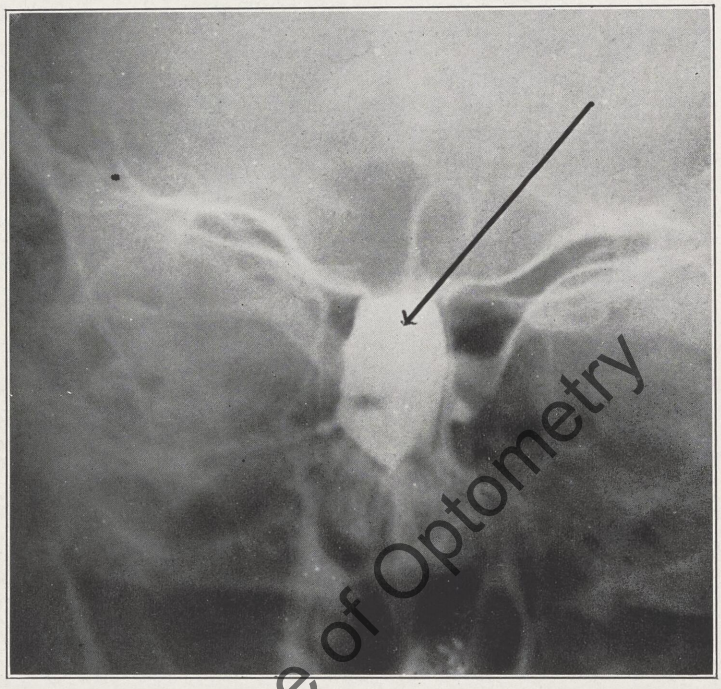

Fig. 110.—Same case as Fig. 109, anteroposterior view of sphenoid filled with iodized oil.

Vidian and second division of the fifth is shown in Fig. 55, which portrays the foramina through which they pass at these points. Faradic stimulation of the Vidian produces pain in the ear, mastoid, neck, shoulder, etc. (See Chapter IV.)

These cases of recent origin (three to six months approximately) when well of the suppuration, were usually well of all symptoms and remained so until a coryza infected the general nasal cavity, when they again developed their pains, often with-

Digitized by Illinois College of Optometry

out suppuration of the sphenoidal and post-ethmoidal cells. The membrane of the sphenoidal sinus, however, usually showed under these circumstances a red swollen, or edematous condition (even polypoid) analogous to that shown by the anterior ethmoidal region in hyperplastic ethmoiditis under similar inflammatory influences; that is, clinically it was hyperplastic sphenoiditis. In the recovery the swelling and edema would subside, but more or less of the pain would continue, and at a time later begin a cyclical reappearance, with no visible disturbance in the sphenoidal sinus, even when its anterior wall had a permanent opening in it large enough to permit a good view of its interior. I did not, however, at this time employ Holmes' nasopharyngoscope. Use of this instrument later showed that patches of inflammation within the sinus were usually discoverable on the floor or lower lateral part of its walls. (Case 73.) The Vidian canal with the Vidian nerve is on the floor, and the foramen rotundum, containing the maxillary nerve is at the lower lateral anterior part of the body of the sphenoid. I have observed a similar behavior of the nasal ganglion; i. e., intermittent reappearance of the neuralgia usually with an inflamed spot at the sphenopalatine foramen. I have also observed in these sphenoidal cases a picture identical with the neuralgic and sympathetic phenomena which start in the nasal ganglion. This is not surprising; on the contrary, it would be expected after one has proved the accessibility of these nerve trunks. The entire nerve supply of that ganglion, to wit, the second division of the fifth and the Vidian nerve, being so closely associated with the sphenoidal sinus, the picture of the ganglion neuralgia and sympathetic phenomena are readily reproduced under inflammatory conditions within the sinus. *The differential diagnosis* is made by the facts that cocainization of the ganglion *stops* the pain and sympathetic phenomena when they originate in the *ganglion,* but *fails* to stop them when they originate in the *sphenoid,* because the ganglion is peripheral to that point of origin; and that cocaine solution applied within the sphenoidal sinus does stop the pain, etc. In the case of ganglion neuralgia, etc., the membrane covering the sphenopalatine foramen is usually but not always, congested and thick-

Digitized by Illinois College of Optometry

ened. This appearance may be absent in the case where the pain is started in the nerve trunks from within the sinus.

I have seen this class of sphenoidal cases behave as vasomotor rhinitis or rhinorrhea or "hay fever," as the patients call that form of paroxysmal sneezing, accompanied by profuse watery discharge and by asthma. In these cases all therapeutic measures applied peripherally (intranasal) were of no avail. They yielded to intrasphenoidal applications.

In the observation of these cases I am led to the belief that a large number of the frequently recurring headaches, of whatever length of time standing, that usually bear the name "migraine," that are met with in the general practice of medicine, that have defied diagnosis and treatment, are sphenoidal inflammations existent, or were started as such. The nasal ganglion must be included here (see Cases 61, 62, 63, 64, 65, 66, 67). They may have lost all the evidences of local disease, which some months or years before were easily recognizable. I believe that the sensory and involuntary nerve trunks have become diseased from juxtaposition, just as is known in the case of the optic nerve. Disease of the nerve trunks under these circumstances is in no wise different in its clinical behavior from that which is started further toward the periphery, as for instance, from an antrum of Highmore suppuration or a diseased tooth, which after the cure of the local disorder continues painful at intervals or becomes a tic douloureux. The second division of the fifth nerve in the foramen rotundum is in as close association with the sphenoidal sinus as is the optic nerve in the optic canal, and under identical setting, namely, surrounded completely by a firm, bony ring. This is true of the third division of the fifth nerve also; but it is not, as a rule, so closely associated with the sphenoidal sinus. Optic nerve disease, secondary to the sinus disease, is too well known and proved to require argument here. I see no reason why we may not assume as much for the other nerve trunks in close association with these sinuses, with the difference between the types of nerves. This sphnoidal area being central to the place of injection of alcohol into the branches of the fifth nerve, from under the zygoma, may explain some of the cases that have not been relieved by that treatment. Also, for the same reason can we understand that when the semilunar

Digitized by Illinois College of Optometry

ganglion has become involved and gives rise to the pain, intrasphenoidal applications will fail to give relief.

At this time it is pertinent to mention the following three observations which may be spoken of as anatomical, pathological and clinical. In 1907 Uffenorde[2] demonstrated a microscopic vein communicating below the sphenoidal sinus and the optic nerve. In 1913 de Kleign and Gerlach demonstrated an encapsulated diplococcus in the mucous membrane lining the sphenoid. It was demonstrated passing through the bone into the optic canal, into the optic nerve and forward into the globe. In 1915 I saw a lesion on the optic canal by means of Holmes' pharyngoscope. This was a severe case of serous iritis with hemorrhages into the vitreous. A rather dark gray lesion, about 1 cm. in diameter, with veins running to a center point on a thick mucous membrane appeared (Case No. 73).

In the discussion of Joseph D. Heitger's paper on eye lesions of nasal origin E. H. Cary refers to a personal observation of a case in which the patient had enlarged pupils, loss of accommodation and iritis. Upon examination of the nose it was impossible to determine the presence of any pathology in the sinuses. The patient died of meningitis and autopsy showed an encapsulated abscess within the sphenoid. The third nerve passed beneath the second and there was enough involvement of the bone to affect the third nerve. The third nerve paralysis and the streptococcus meningitis were accounted for by the sphenoidal infection.

The involvement of the nerve trunks in the sphenoidal district producing the sneezing explains why the injection of the branches in the neighborhood of the sphenopalatine foramen (Stein[3]), combined with the same treatment of the anterior nerves, has failed to influence the sneezing in some cases, the sphenoidal area being central to the other nerves.

It appears that whatever may be the lesion of the nerves, it is rather easily remediable in its earlier stages by intrasphenoidal medication. The worst cases by sedulous treatment may be greatly improved, if not cured, in a very large percentage of cases.

I have not thus far been able to secure any post-mortem material bearing on the above question. This happens because

Digitized by Illinois College of Optometry

we as rhinologists are apt to see the patient only while he is in good general health. Later in life when his general health fails he seeks the help of the internist and dies in his charge unknown to us. We learn of his death only some time later. In the public hospitals the chief obstacle to securing this material is the antagonism of the undertakers to any form of autopsy. They seem, somehow, to be able to accomplish this.

That the cavernous sinuses may become infected and thrombotic, secondary to sphenoidal infection, is well known. In these considerations the cavernous sinus, however, plays only an anatomical part.

I have stated in the records of some of these cases that they behave as a hyperplastic ethmoiditis, and that some did not. So far as I have been able to learn, there is no post-mortem histological proof of a hyperplastic process in the sphenoid such as has been proved in the ethmoid. Clinically it exists.

Hyperplastic disease in the nose involves not only the bone but the soft parts covering it, in the nose and in the paranasal cells, as shown often at the time of operation by polyps within the cells. Whether such changes ever occur on the orbital side of the ethmoid or maxillary antrum or the dural side of the sinuses, is a question I have not as yet been able to solve. A case reported by W. B. Chamberlain indicates that polyps may form in the cranium.

The conclusions here recorded are the results of examinations of bone removed from 185 such cases in my own practice; I have been assisted by Dr. Jonathan Wright's examinations and conclusions regarding the microscopic changes in them.

The clinical diagnosis of hyperplastic sphenoiditis was confirmed by Dr. Wright from the examination of the anterior and inferior sphenoidal walls removed from these cases. Furthermore, Dr. Wright's conclusions passed upon the bone sections from these cases, whose histories were unknown to him, corresponded so closely with their history before and after operation as to be very striking. The list comprises those operated upon for suppuration of longer or shorter standing without other symptoms, which I feel should be classed as the simplest cases; and others operated for pus with more or less headache

Digitized by Illinois College of Optometry

and of longer (six months) or shorter (two months) standing which were mild cases; and others for acute exacerbation with suppuration and others for acute ocular involvement and some totally blind with little or no disc changes; some with transitory amblyopia; some with simple choroiditis, and others of this class with ocular palsies also, third, fourth, and sixth nerves, which are of the type of ophthalmoplegic "megrim"; others of many months, or years, standing without pus, with slight disc swelling slowly increasing with a narrowing visual field; some with choroidal hemorrhages and total clouding of the uveal media; some serous iritis and cyclitis and anterior chamber hemorrhages, others without pus but with sensory (fifth) trunk involvements (hypaesthesia) and recurrent headache of the (severe) vulgar migraine type, with and without pallor (sympathetic migraine); one recurrent headache with loss of consciousness, of ten years' standing of the type of epileptic migraine; sixteen with ophthalmic migraine, complete pictures of all grades, four with severe headache and hallucinations, the type of psychical migraine, and eight major epilepsies (one cured 18 years). (See Case Histories.) Most were uncomplicated by systemic conditions. Some, however, occurred in the course of nephritis and a number in arteriosclerosis and high blood pressure, and some with arthritis deformans; some with severe digestive disorders and some in syphilities. All systemic conditions seemed to have so little influence on the local conditions as to be negligible. The length of time over which these cases have been observed varies from twenty months to twenty-five years.

Intrasphenoidal observation with Holmes' nasopharyngoscope (C. H. Gundelach) after the anterior wall was removed has shown thickening of the membrane, sometimes a marked sclerotic state and often localized inflammation, and sometimes polyps or cysts within the sinus, and sometimes vessels entering and leaving the sinuses through that part of the wall which makes up the optic canal (Case 73.) Furthermore, the configuration of the sinus can often be made out accurately, especially the most important parts. These are more or less at a right angle to the shaft of the instrument, which is the direction in which the prism looks; e. g., the regions of the optic canal, foramen rotun-

Digitized by Illinois College of Optometry

dum and Vidian canal. As the instrument is now constructed it has the defect that it cannot look forward or backward more than its 60° visual angle (30° to each side of the perpendicular) and requires a cell 12 mm. front to back, to contain its light and prism, as Dr. Gundelach has stated. It has, however, been of much help in the understanding of these cases as well as determining the comprehensiveness of my post-ethmoidal-sphenoidal operation. By these means I have been able to confirm the diagnosis of hyperplastic sphenoiditis by intrasphenoidal observation and to learn that the process is *not always universal,* and that the exacerbations which may take place in this district from coryzas *may be localized;* and that according to their *position* they may be more or less *pernicious or disastrous;* e. g., when localized about the *optic canal* they may impair vision *without other symptoms;* or when localized on the *lower latter aspect* of the sinus they may cause *maxillary* neuralgia; or on the floor they may give rise to *Vidian* neuralgia of any grade. I use the term "Vidian neuralgia" to express pain in the ear, mastoid, occiput, neck, shoulder blade, shoulder, arm, forearm and hand because I found by experiments upon the nasal ganglion that it could be produced by the faradic current attached to the needle when *in situ* for injection of the ganglion and that it could be produced separately from the anterior or maxillary part of the symptom-complex (pain in the teeth, eye and temple), by inserting the needle into the Vidian on the internal side of the ganglion. The depressing peculiarity of this pain has been emphasized by M. A. Bliss. Marked anaphrodisic power has been ascribed to it by some patients.

This observation has also been made by R. H. Skillern in connection with paranasal cell disease.

In considering hyperplastic sphenoiditis as a pathological process with the part it plays clinically, I feel that, primarily, attention should be called to the anatomy of these parts, as recorded above. The relations of the optic canal with the contained optic nerve, to that cell are at once important and striking and have been remarked about by many observers, notably Emil Berger; and latterly emphasized by A. Onodi, and again by H. W. Loeb,[1] who has furnished us with the best pictures

Digitized by Illinois College of Optometry

I have seen of that district and its variations. His observations have recently been confirmed by S. B. Westlake.

Attention to the *anatomical* relations of the sphenoidal cell to the foramen rotundum containing the maxillary nerve, and the foramen ovale containing the mandibular nerve, and Vidian canal containing the Vidian nerve, as well as the clinical importance of these relations was directed for the first time in my above cited text.[27] Those anatomical observations were confirmed by Ladislaus Onodi,[2] working by a different method. Our results were published May 11, 1912 (Sluder[27]), and July 10, 1912 (Onodi[2]), respectively, except for the Vidian nerve, which he did not at that time consider as I remarked above. Later he confirmed the Vidian relations. Dr. Onodi in this latter text[1] refers to my observations.[18, 27] He has, however, made mistakes possibly explicable by differences of language, which require correction; i. e., the text (Sluder[27]) was not a "lecture" but presented as an official communication to the American Laryngological Association at its Thirty-fourth Annual Meeting, held in Atlantic City, N. J., May 9 to 11, 1912. The presentation was accompanied by the drawings which were published with the text as well as the specimens from which the drawings were made, no mention of which has hitherto seemed to serve a purpose. In his citation of the other text (Sluder[18]) he has made a mistake as to whose researches are recorded in that text. The determination of the age at which the sphenoidal sinus reaches close relations to the foramen rotundum with the maxillary nerve and Vidian canal with the Vidian nerve was made by me and not by Dr. Davis. Through personal favor Warren B. Davis allowed me to examine his matchless collection of Caucasian specimens with the understanding that I might enjoy the privilege of recording my observations, giving him credit for the material. At that time Dr. Davis was not interested in the foramina and canals or nerve-trunk relations to the body of the sphenoid. His desire was to contribute to anatomy a full and accurate knowledge of the "Development and Anatomy of the Nasal Accessory Sinuses in Man" (to quote the title of his monograph, 1914), and he did this with a completeness and an accuracy that surpassed all description or portrayal extant. And so it was that he had

Digitized by Illinois College of Optometry

definitely determined the beginning and the manner of the development of the sphenoidal sinus, but he was not concerned with its approach to the foramen rotundum or the Vidian canal, nor did he realize any clinical significance or importance in those relations. I attempted to make this clear in my text. In addition to differences in the languages (which make mistakes very easy) these points might have been brought forth with greater emphasis, which did not, however, seem to me, at the time to be necessary.

The statement is made in Dr. Onodi's text that his observations were first published in "Orvosi Hetilap," March 24, 1912. Perusal of that journal shows his text to have been published November 3, 1912.

Dr. Onodi and I made some similar observations. Mine were made as a necessary chapter—the applied anatomy—in a very difficult and complex clinical problem. The question of the adjacent foramina and canals was at that time a matter of importance and record for me and has grown constantly more important. I do not, however, regard the nerve contacts with decreasing importance. Dr. Onodi's method was to follow the nerve trunks in their courses and when found in contact with the bone to measure the lengths of such contacts and note the thickness of the bone separating the trunks from the sphenoidal sinus, and I believe this to be very valuable contribution to our knowledge of this district. He did not consider the foramina or canals or the part played by the cavernous sinus in determining the contacts. I, too, had tried that method, but in my hands it was less satisfactory than the method by serial cross section of this district, using material carefully hardened in formaldehyde and decalcified in dilute hydrochloric acid. Such material may be sectioned with a good knife, as thin as 1.5 mm., or even 1 mm. when desired. These sections when examined with magnifying glasses were most satisfactory. The macerated bones, too, in some instances were advantageous. The cross sections have the advantage that they determine all contacts most accurately as well as the relations of the foramina and canals and the thickness of the separating bone. They also give an estimate of the amount of fat or connective tissue surrounding the nerves in the foramina and canals.

Digitized by Illinois College of Optometry

The subject of migraine is so large that a bibliographic presentation of it is a gigantic task that would give no conclusion in regard to its association with the nose (hyperplastic sphenoiditis). There is only one way this can be settled; neurologists must have these patients examined by rhinologists capable of passing judgment upon these questions.

It is to be remembered that migraine has been recognized since 20 A. D. and that modern rhinology dates from the discovery of cocaine, 1885 (?).

Wonderful descriptions of migraine exist, but patients suffering with this malady until very recently did not have the advantage of advanced rhinological consultation. We may still hope and expect rhinology to help clear up the etiology of the many cases of veritable migraine.

Arthur M. Alden has reported a group of two cases and has referred to two cases from the literature of psychosis associated with disease of the nasal accessory sinuses. The patients were operated upon, with recovery. In one of his cases the maxillary sinus was affected with suppuration, associated with involvement of the bone of the upper jaw. In the other case the antrum and frontal sinus were involved. In one of the cases reported from the literature the frontal sinus was diseased, and in the other the post-ethmoidal and sphenoidal sinuses were diseased. In Hajek's[2] text on the *Pathology and Treatment of the Suppurative Diseases of the Nasal Accessory Sinuses* he goes into great detail on the relation of psychoses and depressive conditions to suppuration of the sinuses.

Clarence Ide has also reported a case of psychosis resulting from the toxins of chronic maxillary sinusitis, coupled with left hyperphoria of 8½ per cent.

In my text,[27] hyperplastic sphenoiditis was referred to as being in my opinion the lesion underlying many of the recurrent headaches, in healthy people, which at present bear the name "migraine." I spoke of this class of cases again at the meeting of the American Laryngological Association in 1913 and again at its 1914 meeting, explaining some of its features. Its (hyperplastic sphenoiditis) very great importance in the life of the patient and its far-reaching pernicious possibilities were not, however, so clearly impressed upon me then

Digitized by Illinois College of Optometry

(1912) as now. At that time I thought that many of the cases, if not all, were explained by the *inflammatory* process either extending *through* or *transmitting* its *toxins through* the thin bone walls to the adjacent nerve trunks because I had *proved* that *cocaine* readily *passed through* from the *sphenoidal sinus* to the *nerve trunks*. But within the past few years, as a result of a much wider clinical experience, I have come to feel that there are probably several factors contributing to the clinical picture, those being two of them, and that a third and probably much more serious one is the bone change in the hyperplastic process with or without periostitis. The bone change, however, required the proof which Dr. Wright has supplied. It would seem that such material ought to be obtainable post-mortem, but so far that has not been my experience. My ideas therefore have of necessity been formed by the association of some facts with an inductive philosophy. In this connection it might be argued that the condition of the anterior wall of the sphenoidal cell (which must include its post-ethmoidal face) is not a criterion for the remaining part of the body, and that conclusions drawn from that material dare not be generalized for that district. Holmes' nasopharyngoscope is an aid which permits of much conclusive observation. By it we find that the hyperplastic process is *not* always uniformly distributed within the cell. It may be distributed irregularly but is usually more marked in the lower half of the cell.

Hyperplastic anterior ethmoiditis may sometimes precede a like change in the post-ethmoidal-sphenoidal district; and it was from such cases that I began to form the ideas embodied in this text. I have observed some of them for twenty-six years. The first clinical effect in such a case is the closure of the frontal sinus, the outlet of which, aside from being in the district where the process so readily begins because of the direct blast of inspired air with its dust and bacteria, lends itself easily to clinical manifestations because of its being narrow usually at some point if not in much of its length; and therefore easily closed. The fact pointed out by Uffenorde[2] that the submucous connective tissue on the lateral aspect of the middle turbinate and internal ethmoidal wall is loose, also readily contributes to the clinical picture. These facts account for the

Digitized by Illinois College of Optometry

(nonsuppurative) cases which Ewing and I described in 1900.[2] A part of the air within the cell is then absorbed, resulting in a negative pressure and headache accompanied by Ewing's sign (a tender point at the upper inner front of the orbit) and asthenopia. The closure may also be brought about by other causes, irrelevant to the argument here, a detailed enumeration of which with differential diagnosis may be found in Chapter III. The pathological state bearing upon the questions here in hand, is that in which the tissues of the middle meatus become hyperplastic. In these cases the membrane *readily* becomes *edematous,* and *coryzas* cause *polyps,* which in the *early* history of the case *disappear* with the subsidence of the *acute* conditions; *later* as the bone becomes more *hyperplastic* the polyps remain permanent. It has been my habit to remove the middle turbinate in such cases by an incision placed about 2 mm. below the cribriform plate. This gives, in usual skulls, a funnel-shaped outlet to the frontal sinus, apex down formed by the uncinate process in front and the ethmoid bulla behind and below, the lower part being the hiatus semilunaris, measuring normally 1 to 2 mm., expanding to 5 mm. above, anteroposteriorly, and 2 to 4 mm., laterally. These anatomical details are elaborated in Chapter III. The immediate result of such surgery is a wide opening of the frontal sinus into the nose and a cessation of all symptoms for five to ten years (or longer). The patient then returns for treatment at the time of a coryza, because of slight headache and asthenopia, which he is anxious about from previous experience. The rhinologist finds the outlet or inlet of the frontal sinus closed, but as the swollen membrane *shrinks* he finds that the *symptoms subside* and that the outlet or inlet is then open, but *smaller* than it *was.* As the years pass he finds that the uncinate thickens a little, but that the bulla enlarges more and the outlet or inlet of the frontal sinus becomes smaller and *finally closes again* and the *original headache, etc., syndrome is reestablished without pus.* The tissues from such cases were examined by Dr. Wright and found to show the changes of hyperplastic ethmoiditis. The picture in the nose shows the macroscopic changes to correspond and to be extending *backward;* and later (without pus) the pain of maxillary and Vidian nerve involvement, that is, pain around

Digitized by Illinois College of Optometry

the eye and in the upper jaw and temple, with pain in the occiput and neck, etc., is added as the process in the bone extends backward; and polyps begin to form *above* the middle turbinate line at the time of a coryza. At first they disappear with recovery from the coryza; *later* they become *permanent.* In the progress (development) of the bone disorder *backward,* the maxillary and Vidian headaches appear *only* at the time of coryza. Later, however, they recur at longer or shorter intervals in more or less severity *without visible local changes* and continue to do so *indefinitely* with the neurologist's diagnosis *"migraine."* (I have seen such headaches of forty years' standing very greatly relieved by the sphenoidal operation. They cannot be cured by operation if the pathological mechanism is correct in its idea.) The same clinical picture is produced by irritation of the nasal ganglion, but this may be differentiated by the fact that the nasal ganglion pain can be stopped by cocainization of the ganglion, whereas the pain caused by the sphenoid in the nerve trunks, central to this, cannot be stopped that way. (See Chapter V.)

Optic nerve disorders arise *often,* secondary to hyperplastic bone change of the spheno-post-ethmoidal district. A large percentage are preceded by those headaches—often for *many* years. In some cases there is a slow encroachment upon the optic nerve, as shown by slight swelling of the margin of the disc, which increases slowly with gradually failing vision. This may be a process of years. Adamkowitz found that slow compression of nerves destroys function slowly. In other cases the eye becomes quickly blind with or without changes in the disc. Some patients have a transitory amblyopia. Some show muscle imbalance, probably because of discomfort arising from the attachment to inflamed bone at the apex of the orbit. Some show hyperesthesia and hypalgesia over the maxillary distribution of the fifth nerve.

The *explanation* of the headaches and optic disorders in such cases, I believe, is hyperplastic bone process and that its mode of operation is to *narrow the bone canals* through which the respective nerves pass; i. e., the optic canal with the optic nerve, the foramen rotundum transmitting the maxillary nerve, the Vidian canal with the Vidian nerve. The foramen ovale with

Digitized by Illinois College of Optometry

the mandibular nerve only rarely comes into these considerations because it is usually far enough removed from the sphenoidal cell to be exempt as a clinical factor. (It does, however, sometimes become a part of these pictures.) This seems to me a reasonable deduction from Dr. Wright's findings in the wall of the sphenoid in conjunction with intrasphenoidal (pharyngoscope) observation, together with the easily seen behavior of the process on the lateral wall anteriorly, where the frontal outlet may be seen narrowing from year to year. It may here be urged that the intranasal observation was made in a part *exposed* to the atmospheric air and that the foramina and canals mentioned are not so exposed; and that the frontal outlet being empty offers no resistance to encroachment whereas the foramina and canals are snugly filled and would offer some, if not considerable resistance; and that the osteoblasts are active only on convexities. I have, however, seen the uncinate process become markedly thickened and enlarged in its *concavity* in the progress of hyperplastic anterior ethmoiditis (also observed by Uffenorde[2]). And it may be argued that the lesion in the foramina and canals is probably a periostitis, which is, judging from the removed bone, probably true in some cases, but not all, by any means; whereas the hyperplastic bone change was constant for this class of cases and extended through the depths of the tissues. In other words, it was not limited to the part exposed to the air and was irregularly accompanied by periostitis. Dr. Wright and I believe that the process begins as a surface tissue change, and proceeds to the periosteal layers and bone. But the sections show that the surface and periosteum may recover and the deeper changes go on.

The canals in the skulls of present-day children have often seemed to me larger than those of the present-day adult.

This, however, is a difficult point to determine and may very readily be only apparent and not real. In truth it would seem that in the National Museum, Washington, the privileges of which were kindly permitted by Dr. Ales Hrdlicka, the director, in specimens of the skulls of aboriginal American Indians this is probably not the fact. Sir Arthur Keith's observations argue against anatomical change being possible in a few thousand years. Larger canals would explain why

Digitized by Illinois College of Optometry

these headaches and optic nerve troubles do not begin more often in childhood. I have, however, seen the headaches at the age of three and seven years and the eye trouble at six years. It is easily conceivable that a small space around each nerve is left more or less filled with fat or loose connective tissue. This tissue would be easily compressible in the foramina and canals and might allow for or accommodate a congestion rising from whatever of many causes; e. g., a digestive or other systemic toxemia or the mechanical gravity congestion produced by making the head the lowermost instead of the uppermost part of the body (in other words, when the head is turned downward in any considerable degree). If the narrowing of the canal or foramen is merely enough to take up this small space, it will, it seems to me, place that nerve in a vulnerable position, which explains some of the phenomena of these cases, namely, pain established instantly by bending the head down or by coughing or sneezing in which the peripheral blood pressure is suddenly raised; and sudden transitory amblyopia. Further encroachment on their caliber would explain the slowly progressive optic nerve cases and the more protracted severe headaches.

Leon E. White[1, 2, 3, 4, 5] has recently published several observations on the size of the optic canal with reference to optic lesions of nasal origin. By x-ray pictures he has found that the optic canal on the affected side is smaller. He thinks it is congenital and a determining factor in subsequent eye lesions of nasal origin, which may be true. One may, however, think that the size of the optic canal is determined by the size of the optic nerve, just as the size of the brain cavity is determined by the size of the brain. In a recent conversation with Dr. F. K. Hansel concerning this point he suggested that the size of the foramina for the other cranial nerves is not a clinical factor. This recalls that I have many times noted the large and small size of the foramen rotundum. No history was known, however, of the specimens examined.

If one may be permitted to think of the hyperplastic lesion in this region narrowing the Vidian canal and the foramen rotundum one may also be permitted to think of this process narrowing the optic canal and this process may also be thought

Digitized by Illinois College of Optometry

of as a factor in the development of the optic lesion. Here, again, one realizes the need of post-mortem material to determine the facts.

In the observations of H. A. Goalwin on the optic canal in normal and deformed skulls he states that the canal reaches its full length and breadth at three years of age. If this is true it is obvious that the growth of the skull dependent upon the growth of the brain is probably incorrect. It is, moreover, difficult to understand how the size of the optic canal, which matures at the age of three years, can be a factor in nerve lesions 20 or 40 years later as suggested by White.[2]

If now it be conceded that hyperplastic bone process can and does narrow the bony foramina and canals adjacent to the sphenoidal sinus, and that the narrowing is the cause of the pain in all the contained nerves except the optic; and that the optic also suffers according to the degree and rapidity of the pathological process—we have also the explanation of why maxillary and Vidian pains are so very much the more frequent symptoms, because the lower part of the sphenoidal sinus where the canals run which transmit those nerves is most often affected, and the factor of secretions and their toxicity plays here in addition to what may be the process in the bone. They remain in the lower part. Next in order of frequency is affection of the optic nerve. That this, however, is less frequent than the maxillary and Vidian lesions is probably likewise a matter of drainage, it being higher and forward in the sinus. The wall of the optic canal cannot as a rule be submerged in secretion in any position in which the head may be placed unless the ostium sphenoidale is closed. In the erect posture the sinus will overflow ere this is reached. The only positions of the usual skull making the optic canal dependent is face downward, and that again would fail because the ostium would be placed below and drain the cavity, or possibly lying on that side of the head; i. e., left side for left optic canal, with considerable secretion contained in the sinus. H. W. Loeb[1] has shown that the ostium is usually midway between the roof and floor of the sinus.

The optic canal would seem to be almost of necessity a

Digitized by Illinois College of Optometry

later involvement, by bone extension; or *localized inflammatory* areas from a coryza.

In contradistinction to the clinical lesions of these nerves in bony confines, are such lesions of the nerves in the soft (loose) confines of the sphenoidal fissure; to wit, the oculomotor, trochlear, ophthalmic, and abducent nerves, although these nerves are in contact with the bone for a longer or shorter distance as they pass through the sphenoidal fissure into the orbit or on the clivus of Blumenbach. The bone here may be hollowed (often) by the sphenoidal sinus extending into the great wing or even by the frontal sinus extending backward into the lesser wing (rare) or by sphenoidal or ethmoidal cells projected into that district. In my experience a supraorbital nerve pain of sphenoidal origin is rare. Ophthalmic nerve contact with a thin-walled sinus, however, is also rare. Pain in the brow is frequent and may arise from a number of causes; e. g., frontal sinus vacuum or empyema, or anterior ethmoidal neuralgia, or maxillary nerve irritation in the sphenoid, and these must be very carefully differentiated. Supraorbital neuralgia (headache), however, of systemic toxic origin is *very* frequent. A lesion of the trochlear nerve is also *very* rare, according to my experience and that of my ophthalmological associates. Sphenoidal lesions of the oculomotor and abducens are seen oftener because of their arrangement in the sphenoidal fissure (the sixth is exposed on the clivus of Blumenbach and the sixth and third come into relation with the wall of the sinus when it is prolonged into the great wing; the fourth is more protected). These lesions are seen, however, much less often than those of the optic and infinitely less often than the maxillary and vidian lesions. It is a fact that the nerves in soft confines are not as often exposed to the sphenoidal sinus as those in the bone confines. But this, to my mind, explains only a small part of the great statistical differences; i. e., the very frequent involvement of those in the bone confines and the very infrequent involvement of those in the soft confines. And in this connection I emphasize again that narrowing of their confines is the probable prominent part of the lesion. Were the simple inflammatory process in the membranous lining of the sinus responsible for the clinical pictures by

Digitized by Illinois College of Optometry

transmissions of its toxins through the bone, or were a periostitis of the foramina and the sphenoidal fissure, or were the lesion a neuritis from continuity, to blame, then in all reasonable probability would the oculomotor, trochlear, ophthalmic and abducent nerves take part in these pictures more often. I believe this because of my cocaine experiments (see page 159). In some instances the entire trigeminus may be paralyzed by painting the sphenoidal sinus with cocaine solution, with great confusion in the eye which the patient cannot describe. The sphenoidal sinus enlarges until it comes into close relation with the foramen rotundum often as early as the third year of life and by the seventh year often reaches to the Vidian canal. This seems to me to be the anatomical explanation of these cases in childhood. They are, however, rarer in childhood, as may be expected if we accept the theory of narrowing of the canals.

Dr. Wright believes that some of the pain in these cases must be caused by a periostitis in the nasal fossae just as such a lesion on the shaft of the tibia causes pain.

Post-ethmoidal-sphenoidal inflammation in the *young* often takes on the hyperplastic bone process evidenced by thickening, polyps and general edema. In children it is *often* the cause of *frequent coryza* with *paroxysmal sneezing, asthma, bronchitis* and fever. I believe these symptoms (not fever) are brought about as a sympathetic nerve manifestation from the nasal ganglion. Pediatricians often report this syndrome as the result of other causes without the nose having been excluded as a possible factor.

An *index* to the hyperplastic process seems to exist. The degree of hyperplasia of the plica septi seems to indicate a corresponding degree in the sphenoid, explicable probably by virtue of the fact that secretion from the sphenoid descends over the plica (usually) whereas that from the post-ethmoid passes over the end of the turbinate. The secretion is often serous. I believe, however, it is distinctly irritant. This would seem so from its effect on the skin of the tip of the nose and the lip. The middle turbinate in *general* is *not*, however, an index of the changes in the *post-ethmoidal-sphenoidal* sinuses.

Hyperplastic sphenoiditis, in my opinion, is the explanation of why the treatment of nasal ganglion neuralgia is so

Digitized by Illinois College of Optometry

often disappointing. The diagnosis may seem clear inasmuch as the pain complex may be controllable from the nasal ganglion by cocaine, but injection of the ganglion is followed by only a short period of relief because the irritation continues. The injection of the ganglion helps, but the satisfactory relief of the patient is accomplished only after the hyperplastic bone process has been controlled. This happens *sometimes* as a result of the *injection* but at other times reinjection and in many, a post-ethmoidal-sphenoidal operation with *after treatment are required.* (Cases 46, 54, 108.) Until this is accomplished, the hyperplastic bone process may keep up the ganglion irritation indefinitely.

Chas. B. Williams and recently E. T. Senseney have published observations on the part that endocrine disturbances may play in lower half headache. In some cases when treatment was unsatisfactory they obtained satisfactory results by the administration of corpus luteum, ovarian and thyroid substance. I do not know how these cases may be identified or selected. They involve the consideration of the rôle of the involuntary nervous system in lower half headache and its correlated phenomena (see page 271). I have thought about these influences for a long time, originally because of the part the menstrual function plays in these cases. Many have uniformly an exacerbation at that time manifested by congestion in the post-nasal district with headache, and I have repeatedly tried endocrine remedies in such intractable cases. I have also sent some such cases to Dr. Wm. E. Engelbach, an accomplished endocrinologist, for general investigation, but so far our efforts have failed. I have, however, known of such success, not only in Dr. Senseney's practice.

It is pertinent here to mention the course of an intractable headache that I observed first in 1899. At that time a healthy young woman aged 23 years presented herself with an acute suppurative pansinusitis, accompanied by severe headache for the first time in her life. The acute suppuration ceased with the exception of sphenoiditis. I operated for this. The suppuration stopped, but there remained headache and a slowly progressive hyperplastic process. The openings into the sinuses have remained, but despite all effort that I was capable of she

Digitized by Illinois College of Optometry

suffered with headache, irregularly recurrent, often, and severe, until the menopause which was complete two years ago. Since this she has not had headache and the hyperplastic process in the postnasal district has involuted so far as to be no longer recognizable. The district appears *normal.*

In two severe intractable headaches in women (35 years old), where everything else failed, I have succeeded fairly well in relieving them by prolonged administration of small doses of tuberculin. These women were not tuberculous. It may act as a foreign proteid only. Thyroid and corpus luteum extract failed. In another woman (30 years old) with old healed bone tuberculosis tuberculin and everything else failed. After 15 years she died of what was said to be tuberculous meningitis. No autopsy was held. She had been examined many times by able physicians in all departments of medicine. In one severe case, a woman 45 years old, I got results with corpus luteum extract after everything else failed. She had had a pan-hysterectomy ten years before.

I know of no such corresponding influence in men. Dr. Senseney's patients were all women.

It is quite possible that some endocrine influence is the cause of some of the failures of the injection of alcohol for nasal ganglion neurosis. There are cases that according to the cocaine test should give satisfactory results by injection but do not. Some of these are sphenoidal complications. There are, however, others for which no explanation can be offered at present.

A. J. Carlson has also published a report of the endocrine glands in relation to the ear, nose and throat.

The best post-operative anatomical results—I mean by this, that the result has remained better, for a longer time; i. e., remained less altered by a continuance of the hyperplastic process, according to my observation—have been in patients whose general bony skulls have changed least from year to year. These patients show age by change in the skin rather than of feature.

In all these cases a slight acute process added to the existent hyperplastic process brings on disaster out of proportion to the acute process.

Digitized by Illinois College of Optometry

I record the observations of Dr. Wright made upon the conclusion of the examination of the series of specimens:

"As a result of the observations made upon Doctor Sluder's specimens and as the result of the conference with him in which he has detailed the history of each case in connection with the pathological findings, one may say in a general way that the coincidence of inflammations of the middle turbinate with inflammations of the sphenoidal sinus, is by no means universal, that is, in some of the cases marked involvement of the mucous membrane and of the bony structures in and around the sphenoidal sinus was observed while the middle turbinate was in a fairly normal condition, and the same is true in a reverse sense.

"I have been especially impressed in examining the cases to observe that the vast majority of specimens submitted to me were from female patients. Doctor Sluder perhaps can go more carefully into the relative proportion of these, but so far as the slides which he has submitted to me go, it is quite evident that perhaps three-quarters of them are from females.

"As to the histological findings, again it may be said that evidently the inflammation of the upper sinuses of the nose is a very frequent occurrence with many of the symptoms of pain in and about the nose or even of diffuse headaches apparently due to a periostitis with a local cause. Apparently, profound changes may occur in these cases in the mucous membrane and in the bone without serious involvement of the important structures with which Doctor Sluder has so long been busy, but when inflammatory exudates occur in such a way that the Vidian nerve and the second division of the fifth are affected by the pressure of inflammatory exudates, we get periphery manifestations of pain in the lower part of the head and the cervical region running down to the shoulder which is very distressing and obstinate and may last for years. Apparently, the same principle may be applied to the optic nerve.

"The patient may have had inflammatory conditions of his sphenoidal sinus for many years before serious involvement of the optic nerve occurs. When it does, the evidence goes to show that the inflammatory process has extended to the neighborhood of the course of the optic nerve from the upper and

Digitized by Illinois College of Optometry

outer wall of the sphenoidal sinus inducing marked functional disturbance in the eye or even complete destruction of the function of the optic nerve.''

Dr. Wright's observation that most of the patients were females is true for the series presented. In practice, however, I think the preponderance of females over males is much smaller, if they be not almost equally divided. In an epidemic of post-nasal infections such as existed in St. Louis for three years (1912-1914 inclusive), and as I understand has existed in other parts of the United States also, the sexes seemed to me to be equally attacked. The females seem to become chronic sufferers somewhat oftener than the males, possibly because their bones are often lighter, which means that the above considered nerve trunks have less protection. A possible additional explanation of this fact may exist in the influence of the menstrual function as shown in the cases recorded above (page 182).

DIAGNOSIS

The clinical diagnosis of hyperplastic post-ethmoidal sphenoiditis follows the same general rules that govern the anterior ethmoidal region. The former is, however, very much more inaccessible and must be illuminated through a much longer and narrower channel when examined from the throat. Examination from the front of the nose is so seldom satisfactory that it cannot be relied upon. If a cadaver is examined and measured it will be found that from the post-nasal glass as it rests in the throat to the upper meatus and the sphenoethmoidal recess is, in a full sized head, a distance of from 6 to 8 cm. This illumination must be supplied by reflection from a glass often as small as 1 cm. in diameter and be projected into the narrow olfactory fissure. It therefore requires a powerful source of light to be sufficiently illuminating when reduced to this small pencil at that distance. These points may appear trite but from great experience with the patient I feel that they cannot be too much emphasized, and from a wide experience with rhinologists of all degrees of professional acumen, I feel that the intensity and quality of the light employed for these pur-

Digitized by Illinois College of Optometry

poses are very often unsatisfactory for the necessities besetting this district.

The one, oldest light, all powerful, uniform, white and available for everyone is the direct sun. When focused, however, by the concave head mirror it is too hot to be borne by the patient. It must therefore be used with the head mirror more or less out of focus. Moreover the light of the direct sun on a clear day focused by a 10 cm. head mirror is so very intense that it is apt to obliterate much if not all of the detail of the picture and so defeat its own special ends. Furthermore the

Fig. 111.—Lietz liliput arc lamp.

brighter the light, the more evident become all flaws in the post-nasal glass however minute (such as scratches made by wiping), which make more or less added difficulties. Using the head mirror out of focus therefore serves three important purposes. The same objects are attained by using the sun shining through thin fleecy clouds or something giving this effect. Among the electric lights must be mentioned an arc light* made and sold by Ernst Leitz of Wetzler, Germany, under the name of "LilliputArc Lamp" (Fig. 111) which is as satisfactory as the direct sun, with the advantage of being available at any hour. The carbons meet at a right angle and give a very brilliant white light

*May be Purchased from V. Mueller & Co., Chicago.

Digitized by Illinois College of Optometry

which is condensed into a pencil by a convex lens. When this pencil is reflected by a concave head mirror and focused it is practically indistinguishable from the sun but not quite so brilliant or so hot, both of which points are advantageous. It is a different light from that of the arc lamp in common use as street illumination. In burning, a little white smoke is given off which condenses to a white powder suggesting zinc oxide, suggesting that the carbons had been impregnated with a zinc salt which may be the way in which the "white" light is made. Leitz declines to tell the process of manufacture. No incandescent bulb light that I know of is so satisfactory as the sun or the "Lilliput Arc" for brilliancy or color. The gas lights have more serious faults, namely, less brilliancy and more colors. The light should be white and bright. A yellow or red color to the light interferes with the correct estimate of the color of the membrane and sometimes the thickness of the epithelium in the parts examined and a green or yellow color makes the recognition of small amounts of thin greenish or yellowish secretion very difficult or impossible. The Argand gas lamp is quite red and yellow and the incandescent gas mantle (Welsbach or Auer's) is green and yellow and of far too little brilliancy. So to my mind the sources of light in routine use by rhinologists at present are usually unsatisfactory for post-nasal observation although I recognize that for anterior rhinoscopy they answer their purposes. The advantages of a brilliant white light have been recognized by *laryngologists* for many years. Morell McKenzie in *The Laryngoscope,* third edition, described the oxyhydrogen calcium light and I saw it in use in the London clinics a number of years ago. The calcium light is perfect but more troublesome than the electric arc. The importance and advantages of bright white light for the *sphenoethmoidal district* have not heretofore been emphasized. One other source of light and means of observation should be mentioned, namely, Holmes' nasopharyngoscope. Sometimes it is of the utmost help by virtue of its right angle vision and should always be at hand but its short focus and incandescent lamp make the interpretation of its picture more difficult than that of direct vision with strong white light.

Digitized by Illinois College of Optometry

J. G. Heitger[1] has used a red free light for post-nasal diagnosis. He says it emphasizes opacity and vascularity of the mucous membrane. I have not as yet had a chance to try it.

Another item that may seem supererogatory is a description of the normal post-ethmoidal-sphenoidal district. No clear description, however, such as will answer my purposes, exists so far as I know.

The posterior end of the middle turbinate should be considered the lower boundary of this region. The posterior margin of the vomer bears the plica septi. In the effort to describe the normal of this region, emphasis should be laid on the color, thickness and translucency of the membrane of the olfactory fissure and the size and character of the posterior tip of the middle turbinate and the plica septi.

The color of the normal membrane is pink (not red) and it fits closely to the bone. It gives the impression of thin pink silk velvet. The epithelium is smooth and transparent and the effect is given that the membrane is translucent. It appears moist but not wet. If it is wet it will glisten. (The degree of moisture here is, to my mind, an important item.) No vessels are recognizable clinically. The tip of the middle turbinate is smooth and pink but gives the impression that the membrane is less closely applied to the underlying bone. The plica septi is only slightly developed and is of pearl pink appearance, that is to say, it is slightly less translucent than the surrounding membrane. Such a picture is not seen in the routine of a rhinologist's practice as a rule. Patients who consult him have had some disturbance in this district in the great majority of instances. He can, however, familiarize himself with it by observation on children suitable for the purpose or on adults who have been free of nasal disorders and who are not "subject to headache and stiff neck." I emphasize this point because such patients are frequently unconscious of an existing nasal lesion as the cause. Another district which furnishes a membrane similar or identical is the septum in the lower anterior half but well back of the vestibule. The membrane here is not apt to show hyperplastic changes until the remaining nose is markedly involved by that process.

An acute inflammation in this district causes the membrane

Digitized by Illinois College of Optometry

to swell and become darker red and more moist—wet. (Sometimes it is found that the appearance of acute inflammation is not an acute state, but is present as a chronic state and sometimes it is present throughout the nose.) Pus may or may not accompany it. It does not cause the vessels to show or the epithelium to become opaque or rough. When, however, it is oft repeated, some swelling remains permanent and some small vessels become visible and a quality of opacity is added which is from thickening and clouding of the epithelium. Moisture or pus may or may not always be present. The surface appears more or less roughened. Swelling of an edematous nature may be present but it is much less likely than in the middle meatus in front, under similar conditions. Oblique illumination of thickened epithelium may give the appearance of thin pus, best marked in the upper arc of the choana.

Another change in the membrane of this district which should be carefully observed is a velvet-like thickening without much if any change in color or moisture and without the appearance of macroscopic blood vessels. Slight roughening of the surface may be discernible without opacity. It reminds one of the "lymphoid enlargement" of the tonsil in contradistinction to the "inflammatory enlargement."

All changes in these parts should be carefully noted because a very slight surface change is often accompanied by much more advanced and serious change in the deeper parts as is often shown by the finding of polyps within the cells at the time of operation, no evidence of which was previously recognizable. And furthermore, patches of inflammation may often be found with the pharyngoscope within the cells which are very pernicious and disastrous according to their location; e. g., upon the optic canal. These patches are often much more marked than the changes in the parts exposed for observation prior to the opening of the cells.

For these reasons I feel that the *normal* should be clearly fixed in the rhinologist's mind and all changes departing from it, however slight, should be most carefully considered. There is a tendency at present among rhinologists to advocate a post-ethmoidal-sphenoidal operation in cases of ocular lesions even though the sphenoid is normal. I believe close attention to

Digitized by Illinois College of Optometry

these points will show that very few if any of these cases are normal. Furthermore I do not believe that the post-ethmoidal-sphenoidal operation is free of danger in the hands of every rhinologist. The most experienced rhinologist may get lost in this region at times. I have seen the eye which it was intended to save, lost for the vision it had at the time of operation, and Harmon Smith also has reported such disaster. In private conversation with rhinologists I have learned of death following a number of these operations. Simple opening of the sphenoid from its natural opening downwards is as nearly free of danger as surgery may well be, but that is utterly insufficient in many cases, as will be at once seen from an inspection of almost any set of a dozen specimens. Sometimes the sphenoidal sinus forms the inner part of the optic canal and sometimes the post-ethmoidal sinus forms it; and there is no way to tell in the patient at the time of operation which it is. Therefore the sure practice is to do the combined operation.

The distribution of the hyperplastic process here is of great interest, and various. Sometimes it is an extension backward of an easily recognizable hyperplastic anterior ethmoiditis* manifest by enlargement of the soft parts and bone of the middle turbinate with edema and polyps in the middle meatus or sometimes extension backward of a general hyperplastic rhinitis. But these are, to my mind, by no means necessary forerunners. Frequently I have seen hyperplastic post-ethmoidal sphenoiditis develop in adults who had been my patients from early childhood and who to my personal knowledge had never had a clinically recognizable affection of any of their paranasal cells, and did not have a general hyperplastic rhinitis. In these patients it began as the primary, and was the only sinus involvement. It was the result of repeated infection of this district alone. It furthermore is capable of other niceties of distribution. Later it develops more markedly as a post-ethmoiditis or a sphenoiditis. It seems to me from close observation that a post-ethmoiditis in time brings about a hyperplasia of the posterior tip of the middle turbinate, and that a sphenoiditis likewise produces a hyperplasia of the plica

*Uffenorde[2] has given a careful description of this anterior picture clinically and anatomically to which the reader is earnestly referred.

Digitized by Illinois College of Optometry

septi. Explanation of these phenomena seems to me to lie in the fact that the thin serous secretion which usually accompanies this process is discharged from the post-ethmoidal outlet over the posterior tip of the turbinate, whereas the thin secretion from the sphenoid in the sphenoethmoidal recess is usually found over the plica septi while the head is erect. I have proved these facts on the cadaver. This secretion is in all likelihood irritant if the effects of nasal serous discharge on the lip may be taken as a criterion.

I should like particularly to call attention to a hyperplastic inflammation of the posterior tip of the middle turbinate and the sphenopalatine foramen district, for the reason that this lesion has so often been the accompaniment of chorioiditis with clouding of the vitreous, iritis and hemorrhage into the vitreous and anterior chamber. (Cases 71, 72.) I do not recall that this has been associated with optic neuritis. Dr. Wright observed that the vessels in the material removed from these cases showed more involvement than the specimens removed from the headache or the optic cases with less bone involvement.

Polyp formation may accompany hyperplastic post-ethmoidal sphenoiditis and show in the olfactory fissure constantly or only at the time of a coryza to disappear with recovery from the coryza. These, however, are the less frequent cases. The probe may recognize the more advanced degrees of thickening.

Post-ethmoidal-sphenoidal suppuration is readily recognizable if the pus is thick and adherent so that it remains at the point of entrance into the nose; and is at all profuse. As the patient begins to recover and the secretion becomes less and thinner it is not always so easily recognizable. This is true for several reasons. (1) Thin secretion easily descends from its point of entrance into the nose and is not readily found at that point, as is thick adhering pus. (2) The outlets of the post-ethmoidal and sphenoidal cells are so frequently not to be seen by any method of inspection; unless the pus is adherent enough to accumulate at those points it will not be found. The district is almost always moist and does not permit pus to thicken by drying. If anything it makes it more liquid. In a narrow nose secretion from the post-ethmoid, in the erect

Digitized by Illinois College of Optometry

or reclining posture flows over the middle turbinate at a point which makes it very difficult or impossible to recognize by any of our present means of investigation. In a wide nose this is easily seen by posterior rhinoscopy, sometimes by Holmes' pharyngoscope. Some of the secretion passes downward and backward over the posterior tip of the turbinate and would be easily recognized if it remained there, but in small and medium sized pharynges the soft palate rises in swallowing, and certainly in gagging (which frequently happens in the examination) to a height that wipes it away from the tip. I have proved this repeatedly. It is necessary therefore to recognize the secretion anterior to the choanal plane. In many instances this is very difficult or impossible; e. g., in such cases as have small choanal outlets which are placed rather high compared to the level at which the post-nasal glass must rest. It will therefore be recognized that my argument is that a post-ethmoidal sphenoiditis may exist and pour into the nose a thin secretion which cannot be recognized at the points of entrance into the nose. Secretion from these parts, when from a process of long standing, eventually becomes serous, transparent and colorless. When from a process of more recent origin it is seropurulent, not unlike thin cow's milk in color and thickness. The picture may be reproduced in great verisimilitude by the instillation of a few drops of thin cow's milk into the olfactory fissure. Such an experiment will also prove the short time such a fluid remains recognizable. In from three to five minutes it will have disappeared: and also, in a small pharynx the wiping effect of the palate may easily be seen.

Very seldom is to be seen a stream of pus coming from the sphenoid and descending from the sphenoethmoidal recess over the posterior pharyngeal wall to descend upon it. This happens only in large pharynges where the soft palate is too short to reach up to wipe it off. Were it not for the wiping effect of the palate, this would be a frequent picture.

In the cases of sinus headache the importance of a tiny streak of pus on the posterior margin of the vomer should be observed. Usually it can be determined from which side it appears. These cases are often of great importance and surpass

Digitized by Illinois College of Optometry

all others for diagnosis. The ostia of the sphenoid and the post-ethmoid in these cases are almost never visible. Sometimes the plica septa is enlarged. Many times the posterior nasal picture is normal. In this connection a correlated action of the pharynx and soft palate (Sluder[35]) may be responsible for the difficulty in finding the suppurations.

The following is a detailed description of experiments proving the effects of the trowel-like and wiping effect of the soft palate:

THE CORRELATED ACTION OF THE PHARYNX AND SOFT PALATE; AND ITS EFFECTS UPON POST-NASAL DIAGNOSIS (SLUDER[35])*

By correlated action of the pharynx and soft palate must be understood the resultant action or effect of both the parts acting at once.

This district is complex anatomically, and serves in several functions; namely, swallowing, gagging, vomiting, sneezing, sucking, coughing, snoring, breathing, speaking, and singing, each of which is complex physiologically. My concern here is with the naso and oropharynges, and the functions of empty swallowing and gagging.

The simplest conception of the district, it seems to me, is that it resembles a soft walled tube, wanting in large part in front where the soft palate acting as a flat valve divides it into a nasopharynx above and an oropharynx below. The upper outlet is fixed bone and divided into the choanae by the septum nasi. The deficiency below is the posterior outlet of the mouth. The action of the tube in swallowing is a vermicular contraction from above downward, the anterior lower deficiency being closed by the tongue, which moves backward and upward, while the palate closes off the upper part. In ordinary swallowing a gentle degree of muscular contraction is used. In gagging the vermicular action is from below upward with the strongest contraction.

In or upon the posterior wall (pronounced in children) above the soft palate, is placed the pharyngeal tonsil increasing

*Reprinted from the Transactions of the American Laryngological Association, 1914.

Digitized by Illinois College of Optometry

in front to back measurement from below upward, its uppermost part a free surface, somewhat shelf-like, almost touching the basilar process of the occiput; or it is a little further removed from it according to the degree of swelling or shrinking which has gone on in it. Laterally, below the soft palate, are placed the faucial tonsils varying in size and degree of imbedding. They are nearly always limited below by their junction with the lymphoid tissue at the lower lateral aspect of the tongue, which is a rather constant point. Their limitations above are less constant.

Two types of tonsils may be recognized—one placed free (''unattached'' or ''nonadherent'') between the pillars of the fauces; the other place deeply (imbedded) between them, little if any of its substance protruding ''free'' into the pharynx. According to the degree of enlargement of the organ either of these types may rise into the mobile palate, even to meeting in the median line, compressing the uvula between them or crowding it forward and upward. When this is true, the upper lateral limit of the tonsil mass rises often to the junction of the upper and middle thirds of the palate; but this is less apt to be true for the free tonsil than for the imbedded one. The large ''free'' tonsil may lie under the palate arch in equal volume but will push up the arch itself rather than ascend within it which makes it (the arch) look higher, if not stand actually higher.

Just above the palate and slightly posterior to the middle line of the tonsil is found the cartilaginous mouth of the eustachian tube, which varies in size, prominence and position; being small and flat, or large and protruding one-half to one cm. into the pharynx; or rising as high as the middle turbinate. Posterior to the mouth of the tube is the recessus pharyngeus (fossa of Rosenmueller), which may be scarcely at all marked or may be one and a half cm. deep and one cm. wide, extending outward and backward.

The free margin of the vomer begins below at the posterior limit of the hard palate and may rise straight up or pass upward and backward at an angle of 45 degrees. The angle of the choanal plane is determined by this angle. Its vertical

Digitized by Illinois College of Optometry

measurement varies from one and one-half cm. to three and one-half cm. approximately.

The plica septi varies in size and position, extending slightly beyond the free margin of the vomer; or is placed well forward of this and sometimes higher or lower.

The soft palate is rather constant in length from its junction with the hard palate to its lower margin, but varies from two mm. to one cm. in thickness. The uvula and tongue vary greatly in size, and may play a part in correlated action.

The dimensions of the pharynx at the level of the palate may be five cm. laterally, by two and one-half cm. anteroposteriorly, which is the largest pharynx I have seen. Luschka gives those measurements as normal. From my observations the average measurement in what seem normal adults in life is only about one-half of that size, and it seems to me that those measurements may be further reduced by one-fifth in what must often be admitted as normal. Such, however, must be considered a "small normal" pharynx. It may be narrowed to obliteration, by enlargement of the structures found in it. The circular measurement of this plane may be greatly lessened, without the soft palate being shortened as it might be were the simple requirements of the flap valve followed. It seems its length is determined by something else than its functional needs. Its elasticity may vary.

I have thought it of interest to know, for clinical use, what happens in the nasopharynx during the acts of empty swallowing and gagging, and to this end have conducted in a desultory fashion a number of experiments extending over thirteen years' time. No way was known to me by which these functions could be observed directly, and even now with the help of Holmes' nasopharyngoscope and the x-ray it still seems impossible. The x-ray of a bismuth bolus being swallowed shows its upward and backward, or its directly backward course after passing the hard palate; but otherwise does not help. Einthoven has given an extensive bibliography of writings on the physiology of the pharynx. But the particular type and purpose of the observations now to be described I fail to find recorded.

Digitized by Illinois College of Optometry

For my purposes I have tried many pigments to see if one could be found that would mark the surface wherever it touched, when placed on the upper surface of the soft palate in liquid form, one or two drops in volume. Two qualities were necessary in it, namely, that it should adhere readily to the membrane, and contrast sharply with it. These were found in a mixture of bismuth subcarbonate or hydroxide. Nitrate of bismuth is dissolved in dilute nitric acid and mannite (about 2 per cent) added. To this is added a solution of carbonate or hydroxide of soda to neutralization. The precipitate is washed free of salts and allowed to settle, or centrifuged to the thickness of buttermilk. It is opaque white, contrasts sharply with the red of the membrane, and adherent to it under all conditions sufficiently to permit of any desired observation. Liquid India ink* may be used as a black pigment. A drop or two of the liquid is introduced through one nostril by means of a small caliber canula and syringe, to arrive at the upper surface of the soft palate at a point in the center line of the choanal outlet. In a normal adult pharynx it is, upon swallowing, found spread over its posterior wall as high as the lower margin of the eustachian tube, usually equally on each side. The mouth of the pharyngeal bursa is below this level. In this way I have seen pus, secreted by the antrum of Highmore in small amount, come into the nasal fossa in some way that eluded detection, reach the soft palate from the floor of the nose, and be habitually absent from the nasal fossa, to appear spread over the mouth of the pharyngeal bursa simulating Thornwald's disease.† The soft palate acted as a trowel and spread the pus there, as a mason spreads his mortar with his trowel. Inasmuch as no pus could be found in the nose this deception was complete for some time. In this throat, gagging would have spread the pus in the same general way a little higher up. This effect, however, may be *reversed*. Instead of the pus being spread from the floor of the nose and soft palate, upward and backward, it may enter the nose from behind and above, and be wiped off the posterior pharyngeal wall to appear only upon the upper back part of the palate. Its origin then may be difficult to trace.

*Draughtsman's India ink is sold in the American markets in liquid form.
†Uber d. Bedeutung d. Bursa Pharyngea. v. G. L. Thornwaldt, Wiesbaden, 1885.

Digitized by Illinois College of Optometry

In order that this may happen the throat must be narrow in anteroposterior measurement regardless of what may be its lateral dimension.

Should the tonsils be small or absent, the loss of their pushing upward effect results in a lesser ascent of the palate. For the highest trowel effect in the nasopharynx the presence of the tonsils, to a greater or less extent, is necessary. The mouths of the tubes may or may not assist in this by the coming forward of the posterior wall of the pharynx to meet them, thereby obliterating the recessus pharyngeus. In a pharynx with small tonsils and small tube mouths, a drop or two of the bismuth mixture introduced to descend over the lateral aspect of the end of the lower turbinate will, in swallowing, be found spread on the lateral half of the posterior pharyngeal wall of that side at about the level of the lower part of the mouth of the tube. In the production of this picture the tube's mouth is set in the normal position; that is, there is approximately one-half cm. free space between the tip of the turbinate and the cartilage of the tube; with like space between the floor of the nose and the cartilage, and like space in the recessus. The tonsils must be normal. Should they be large and rise high the pigment will be spread to a higher level, as they, also, are carried up in the rise of the palate and are assisted in this by the base of the tongue.

In gagging, the contraction of the constrictors may be so strong that in a smaller throat the posterior wall of the pharynx is brought forward to the limit of the hard palate and the lateral walls approximated. At the same time the soft palate is forcibly elevated to a considerable degree above the level of the hard palate, sometimes dimpling one cm. above it. It should be recalled that the thickness of the soft palate is an average of about one-half cm., and frequently twice that; so this must be added in estimating, from below, the ascent of its upper surface. When the lateral walls are approximated and the posterior wall brought forward, and the palate is, as it were, stuffed upward into this narrowing gap, as happens in gagging, it is found that in the small normal throat the nasopharyngeal space is annihilated, as may be shown when a drop of bismuth mixture is palced near the center of the upper surface of the soft

Digitized by Illinois College of Optometry

palate and gagging induced. The resultant picture shows the pigment to have been spread by a general approximation of the surfaces, that is to be generally distributed, including an application to the free margin of the vomer. The angle of the choanal plane will play a part in this. This effect cannot happen in a large normal pharynx, or one of small normal caliber, but of unusual height with a vertical choanal plane; for the tucking up of the palate is a necessary part and it cannot be tucked up beyond its own length. The parts of such pharynges cannot all be approximated, but with their diminution in size it becomes more and more easy, until it comes to pass in a small pharynx with normal swallowing. In this way I have seen seropus spread by the palate from the center of the floor of the choanal outlet, backward and upward, and lose all index to its origin. I have also in this way seen small amounts of seropus, entering the nasopharynx from above, wiped away and so spread out as to elude recognition. And I have often seen a sphenoidal discharge, profuse and purulent, wiped off the posterior wall, leaving no index to its origin, adhere to the palate, and be raised over the tube into the middle meatus. At other times I have seen a small streak of thin pus, descending on the free margin of the vomer, wiped away by the palate and elude further recognition.

In considering diminution of size in the pharynx I feel that the means by which this may happen should be noted. A small pharynx may be part of a general diminutive state, e. g., childhood; or the older pharynx may be encroached upon in several ways. The pharyngeal tonsil may exist in greater or less bulk narrowing its upper part from behind forward. The faucial tonsils may be enlarged narrowing it laterally. I suggest scrutiny of the imbedded type, which may be large and not protrude beyond the surface. They are sunk into the walls and become evident only in gagging. I believe this type to be more potent in producing these effects than the prominent free one. It seems with the help of the tongue more efficacious in crowding the palate upward and backward. In gagging, the tonsil masses are carried markedly upward in the strong upward pull of the palate, while the posterior wall comes forward.

The mouth of the tube—in usual position and environed by

Digitized by Illinois College of Optometry

normal turbinates, permits pus, flowing backward out of the middle meatus, to descend over the lower turbinate between its tip and the mouth of the tube. The act of swallowing will then spread the pus or pigment on the same side of the posterior wall to about the level of the lower limit of the mouth of the tube or a little higher. In gagging, under these conditions, the pus or pigment may be transferred from the lowermost lateral point of the choana of one side to the uppermost lateral point of the opposite side, namely, the lower part of the sphenoethmoidal recess. This happens probably only when the contraction is strong in the obliteration of the last of the already narrowed space, after the palate has been forcibly elevated in a pharynx that is certainly not taller than normal (rather shorter).

The tube may be placed downward and forward of its usual position. Pus then proceeding backward from the middle meatus may pass over the tube backward and downward by way of the recessus pharyngeus. This is made easier by swelling of the posterior tip. In this instance the narrowing of the nasopharynx in swallowing, combined with ascent of the palate, may in propitious throats convert the recessus into a tube, which will have its vermicular movement from below upward. In this way pigment may be transferred from the floor or middle meatus of one side to the upper meatus of the same side, and this holds true for pus also. It may also happen that pigment or pus descending in the recessus from above is at times stuffed into the middle or lower meatus provided it be caught in the right way to reverse this effect. Many times I have seen seropus, entering the recessus from above, by the act of swallowing, wiped away or so spread out as to elude recognition. I have sometimes seen, in gagging, pus from one olfactory fissure smeared over in such a way as to simulate suppuration of the opposite fissure also.

But in the production of these phenomena there seems to be little or no constancy. Sometimes the pigment will adhere more to the anterior parts, and at other times more posteriorly. This irregularity seems true oftener for pigment than pus. Possibly a difference in the moisture of the parts at different times determines this. Bismuth may be used to produce one picture and

Digitized by Illinois College of Optometry

then India ink, at another or the same point. In this way two experiments may be done in a throat at the same sitting.

Observation upon the suppurations leads me to believe that their pictures in the pharynx may vary, that is, be different one time from that which appears at another time under similar conditions in the same throat. And furthermore that these pictures are not the result of a single act of swallowing. They are not so easily or readily produced as to result from a single act. It seems to me that pus is less easily transferred than bismuth and that many of the pictures we find are the results of a small volume of secretion and repeated swallowing, that is, that a small amount of secretion is each time put into its unnatural position, and that the picture we see is the accumulated result of many acts of swallowing. Should the patient gag repeatedly in process of examination, these phenomena may be thereby likewise produced. Observation on the cadaver as well as on the living has shown me, moreover that pus may enter the pharynx from different parts of the nose and not appear at the sinus outlet where it enters. Thin secretion may descend from the sphenoidal sinus on the septum nasi anterior to the plica septi and not be recognizable by any of our present modes of investigation. It reaches the soft palate, below, and is then spread by its trowel action in such a thin film on the posterior wall that it is with difficulty, recognizable. The plica septi shuts it off from recognization by the post-nasal mirror, and it cannot be recognized by the pharyngoscope. The antero-posterior distance between the osteum sphenoidale and the choanal plane varies much in different skulls. This explains how the last mentioned phenomenon may be a fact in some patients, but not in all. The position of the osteum sphenoidale may sometimes be close to the median line, at other times placed far laterally.

A most elusive discharge is that which descends on the free margin of the vomer posterior to the plica septi and is wiped off by the palate in swallowing.

The effects produced by a large tonsil on one side or a large posterior hypertrophy of one side may be calculated, after one has done some of these experiments.

Digitized by Illinois College of Optometry

Resume.—To me it has been surprising to see the degree of narrowing (obliteration) that may take place in the nasopharynx in swallowing and gagging. This seems to have its limitations, however, in the soft parts. The elasticity of the tissues reaches a certain limit only. Therefore when the distance between the posterior limit of the hard palate and the vertebral column is great—2½ cm., and the lateral measurement 5 cm.—the combined narrowing effects are insufficient to obliterate such a large cavity in even the strongest gagging. The soft palate is not long enough to rise beyond the level of the tubes, and the loose tissue beneath the constrictors is insufficient to permit enough movement toward the center to result in approximation (obliteration).

But the degree of elasticity in the soft parts is practically constant. Therefore when the nasopharynx is small either because of scant space in the bony skeleton or because of the size of the structures developed upon or within its walls, approximation of its surfaces (obliteration) is possible by the easy play of the muscles in swallowing or gagging. Naturally the smaller the pharynx the easier may it happen. In a cavity a little smaller than the normal, this would happen only upon strong gagging and the pigment or pus would have to be in fair volume in order to be spread out; whereas in a small cavity a small amount of pigment or pus is spread out far, because the closing pressure is enough to spread a small amount over a wide area. This becomes easier, until, in the small pharynx which one often sees in adults, not to speak of children, it may happen in tranquil, empty swallowing. The quality of the pus also makes a difference. Thick mucopus holds together and does not transfer readily, whereas seropus spreads easier.

Clinically, the understanding of these phenomena is of value —I believe especially so—when some other facts are borne in mind. In considering the transferrence of secretion from one place to another, thereby giving rise to clinical deceptions, it should be recalled that it requires a fluid secretion to permit of this, and that then it is easily done, and that the drier the district and the thicker and more tenacious the secretion the less likely is it to happen. Under the last conditions I have repeatedly tried, in vain, to bring it about. But of *greater* value,

Digitized by Illinois College of Optometry

it seems to me, is to know the fact that by virtue of the power of the small pharynx to approximate its walls it possesses the power to wipe away small amounts of thin secretion from any point of the choanal plane and even points forward of this (as may be shown by the bismuth being often put well into the meatuses). It is then so spread out over the general surface that it is lost from detection, and this may happen in the small pharynx in simple swallowing.

Practical Application of These Observations.—Every rhinologist is familiar with the difficulties that attend the examination of some patients. Despite careful approach, every attempt to see the nasopharynx is followed by gagging, and even a palate hook in a small pharynx does not prevent obliteration of the fault—the posterior wall coming forward. When it is recalled that this simple act may create deceptions in any one of the above enumerated ways, their practical value is self-evident, and when one remembers that in small throats these effects can be produced not only by gagging but by common swallowing, it becomes at once evident that there may be certain nasal disorders requiring diagnosis from the pharynx that may elude recognition indefinitely, i. e., sphenoidal (and post-ethmoidal) discharge of thin consistency descending on the posterior margin of the vomer, or anterior to the plica septi, or in the recessus or near the median line. Such discharge often cannot be seen from in front, including use of Holmes' nasopharyngoscope; so that when it eludes the surgeon from the pharynx, the deception is complete, and I believe may elude him indefinitely. Thin secretion from the sphenoid looks like thin cow's milk. For experimental reproduction of sphenoidal suppuration of thin consistency I have used thin milk or thin bismuth. It is very easily visible at the time of its instillation, but the last trace rapidly disappears from sight in the nose, and from a pharynx that wipes itself in swallowing. I have seen it lost in three minutes and leave no evidence to the patient's sensation—that is, not be recognized as having flown into the pharynx.

In a paper dealing with obscure headaches, I emphasized the fact that sphenoidal inflammation could lose the classical

Digitized by Illinois College of Optometry

picture, namely, the easy showing of pus at the proper point, and continue indefinitely, making headache, but eluding recognition locally.[27] This happens because the secretion gets thinner. The above observations bear directly on such cases. Shrewd observers have emphasized the difficulties besetting sphenoidal diagnosis—conspicuous and familiar is Dr. Casselberry's paper read before the American Laryngolical Association, 1911.

When one bears the possibilities in mind, or better still, will try the various nasopharynges experimentally, he soon learns to estimate—and I believe with reasonable accuracy—the possibilities or probabilities of the individual one at the time of examination, and thereby may avoid some deceptions in the diagnosis.

In concluding, I desire to reiterate and emphasize *that these effects can only very rarely be brought about in what I have defined as the normal adult pharynx with the exception of a simulation of Thornwald's disease, where the trowel action of the soft palate can do this. Very rarely the soft parts may possess unusual elasticity or freedom of motion. Such conditions may make it possible for the normal adult pharynx to approximate its walls not only in gagging but even in swallowing. Alterations in the form and size of the pharynx make the various deceptions possible as herein enumerated. The pictures are produced with surprising clearness by bismuth or India ink and much less so by pus. It is, of course, self-evident that pus at the classical sites, well forward of the choanal plane, with or without a clean pharynx, is of conclusive diagnostic value, and is uninfluenced by any of the above enumerated possibilities*; but he who must needs have these classical pictures clear, before he can make the diagnosis, will have been eluded by other positive cases.

I believe, in a case where the history of nose disease is reasonably clear and the diagnosis very difficult, that it is at times distinctly helpful to know to what extent that nasopharynx is obliterated in swallowing and gagging. This would seem evident from the above context, and may be learned readily by the bismuth experiment.

Digitized by Illinois College of Optometry

The deceptions besetting postnasal diagnosis of the suppurations in children are largely, if not wholly, explained by these observations.

As the inflammatory process continues the secretion loses all purulent character, and the hyperplasia begins. Hyperplastic post-ethmoidal sphenoiditis is usually accompanied by a scant serous secretion but by no means is this always true, just as the same process in the middle meatus is usually accompanied by a little serous secretion but not always. And sometimes the serum may be profuse, but I have uniformly found this to be from the process localized or at least well marked in the membrane over the sphenopalatine foramen; that is, just posterior to the tip of the middle turbinate. The nasal ganglion is immediately beneath this membrane. I have construed and described[42] these cases as manifestations on the part of the sympathetic elements of the nasal ganglion, and not the result of a hyperplastic process in the general expanse of the nose. Treatment of the ganglion will stop the profuse serous secretion but will not stop the hyperplastic process.

Not infrequently it is found that secretion of any kind is totally absent. The membrane is dry. But with secretion or without, under the microscope the lesion is the same. So it is therefore necessary to recognize the changes in the membrane, irrelevant to secretion. This is done by interpreting the color, thickness, translucency of the epithelium and membrane, and vascularity, which are the points I emphasized in the description of the normal. A typical hyperplastic picture usually shows some increase in redness with more or less thickening of the membrane and epithelium. The epithelium may be thickened and rest on a membrane which is not thicker than normal or the membrane may be thickened and covered by epithelium which is normal. The vascularity is increased, manifested by the presence of macroscopic vessels, especially radiating from the sphenopalatine foramen. In addition to this picture exists one manifest only by great diffuse redness and some swelling. It shows no change in the epithelium and no macroscopic vessels and can be shrunk away by adrenalin. At present I do not believe this to be a lesion to be classed as in some manner hyper-

Digitized by Illinois College of Optometry

plastic. I know, however, that it may produce the entire clinical picture as portrayed in this chapter and that it may endure any length of time.

There remains one more item which I feel should be emphasized. In the examination of a patient it is, of course, the rhinologist's concern to determine not only the presence of secretion but also the character of it. Great emphasis is always laid on the presence of pus. The point I wish to make in this connection is the appearances of the epithelium under different conditions. The epithelium on a normal membrane is transparent whether viewed in the perpendicular to the surface or obliquely. When, however, the thickened epithelium is viewed obliquely it is nearly if not quite opaque and on the sharp convexities and concavities presented in the olfactory fissure and sphenoethmoidal recess gives the impression of a layer of pus or seropurulent secretion. This is emphasized in the depths of the sphenoethmoidal recess around the sphenoidal opening which is often visible in good light, and in the upper meatus around the post-ethmoidal outlet. Their edges appear opaque and the depths indistinctly visible so that the appearance of a spot more or less like pus results. The differential diagnosis may be made usually (and without great difficulty) in a light of increased brightness, for example if the electric arc is insufficient the direct sun from a 10 cm. concave glass is ample to settle all question as to what the spot is. Moreover, should it be pus, it is almost invariably greenish yellow or yellowish green whereas the opaque epithelium is white or very slightly bluish white. The spot made by scant pus at the site of the sphenoidal or post-ethmoidal outlet is readily reproduced in the cadaver[41] by the instillation into the cell of a very small amount of bismuth hydroxide in suspension to flow through the outlet into the nasal fossa. The head is then examined by reflected light as in life. Another place where the obliquely illuminated epithelium may give the impression of pus is the upper choanal arc. It is usually marked by a ridge which is the demarcation between the upper limit of the pharynx and the back part of the nose. Here it may appear opaque and give the impression of pus. Just anterior to the ridge is often a sulcus or an expanse that reaches as high or higher than the sphenoidal out-

Digitized by Illinois College of Optometry

let which is then out of the line of vision. Secretion on this surface therefore cannot be seen. Sometimes it may be seen with Holmes' pharyngoscope. As it descends it would of course be recognizable when it reached the ridge and began to descend into the pharynx, if it remained in position. This is the case

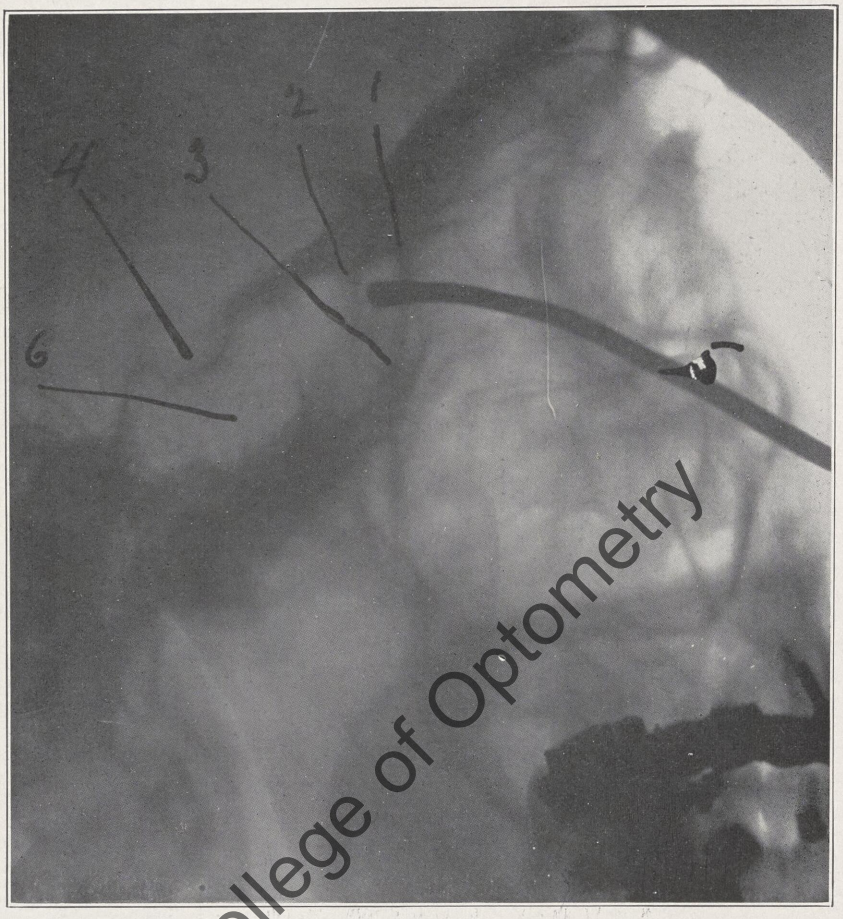

Fig. 112.—Showing a cell *1-2-3* which appeared to be the sphenoidal cell. The probe *5* shows that the veritable sphenoidal cell *6* is behind and below this. *4*. The sella turcica.

in pharynges of considerable size; i. e., so large that the soft palate is not long enough to rise to that height and so cannot wipe it away. But in smaller pharynges the palate in the act of swallowing wipes it away and particularly is this true in gagging which frequently happens in the examination (Sluder[35]).

Digitized by Illinois College of Optometry

Secretion on or over the ridge therefore is very often not allowed to accumulate but is constantly wiped away. The rhinologist's judgment here may be furthermore confounded, not only by the obliquely illuminated epithelium which as stated above may give the impression of pus, but by the fact that pus from elsewhere within the reach of the palate may, by the trowel-like action of its upper surface during the act of swallow-

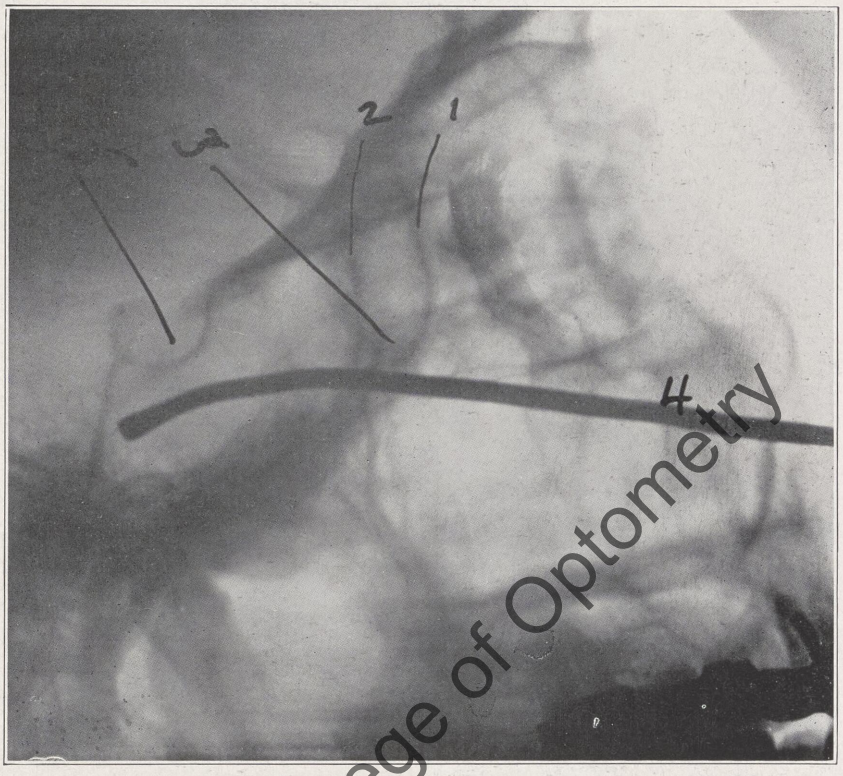

Fig. 113.—Same as Fig. 112 showing probe *4* in lower cell. *1-2-3.* Upper cell. *5.* Sella turcica.

ing or gagging, be transferred from its point of origin, e. g., the lower meatus of the same or the opposite side to the upper choanal arc, and if it is in sufficient amount it will be pushed forward beyond the choanal plane. This will then be not only a deception but produced by pus really.

A. L. Yates has recently made a most instructive observation. By pigments and dyes placed in the anterior nares and

Digitized by Illinois College of Optometry

observed, he determined that much of the flow of mucus was backward into the pharynx. He followed it downwards where it was seen on the arytenoid cartilages, and he determined what is probably more important in that it is subject to change. It has the power of resisting destruction by bacterial toxin but may lose this and become easily permeable by water-soluble toxins. It may have the power of resisting water but if this be

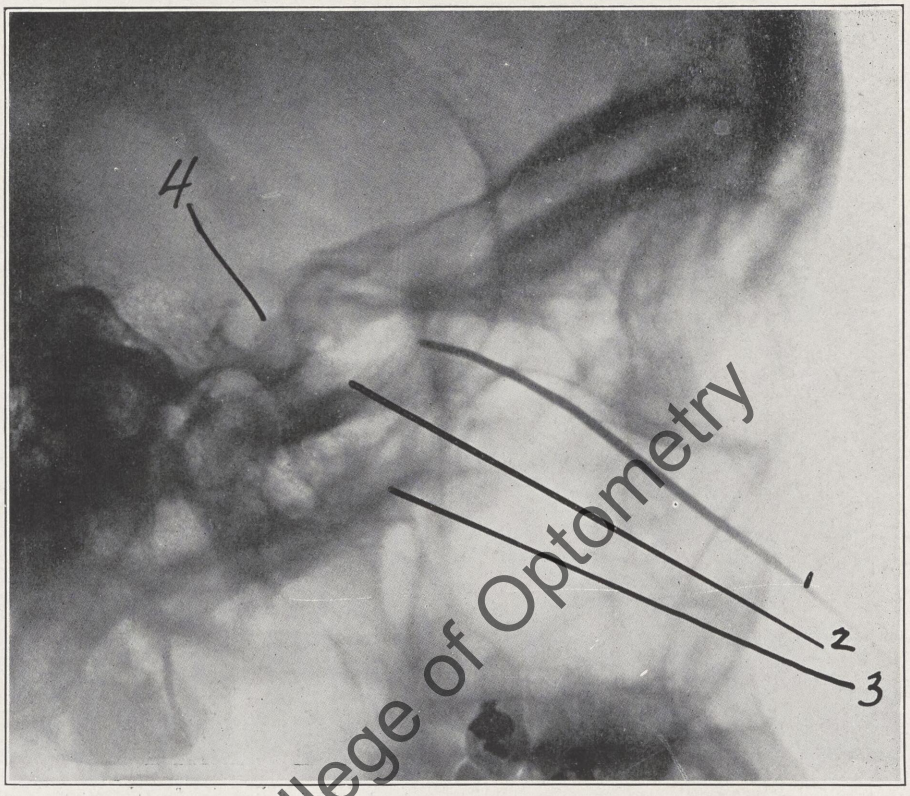

Fig. 114.—Showing an upper and lower subdivision of the sphenoidal body. *1.* A probe in what was the upper cell. *2.* The remains of the separating shelf. *3.* The lower cell opened down in the pterygoid process as far as the bifurcation of the plates. *4.* The sella turcica.

lost, water-soluble toxin passes through and poisons the cilia. As this happens the secretion is also paralyzed and as this increases the bacteria come to dwell in a symbiotic state in the sinuses and from them toxins are readily absorbed with the production of remote symptoms.

Digitized by Illinois College of Optometry

Hyperplastic post-ethmoidal sphenoiditis is rarely unilateral. It may be more marked on one side than the other and the configuration of the district may interfere with its recognition, more on one side than the other. These facts should be borne in mind particularly where the diagnosis is a matter of

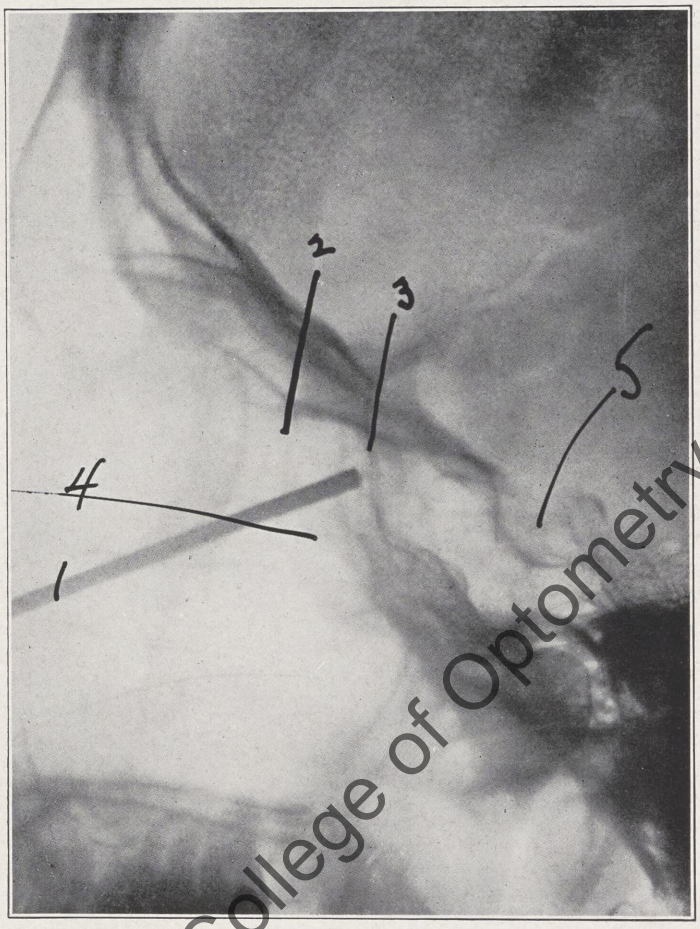

Fig. 115.—Showing an anterior and posterior subdivision of the sphenoidal body. *1.* The probe. *2-4.* Anterior face (this line has been retouched to show better in the reproduction). *3.* Anterior face of posterior cell. *5.* Sella turcica.

serious import, e. g., where a serious eye lesion exists, and the appearances permit of the diagnosis only on the opposite side. Under these circumstances I have operated the side having the eye lesion, despite the fact that the appearances did not per-

Digitized by Illinois College of Optometry

mit of the diagnosis on that side, and found the lesion under the microscope and have been rewarded by the recovery of the eye lesion. The recognition of the hyperplastic process on the opposite side served as a trustworthy guide. Uffenorde[2] observed that hyperplastic ethmoiditis (anterior) is rarely unilateral. He states that it may develop more on one side because of "unfavorable circumstances"; e. g., a deflected septum. But

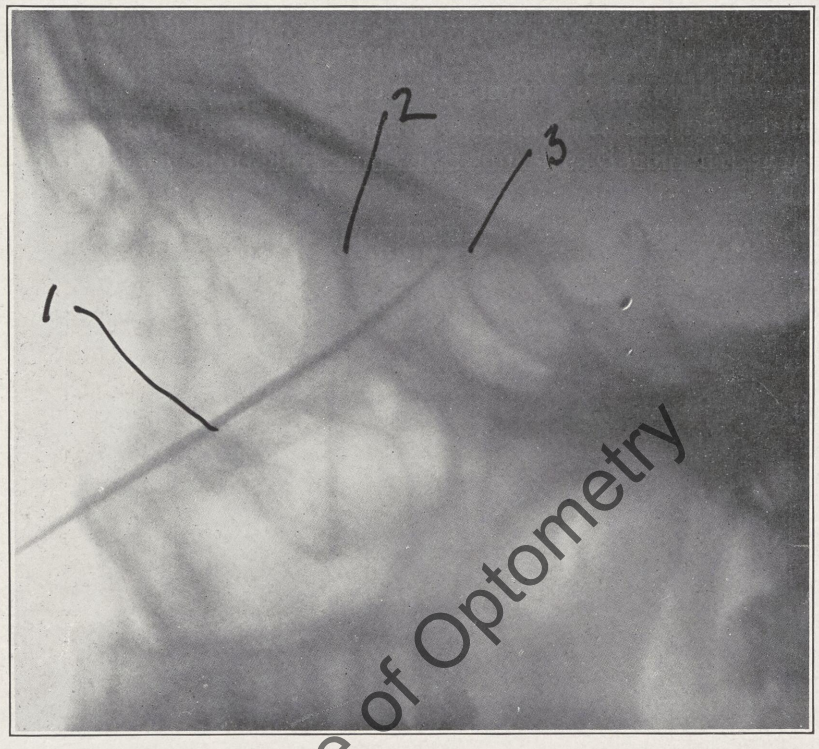

Fig. 116.—Showing subdivided sphenoidal body. *1.* Probe. *2.* Anterior face of anterior cell. *3.* Anterior face of posterior cell.

in a post-ethmoidal-sphenoidal picture such an etiological factor does not exist. Moreover, that may not be the correct interpretation of the anterior picture.

Anatomical Variations.—A feature in the diagnosis quite aside from the pathological lesions described, exists in anomalous anatomical arrangements of these parts. Failure to bear these possibilities in mind may utterly defeat the best technical efforts of rhinologists.

Digitized by Illinois College of Optometry

It not at all infrequently happens that the body of the sphenoid is shared by a post-ethmoidal cell as well as the sphenoidal cell. The extent of this may vary in wide limits. A cell which seems the size of the usual sphenoidal cell may occupy the upper part, while below it the real sphenoidal cell is found. (Figs. 112, 113 and 114.) It is most important that the upper cell be opened for ocular lesions and that the lower cell be opened

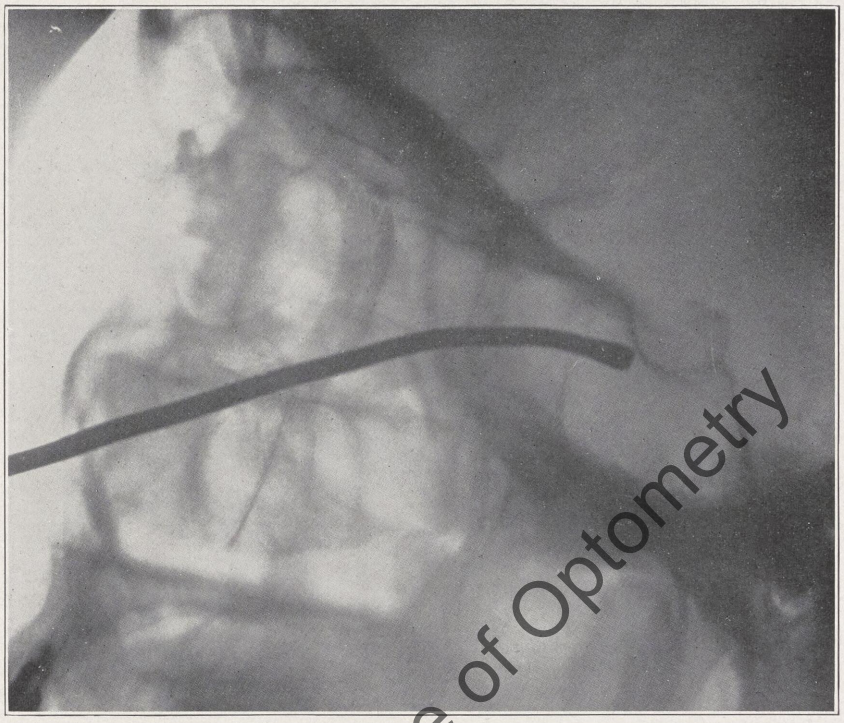

Fig. 117.—Showing probe in large undivided sphenoidal body.

for the painful lesions. It may be thought that confusion here could be avoided by attention to their outlets and utilizing them in the operation. I do not believe this to be the case. There may also be another type of subdivision; namely, anteroposterior. (Compare Fig. 115, 116 and 117.) A cell of the full height of the body may not infrequently be found which at the time of operation appears to be the veritable sphenoidal cell. Later it may be found by the picture with the probe *in situ* that the real sphenoidal cell is back of this. Once I

Digitized by Illinois College of Optometry

opened what seemed to be three cells in the body of the sphenoid, each in the anteroposterior arrangement and apparently occupying the full height of the body. Figs. 118 and 119 show a large

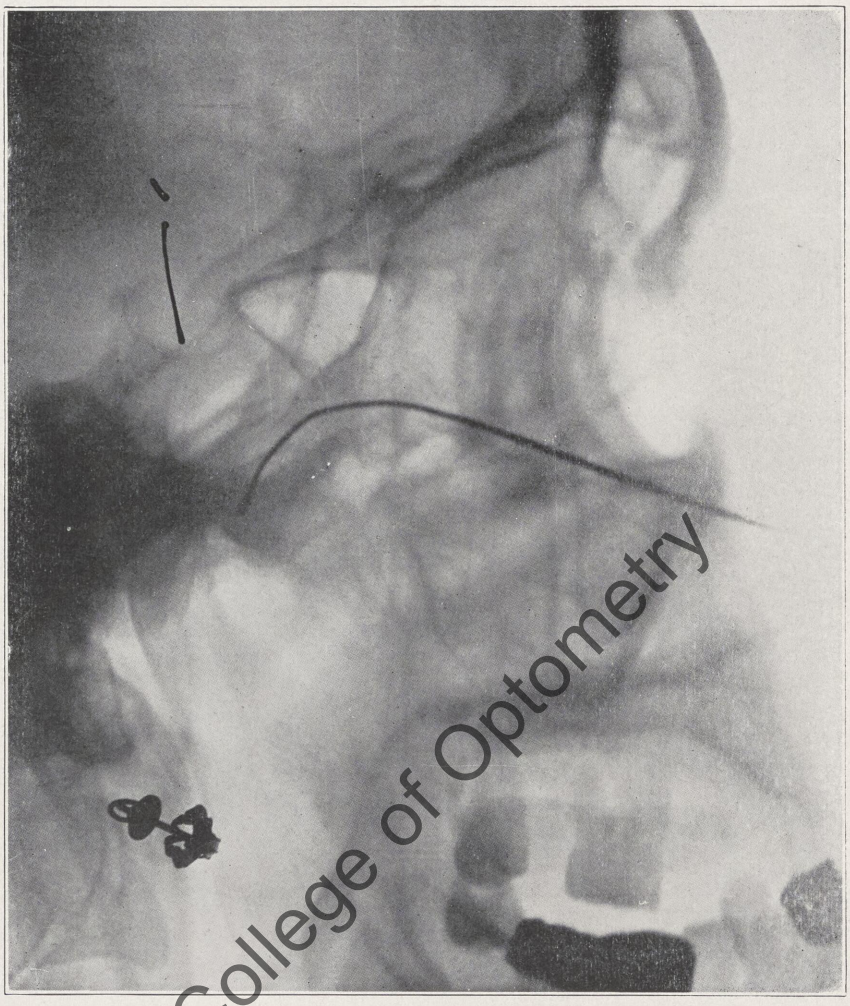

Fig. 118.—Shows probe introduced into a very large sphenoidal cell downward to the bifurcation of the plates.

sphenoidal sinus hollowed out downward into the pterygoid process to the bifurcation of the plates.

The diagnosis of these anomalies is made by taking x-ray pictures of a probe placed in the cell whose identity is in ques-

Digitized by Illinois College of Optometry

tion. Fig. 115 shows a probe in a cell which I believe every rhinologist would have asserted to be the sphenoidal cell. The picture, however, shows the sphenoidal cell below and behind it. Fig. 116 shows a probe in what I believe to have been an equally deceptive cell. It also shows another cell behind it. I

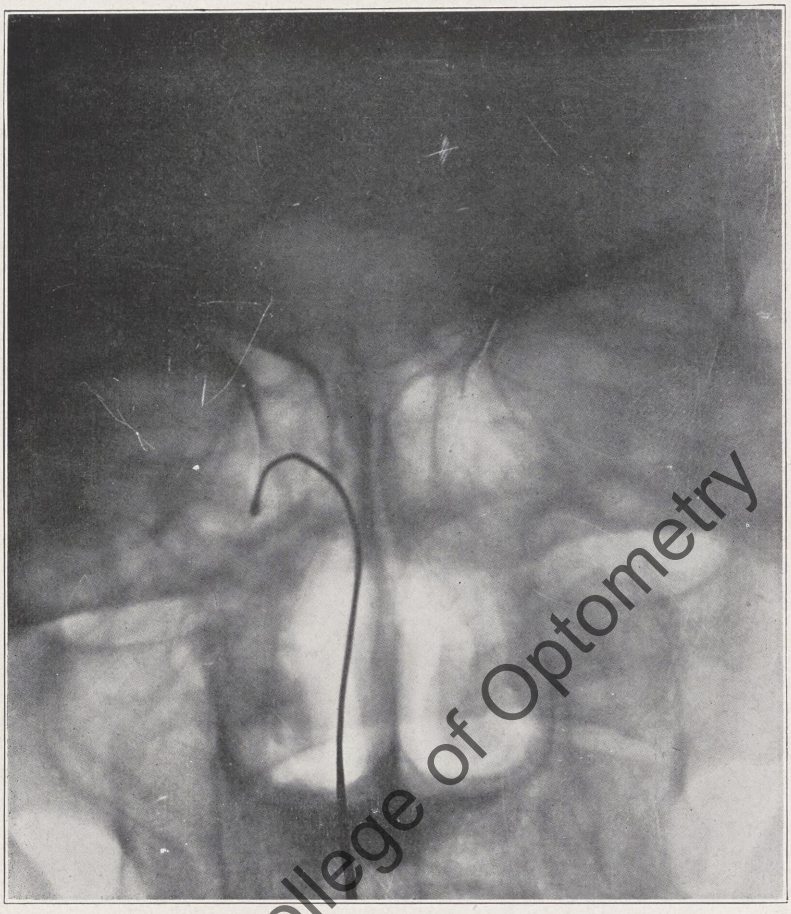

Fig. 119.—Same as Fig. 118 taken from in front.

always take these pictures in cases that have not been benefited by operation. The other cells are of course opened as soon as identified. In this way I have relieved some ocular and painful lesions where previous efforts had failed.

Another anomaly to be borne in mind is the fact that the sphenoidal cell of one side may extend into the other side and

Digitized by Illinois College of Optometry

occupy it almost completely. Such a cell will then border the optic canal of both sides. (Fig. 120.) A. Onodi pointed out that fact. But it also borders the maxillary and Vidian nerves of the opposite side. This anomaly may often be identified at the time of operation, or subsequently by x-ray pictures with probes *in situ*.

The diagnosis of hyperplastic or suppurative post-ethmoidal sphenoiditis in children is often difficult, because it is only seldom that the child may be controlled for a satisfactory post-nasal view. Should this be possible, it presents no other difficulties. A palate hook sometimes but not always facilitates

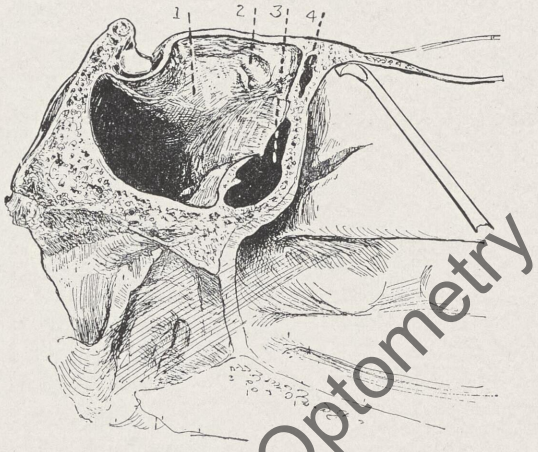

Fig. 120.—Shows the left half of specimen. *1.* Right sphenoidal sinus extending into left side to border left optic canal. *2.* Left sphenoidal sinus *3* also borders left optic canal. A post-ethmoidal cell *4* also borders left optic canal.

the examination in children. It does not always help because in the small nasopharynx of children, it is possible for the constrictors to contract and obliterate the cavity regardless of the position of the soft palate which of course may be held forcibly forward. If the child cannot be controlled for a post-nasal examination, the diagnosis is usually still possible from the anterior nares but is much more difficult. (Thick pus is easily recognizable.) I have found hyperplastic post-ethmoidal sphenoiditis to be a very frequent lesion in childhood from as early as the fourth year, producing headache and eye lesions.

A palate hook in the adult makes practically every naso-

Digitized by Illinois College of Optometry

pharynx possible of a satisfactory examination. Fig. 121 shows a palate hook that locks in position automatically and releases instantly when necessary because of cough or vomiting.

It is interesting to observe the behavior of a coryza that affects one part of the nose in full violence and leaves the other undisturbed by anything more than a slight congestion or not even that. The explanation for this cannot at present be given. It may be in some way a bacteriological phenomenon. It is probably a homologue of phenomena elsewhere; e. g., in the skin. No explanation can be given as to why measles cause one picture on the skin and secondary syphilis another. I

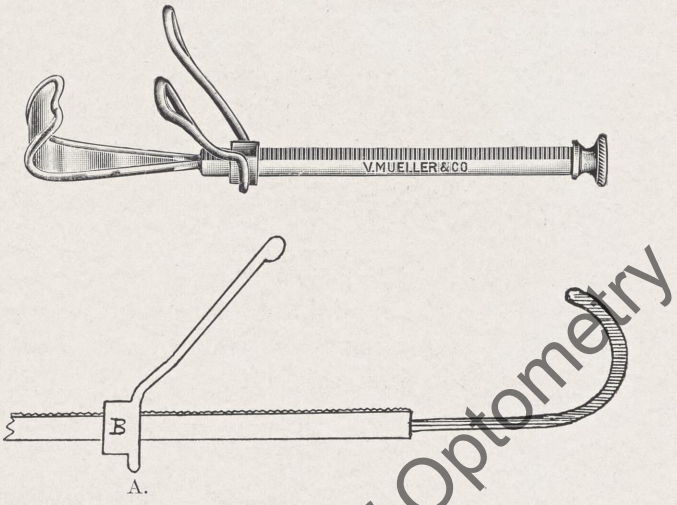

Fig. 121.—Two views of palate hook. The upper surface of the shaft is milled which provides infallible, instantaneous and secure locking when the prongs press the upper lip. The short sleeve *B* is thereby rotated upon its transverse axis locking it into the milled surface of the shaft. It is instantly released by pulling forward the tip *A*. To be had of V. Mueller & Co., Chicago, Ill.

have twice seen the prevailing localizing to be post-ethmoidal-sphenoidal in full virulence and at the same time almost uniformly leaving the anterior sinuses undisturbed. The first occasion was in St. Louis, 1905-1908; the second 1912-1916. In these years anterior sinus infections were quite rare, not only in my own experience, but in that of my colleagues who also commented on the fact. It was also true in the clinic. The ordinary coryza which affected nearly everyone, young or old, was a post-ethmoidal-sphenoidal inflammation with or without

Digitized by Illinois College of Optometry

pus. In other years anterior sinus infections have been quite commonplace. Bacteriological investigation of these problems has failed to give any information.

The question of the association of ocular tuberculosis with the nose was raised by Dr. W. H. Luedde,[1] 1901, 1923.[2] He injected tuberculin into some of his cases of ocular tuberculosis and found the reaction in the eye. At the same time I found a slight reaction in what appeared a typical hyperplastic post-ethmoidal sphenoiditis. Dr. W. M. C. Bryan and I tried to get a tuberculin reaction in other typical cases without ocular lesions, but failed.

Bacteriological investigation of hyperplastic post-ethmoidal sphenoiditis has so far been negative. The x-ray in my experience has failed to help in the diagnosis of hyperplastic post-ethmoidal-sphenoidal diagnosis. It is of paramount value in determining cell anomalies, showing probes in positions which determine these.

PROGNOSIS

Prognosis in the sphenoidal region seems to me to present features for consideration not found elsewhere. The matter of drainage here is often impossible because of an irregularly shaped (large) cavity which cannot be drained from any place in the nose or from any one place, wherever situated. Such a cavity may extend into the great and small wings, into the pterygoid process and down the sphenooccipital slope (clivus of Blumenbach), and have obstructing partitions in it. In contrast to such possibilities it is seldom that a frontal sinus is not drained by a satisfactory inlet to it. This is true for the maxillary antrum and usually for the ethmoidal cells also. The exception in the ethmoid is so rare as to be practically negligible, although it does exist. But were the difficulties in the prognosis here a question of drainage only they would be comparatively simple. Drainage or ventilation of the frontal sinus, ethmoid, and antrum is sufficient to stop pain and to effect the cure in all but very rare exceptions—these being cases of very long standing. For the hyperplastic sphenoid the best drainage and ventilation do not stop the pain except very rarely. Part of the

Digitized by Illinois College of Optometry

sphenoidal floor may be removed, which in a cell of simple arrangement gives perfect drainage. But it does not solve the problem. Some of the hyperplastic sphenoids (some of the worst) are dry. The pain in these cases is not caused by pressure of confined secretion as in an obstructed frontal empyema. It may be induced in great severity by a small area of moderate grade inflammation if situated at the proper place; e. g., at the point where the maxillary nerve passes, particularly through the foramen rotundum; namely, the lower lateral anterior part of cell, or, on the floor where the Vidian passes. I have seen this frequently with the nasopharyngoscope and I have seen such a lesion diminish the vision greatly when situated at the site of the optic canal; to wit, the upper outer anterior aspect of the usual sinus. I have seen these as the primary pictures; that is, at the time the sphenoid was opened, to disappear by treatment with recovery from the symptoms and reappear later as a localized coryza (several times in the same patient) with reestablishment of the original symptoms; namely, pain and blindness. The *degree* of *hyperplasia* in these cases is often *slight* or even *nil.* I have construed them as *having very thin walls separating the maxillary, Vidian and optic nerves. Any disturbance in the cell quickly affects these neighboring nerves by the inflammation or its toxin passing through the bone and membrane to the nerves. This argument is also borne out by therapy. These are the patients who are most quickly and satisfactorily helped by antiphlogistic and analgesic applications within the cell.*

In sharp *contrast to these cases* are others *where upon opening the cell the membrane is thick, rough and dry with no markings at the sites of the maxillary, Vidian, or optic nerves. The hyperplastic bone process is shown by the microscope to be well marked. Therapy in these is disappointing or at least very slowly satisfactory.* Months pass with the best efforts of the rhinologist almost in vain. Continued effort however over a period of several years will usually show a slow improvement. At the end of a year and a half to three years the patient shows definite improvement. Were the *eye* disturbance slight it *may have recovered.* Were it *more than slight* it would be *considerably better.* Were it *headache* it may have so far *recovered*

Digitized by Illinois College of Optometry

that the patient has *much time free of pain.* Coryzas of any grade reestablish the headache more or less. I have construed these *not as simple inflammation or toxin transmission lesions, but as thickening bone lesions with consequent narrowing of the canals through which the nerves pass.* Part of the narrowing may be a periostitis in the canal. But with or without periostitis *the increase of the bone volume must encroach on the canals.* Such a *narrowing means pressure on the nerves with pain. Long continued therapeutic effort will finally reduce the volume* to some extent. And furthermore in later years the rarefying state ensues and further helps the patient. I believe this is what happens when the patient begins to improve spontaneously some time after the fiftieth year as has been observed by neurologists in cases of migraine. The migraine gets better without operation.

Secretion and gravity apparently play a definite part in the first class of cases. The watery secretion gravitates to the lower part of the cell away from the optic canal. This seems to me to explain the greater number of headaches and the smaller number of ocular lesions (as previously stated). The optic canal is almost never separated from the post-ethmoidal or sphenoidal cells by any considerable thickness of bone, whereas the maxillary and Vidian are, in a percentage of cases. The percentage is not large according to my observation but I cannot now put it in figures.

It appears to me to follow in logical sequence that in the first class of cases the prognosis is for speedy relief from the symptoms, and that they must necessarily be reestablished at the time of a coryza. The infection "coryza" in these parts may be of grades so slight that the patient is not cognizant of it and still cause the ocular or the painful lesions. The acutely inflamed area may however be seen with the pharyngoscope after the cells are opened. And for the second class of cases the prognosis is also for relief but it must needs be slower and less complete, although in the *long run the result is preeminently worth the effort* it took to get it. These cases have seemed to me to be less disturbed by coryzas.

The post-ethmoidal-sphenoidal radical operation properly performed in the first class of cases almost always gives a tech-

Digitized by Illinois College of Optometry

nical result that remains satisfactory; that is, the openings of the cells remain as the operator makes them. In the second class they almost always get smaller and very frequently close up completely, and so must be made again, often several times.

In later life an involution of the hyperplastic changes—rarefying osteitis—takes place, sometimes beginning about the fiftieth year and sometimes later. I have seen this in unoperated cases accompanied by corresponding cessation of symptoms, (in one case an ophthalmic migraine in a man). I have tried Tiersche grafts in the sphenoid at the time of operation but the cases are too few and the results not of sufficient duration to permit of a conclusion as to whether or not they help in the prevention of subsequent closing. My impression at present is that they do not help.

TREATMENT

The relief of low grade hyperplastic post-ethmoidal sphenoiditis whether for headache or eye lesions, in my experience, has often been accomplished by the sedulous use of a one and one-half or two per cent alkaline saline solution twice or thrice daily snuffed from the palm of the hand, and the face then quickly turned up so as to make that region the lowest part of the nose, to be flooded by gravity. The same result is secured by the use of a douche which pours into the nose. That necessitates the face being turned up to begin with. I use an ancient English mixture, sodium chloride, sodium bicarbonate and sugar of milk* equal parts. I prefer to have this made into tablets of known weight for the convenience of the patient. They are added to water to make the solution one and one-half to two per cent. That solution is definitely heavier than the blood serum and must set up an osmotic current away from the tissues. That strength is at the same time nonirritant. It diminishes the volume of the tissues without irritation or reaction such as follows stronger astringents or adrenalin solutions. It is of course cleansing also, but other solutions may be so too, and not accomplish the end if they irritate. This

*Sugar of milk seems to make the solution pleasanter in the nose. It is not necessary.

Digitized by Illinois College of Optometry

is moreover exemplified by the same solution if it is too weak or too strong, either of which irritates.

The occasional application of a two per cent silver nitrate solution in small amount is also helpful. A solution of phenol 1 c.c., liq. iodi comp. 4 c.c., water 200 c.c., is helpful occasionally applied in 5 c.c. amounts by means of a syringe, the point of which is placed in the olfactory fissure at about its middle. It is injected with some force. But more satisfactory, in my experience, is the daily use of one-half or one-third per cent solution of phenol in oleum petrolatum; 5 c.c. amounts are injected forcibly into the olfactory fissure by a syringe (fine point) placed in the fissure at about its middle. This is painless and provokes no reaction. I have proved on the cadaver that some of the solution thus instilled enters the post-ethmoidal and sphenoidal cells in skulls where the openings are of the usual size. This oil is furthermore thick enough to remain in its place for some time (one-half to two hours), which helps its effect. When the pain is severe a solution of one-half per cent cocaine alkaloid in oleum petrolatum may be thus instilled. Both the phenol and cocaine are analgesic. *Many low grade recent cases* (with headache or eye lesions) are satisfactorily treated by these means. The question arises here, naturally, "Why not instill the solution into the sphenoid by cannula?" One reason for not adopting this as a routine plan is that the daily effort for this purpose in the average nose, inflicts a degree of trauma that is followed by too much reaction to secure the desired effect. Another reason is that the opening of the sphenoid is often so placed that it cannot be catheterized while the middle turbinate is in place. When the patient cannot be treated by the rhinologist, I give him the phenol oil mixture to pour into his nose as he does the alkaline saline solution, not believing however that it in this way, enters the sphenoid. Ventilation seems to have a direct effect in controlling hyperplasia, or at least I once thought so. Latterly, I have seen cases where this is apparently not true.

The suction treatment advocated by Coffin and Harmon Smith for the suppurating sinuses cannot be of help for these cases because they are not suppurating cases. Some have a

Digitized by Illinois College of Optometry

scant thin secretion that could not be sucked out of the lower part of the sphenoid and many are without any secretion.

Proetz[2] has devised a method of treatment of the sphenoidal and posterior ethmoidal cells which is known as displacement irrigation. By the use of iodized oil the same procedure may be employed to fill the sinuses, so as to outline them with the x-ray.

The osteum of the sphenoid is sometimes inaccessible but by the method of Proetz the sinus may be filled with medicated fluids. It has proved to be a beneficial method of treatment in certain selected cases.

The method as described by Proetz is as follows:

"Displacement irrigation depends upon the exhaustion of air from the sinus and its replacement, through the agency of a partial vacuum, with fluid held in apposition to the sinus opening by gravity.

"The degree of vacuum often employed in attempts to empty the sinuses by simple suction, if not actually injurious to the membrane, at least produces a hyperemia which swells the membrane about the ostium and defeats its own purpose. Furthermore, unless conditions within the sinus are mechanically ideal, which they rarely are, and unless the sinus is placed in the proper position relative to its ostium, simple suction cannot possibly accomplish satisfactory evacuation.

"By displacement, small amounts of air are withdrawn at a time from the sinus by application of mild suction to the nostril. These air bubbles are replaced by droplets of whatever fluid overlies the ostium. Each alternation of pressure introduces only a small amount of fluid, but by repeating the manipulation a number of times the entire sinus may be filled. It is important to place the head in such positions that the fluid in the nasal chamber is kept by gravity in contact with the ostium.

"One of two positions is employed. The supine position is the one of choice for general examination and treatment. In this position filling of the posterior ethmoidal and sphenoidal cells is more easily accomplished. Some filling of anterior ethmoidal and maxillary sinuses occurs at the same time, usually

Digitized by Illinois College of Optometry

sufficient for diagnosis or treatment. The frontal sinuses are most difficult of penetration, owing to the proportions of the *infundibulum ethmoidale,* and for this purpose the prone position is preferable.

"The routine procedure in the supine or sphenoethmoidal position is as follows:*

"1. The patient is placed in the supine position, with his head projecting beyond the top of the treatment chair or table. The occipitoatloid joint is extended until the tip of the chin and the external auditory meatuses are in the same vertical plane. This renders the sphenoidal sinus, with its ostium upturned, the most dependent structure in the nasal chamber. A 'V' shaped pocket thus occurs at the junction of the face of the sphenoid with the cribriform plate of the ethmoid. (Fig. 122.)

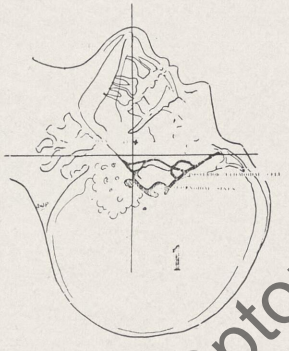

Fig. 122.—Diagram indicating the correct position of the head for displacement irrigation. The tip of the chin lies in a vertical plane with the external auditory meatus. The parts immediately concerned are heavily outlined. Note the slope of the posterior pharyngeal wall. (A. W. Proetz, Annals of Otology, Rhinology and Laryngology, June, 1927.)

"2. The fluid to be introduced is now allowed to flow into the nostrils from a syringe and comes to rest in this pocket, submerging the ostia of the posterior sinuses. It does not enter the sinuses, as their ostia are of insufficient size to permit the escape of the contained air. (Fig. 123.)

"3. Gentle suction is now applied intermittently to one nostril, the other being closed, the palate and tongue being held in the 'K' position to seal the pharynx. Any of the ordinary vacuum appliances will suit, provided that the degree of tension

*Proetz, A. W.: Displacement Irrigation of Nasal Sinuses, Arch. Otolaryngol., July, 1926, iv, 1-12.

Digitized by Illinois College of Optometry

can be controlled. When the suction is first applied, a bubble of air escapes from the sinus through its upturned ostium. On releasing the suction this air is replaced by a drop of the overlying fluid. The process is repeated until the sinus is full; about a dozen alternations usually suffice to accomplish this. (Fig. 124.)

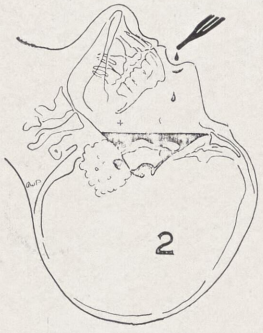

Fig. 123.—The introduction of fluid into the nostril. It comes to rest in the nasal chamber, and submerges the ostia, but does not penetrate the sinuses, as the ostia are too small to permit the interchange of fluid and air. (A. W. Proetz, Annals of Otology, Rhinology and Laryngology, June, 1927.)

Fig. 124.—Intermittent suction is applied at the nostril, withdrawing bubbles of air from the sinuses and permitting their replacement with drops of the overlying fluid. Sphenoidal and posterior ethmoidal cells are shown half filled. (A. W. Proetz, Annals of Otology, Rhinology and Laryngology, June, 1927.)

"4. The patient is returned to the erect position, and the fluid remains *in situ* for an indefinite period (eight hours to several days). (Fig. 125.)

"For injection in the prone position, the patient leans forward or lies face down on a table with the nasofrontal suture and the upper incisors in the same horizontal plane.

Digitized by Illinois College of Optometry

"Two or three mils of fluid are introduced into one nostril with a syringe which fits it closely. On withdrawing the syringe, the nostril is held shut with the finger to prevent the escape of the fluid. Intermittent suction is now applied to the other nostril until the fluid has entered the sinuses. More fluid is introduced if desired, and the process repeated. Injection in this position is accomplished by virtue of the anatomical relation of the posterior margin of the septum to the ostia of the

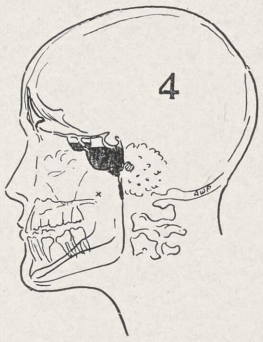

Fig. 125.—Patient returned to the erect position. The fluid remains in the sinuses. (A. W. Proetz, Annals of Itology, Rhinology and Laryngology, June, 1927.)

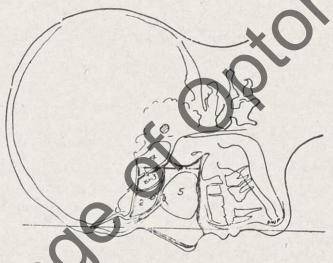

Fig. 126.—Diagram illustrating the prone position for displacement. Again the parts concerned are heavily outlined. If one nasal chamber is filled to the dashed line and its nostril closed, all ostia on that side will be submerged without spilling the oil over the margin of the septum into the other chamber. This other chamber can then be utilized for the vacuum application through the nostril. (A. W. Proetz, Annals of Otology, Rhinology and Laryngology, June, 1927.)

sinuses. With the head in the prone position it is possible, by filling one nasal chamber through the nostril, to submerge all the ostia before any of the fluid spills over the posterior margin of the septum into the other chamber. This septal barrier, there-

Digitized by Illinois College of Optometry

fore, keeps the opposite nasal fossa free from fluid and available for the application of suction. (Fig. 126.)

"The frontal sinus, as has been stated, is the most difficult to fill, as its outlet is long and narrow, and bubbles of air are not readily displaced from it. This condition exists also, and fortunately to an exaggerated degree, in the middle ear and the eustachian tube. This tube is a collapsed membranocartilaginous passage in its pharyngeal portion, and so narrow that no air is withdrawn from the middle ear when the vacuum is applied.

"For treatment the following routine of detail has been adopted because it has proved the most effective in its results, and occasions the least discomfort to the patient.

"It is advisable before beginning treatment to render the ostia as free as possible, and a mild general shrinking of the membrane with 1 per cent cocaine or 3 per cent ephedrin sulphate is resorted to. In case the irrigation is intended for a single cell or group of cells, only the region in question is subjected to astringents.

"The patient sits in a small treatment chair, with a back which can be dropped into a horizontal position. The operator sits on a stool behind him, with a towel in his lap, upon which to rest the patient's head. This towel also serves to catch any drop of fluid which may escape from the syringe or the nose and which will find its way into the patient's eye if not quickly caught. This is an especially important precaution with children.

"The back of the chair is let down and the patient's head rests on the operator's knees. In this way the position of the head can be readily adjusted, so that the chin and ears are in a vertical line. The suction apparatus is held in one hand while the other manipulates the nostril during suction and introduces the fluid from the syringe, which is preferably refilled as required by an assistant. It is important to hold the patient as steady as possible, for if he becomes apprehensive and raises his head fluid escapes into the larynx and sets him coughing. For the same reason it is preferable to introduce small amounts of fluid at a time and repeat as often as desired. Two mils in each nostril at a time is usually tolerated well.

Digitized by Illinois College of Optometry

"The solution should be nearly body temperature. Warm fluids are better than cool ones, and introduction along the septum is more comfortable and effective than against the lateral wall of the nose.

"Any suction apparatus suffices, provided the degree of vacuum can be controlled. Electric or water pumps are preferable, as their action is continuous and can more easily be made to coincide with the closing of the patient's pharynx. The degree of vacuum necessary to effect the introduction of the fluids varies. It should be quite low in any case; never enough to cause the slightest pain.

"A glass-barreled rubber bulb syringe has been designed whose barrel is calibrated at five and ten mils, and whose bulb produces just the required vacuum for the purpose.*

"The alternations of vacuum and its release should be slow, say one cycle per second, in order to permit the complete disengagement of the exhausted air bubble from the ostium. This is especially important in the use of lipiodol, as it is viscous, and bubbles rise slowly through it.

"The patient should be urged to maintain his palate in the 'K' position throughout the procedure, and to breathe through his mouth. As he sits up, the towel on the operator's lap is given him to catch any fluid which may escape from his nose. He should be instructed not to blow it, but to allow the solution to remain *in situ* as long as possible.

"Children and others in whom it is difficult to effect a closure of the pharynx (the 'K' position) to maintain suction, should be told to open the mouth wide. This usually produces the desired result, as does the crying of children.

"The choice of solutions depends upon the individual requirements of the case. There are certain limitations to be considered, however, which do not apply to simple nasal irrigation.

"Any solution which is to be introduced into a sinus must be nonirritating, or the result will be a headache which may be severe and intractable. Furthermore, since the solution is to remain in contact with the membrane for an indefinite and comparatively long period, it must either be stable, or its break-

*Proetz, Arthur W.: A Special Syringe for Displacement Irrigation of the Nasal Sinuses, Arch. Otolaryngol., November, 1926, iv, No. 5, p. 424.

Digitized by Illinois College of Optometry

ing down products must be nontoxic. Apparently the greatest single function to be accomplished by fluids introduced into sinuses for treatment is the mere mechanical dilution and detachment of the secretions, rendering them less toxic and more easily removed by the physiologic agencies of drainage. For this purpose the lotion of choice is sodium chloride solution. In many cases no further treatment is required.

"Imperatori* employs a solution of sodium chloride and sodium bicarbonate, and instructs the patient in the use of the method at home with the aid of the rubber bulb suction syringe.

"In atrophic rhinitis with troublesome crusting, liquid petrolatum is especially useful, as are also dilute solutions of glycerin. These aid mechanically to prevent the formation of crusts and their attendant fetor. Adams† reports eight cases treated with one-half per cent mercurochrome suspended in liquid petrolatum. All obtained considerable relief from crusting and dry throat.

"The best results, from all standpoints, have followed the introduction of a weak solution of ephedrin sulphate. It ranges in strength from 0.1 to 0.5 per cent in physiologic sodium chloride solution. It has the advantage of being stable, and as it is liberated from the ostia in small amounts over a period of many hours, it establishes and maintains drainage effectively. No unpleasant after effects have been noted. Neither adrenalin nor cocaine have been employed.

"Of bactericides no more is to be expected than to prevent bacterial growth in the sinus contents, although Holmes‡ reports favorable results with neosilvol, which he employs as strong as 10 per cent. It is his experience that after the headaches disappear there is relief from the original symptoms. Dilute aqueous solutions of phenol and iodine are well tolerated, especially in chronic conditions.

"With the idea of digesting thick viscous secretions within the sinuses and permitting them to drain more readily, I have introduced enzymol solutions and suspensions of caroid in glycerin and water, but the advantages of these over the saline solu-

*Imperati, Chas. J.: Personal communication dated March 12, 1927.
†Adams, Frank M.: Personal communication dated March 15, 1927.
‡Holmes, W. W.: Personal communication dated April 1, 1927.

Digitized by Illinois College of Optometry

tions were not apparent. These observations included a few cases of atrophic rhinitis with crusting.

"Instances are reported of relief from headaches immediately following the injection of lipiodol for diagnostic purposes. Granger* mentions a case in which there was continuous headache, day and night, for four weeks, which disappeared promptly and completely following an injection of lipiodol for diagnosis.

"Potts† cites the case of a woman in whom an incessant headache of several weeks' duration was similarly relieved. I have encountered several such instances. In one or two the relief was permanent.

"These are isolated cases, and while no conclusions may be drawn from them, they deserve mention.

"It appears that the best results, from the standpoint of cures, are to be expected in those cases which have passed the acute stage, but in which a swollen mucosa interferes with drainage and a purulent discharge continues over an indefinite period of time. Such cases frequently recover after a few irrigations.

"Chronic cases in which extensive tissue changes have taken place cannot be expected to yield to irrigation. The relief from symptoms, however, is often pronounced and immediate. Persistent post-nasal dripping, dryness and headaches frequently improve or disappear.

"Old post-operative cases with extensive scarring and an annoying discharge are made comfortable.

"W. L. Post‡ reports results in twelve patients who have improved or recovered under irrigations with normal sodium chloride or a solution of phenol (0.6 per cent) and iodine (0.1 per cent) in petrolatum. In five of these some eye disorder was the outstanding complaint. Each of them exhibited a subacute nasal inflammation and all were relieved of symptoms. One case of iritis, which became steadily worse under atropin locally and nasal irrigations, began immediately to improve when the displacement method of nasal irrigation was substituted for the ordinary method, although the same solutions were used. Of the nasal cases, subacute inflammations disappeared promptly

*Granger, Amedee: Personal communcation dated December 1, 1926.
†Potts, J. B.: Personal communication dated April 30, 1927.
‡Post, W. L.: Personal communication dated May 1, 1927.

Digitized by Illinois College of Optometry

and entirely; in hyperplastic types relief from symptoms was accomplished.

"Similar results were noted in a series of nine cases treated by Truex.* Four patients with subacute posterior sinus disease recovered completely; two with subacute and three with chronic sinusitis obtained relief. One of the latter was a case of atrophic rhinitis. The subacute cases were of three to six weeks' duration, and not more than five treatments were administered in any case.

"Radiopaque substances introduced into sinuses for diagnosis must be bland and fairly fluid; and they must be nontoxic to the sinus mucosa and to the digestive tract as well.

"So far the most satisfactory shadows have been obtained from a mixture of equal parts of lipiodol† and olive oil. This mixture is nonirritating and headaches have not followed its use. Its viscosity is relatively low, and it does not produce the dense metallic shadows of the pure lipiodol. This is an advantage in that the outlines of overlapping cells can be distinguished, and in many cases filling defects produced by cysts or polyps can be seen which are completely masked by the undiluted oil.

"Some of the silver salts ordinarily used in treatment are fairly radiopaque. In a series studied by McMahon, neosilvol was found to cast the densest shadow. A 20 per cent solution of this salt is about one-half as dense to the x-ray as the diluted lipiodol mentioned above. Ordinary liquid petrolatum is practically transparent to x-rays and may be employed for flushing the nasal chambers to remove any excess lipiodol before making the pictures.

"In introducing these oils by displacement, the alternations of suction and release should be somewhat slower than for treatment solutions on account of their greater viscosity.

"From five to ten mils of the oil are instilled. After its introduction it usually remains in place for some time, so that the injection may be accomplished in the laryngologist's office

*Truex, E. H.: Personal communication dated April 30, 1927.

†Sicard and Forestier: Iodized Oil as a Contrast Medium in Radioscopy, Bull. et mem. soc. med. d. hop. de Paris, 1922, xlvi, 463.

Digitized by Illinois College of Optometry

and the patient sent to the x-ray laboratory at some distance. He should be cautioned against blowing his nose in the interval.

"A mild saline cathartic is usually administered after an examination with lipiodol.

"In making a diagnosis by this method the correct relations of head, x-ray beam and film are of paramount importance. The horizontal x-ray beam is the preferable tube position.

"It is not always possible and seldom desirable to effect a complete filling of the sinuses with iodized oil, and consequently two positions are necessary to exclude abnormalities of the entire sinus wall.

Fig. 127.—Lateral plate made in the position in which the displacement was done. (Horizontal x-ray beam.) It outlines the upper half of the cells. (A. W. Proetz, Annals of Itology, Rhinology and Laryngology, June, 1927.)

"The original sphenoethmoidal position in which the oil was introduced is a convenient one for the lateral exposures (Fig. 127.) An additional lateral film should then be made after a sagittal rotation of 180°. That is a nearly erect position, with the external auditory canals this time above the chin but still in a vertical plane (Fig. 128). The x-ray beam remains in the same lateral horizontal direction.

"Posterior anterior views with the beam still horizontal have given the best results in the observation of frontal and maxillary sinuses; the lateral position for ethmoids. Stereo-

Digitized by Illinois College of Optometry

scopic plates with lipiodol prove must useful in delineating the topography of the cells.

"In regard to the technic of exposure, Ernst* says:

" 'For the average lateral skull examination we adopt a comparatively simple radiographic technique, limiting the fine focus radiator tube to 10 milliamperes and five seconds' exposure. The average potention approximated 76 to 80 K. V. (4½ inch spark gap) at an anode film distance of 28 inches. The exposure time was doubled in the posterior anterior or semilateral views. By means of this radiographic formula clear and distinct radiograms are uniformly obtained. The diag-

Fig. 128.—The same as Fig. 127, in the erect position. This plate indicates the extent to which 10 mils of oil may penetrate the cells at a single filling. The re ation of dental root and antrum is of interest. (A. W. Proetz, Annals of Otology, Rhinology and Laryngology, June, 1927.)

nostic value is relatively dependent upon sharp and contrasting negatives, showing absolutely no movement. Therefore, complete immobilization is the final radiographic requisite in the various positions of the head above described.' Plates held against the patient's head by an assistant while the exposure is being made rarely prove satisfactory. They should be supported by some rigid mechanical contrivance.

"In the matter of interpretation of the negatives made by this method, I wish to maintain the utmost conservatism; still,

*Proetz, A. W., and Ernst, E. C.: Sinus Mapping by the Displacement Method, Radiology, June, 1927.

Digitized by Illinois College of Optometry

after the experiences of a little more than a year, I feel that the method offers at least these two distinct advantages: first, that no cells are overlooked in the filling, and second, that the readiness with which they fill and empty themselves of the oil is an index of their drainage, which is of prime importance in determining the type of treatment. To quote from a previous report:* 'It is frequently impossible to locate the ostium of a sinus, especially in the presence of hyperplasia, and puncture must be resorted to. This in itself is undesirable, aside from the obvious fact that only those cells which are encountered by the trocar are injected. By the displacement method the oil itself

Fig. 129.—Lipiodol mapping of a sphenoid, which observed empty showed no abnormalities. The thin white line between the floor of the cella turcica and the oil is interpreted to indicate a thickened membrane, as is the translucent strip on the right (floor of the sphenoidal cell). This was verified at operation. (A. W. Proetz, Annals of Otology, Rhinology and Laryngology, June, 1927.)

seeks them out. All cells from which a bubble of air can be extruded are at least partly filled, and from this circumstance arises an important diagnostic indication, namely, that the facility with which the oil penetration occurs is a direct index of the patency of the ostia. Not only can general obstruction to drainage be demonstrated but individual cells are shown to

Digitized by Illinois College of Optometry

be obstructed while others are clearly free. Many cases are encountered in which a posterior ethmoidal sinus, for instance, fills readily, while its adjoining sphenoid fails to fill at all, although the oil levels in the normal cells show the head in the proper position and the diseased ostium properly submerged.'

"If a sinus fills readily under mild suction, it may be safely assumed that it drains freely under ordinary circumstances, regardless of apparent obstruction by turbinal and septal distortions. On the other hand, if a cell fails to fill it may be

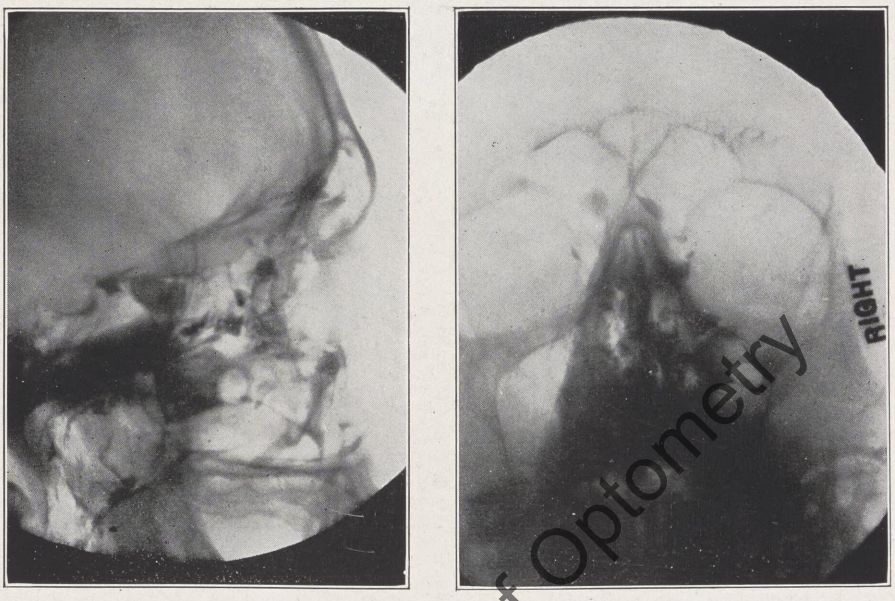

A. *B.*

Fig. 130.—(*a*) Lateral and (*b*) posterior anterior views of the right maxillary sinus, showing an intrinsic filling defect. Unilateral filling in prone position, five mils, oil. (A. W. Proetz, Annals of Otology, Rhinology and Laryngology, June, 1927.)

deduced that its ostium is not normally patent, as the other factors involved in the instillation can be readily controlled.

"Hyperplasias of the sinus mucosa, in order to be visible on the plates, must obviously be macroscopic in extent (Fig. 129), and for this purpose absolute fixation of head and film is necessary. But lesser hyperplasias which cannot be so demonstrated may manifest themselves by the failure of the ostium to admit the fluid. Such plates occur not infrequently in our series.

Digitized by Illinois College of Optometry

Gross hyperplasias, cysts, polyps and foreign bodies are, of course, distinctly outlined (Figs. 130 and 131).

"The factors which determine the entrance of the oil into a cell are suction, apposition of oil to the ostium, fluidity of oil, patency of the ostium and presence of air in the cells to be displaced. As all but the last two can be readily controlled, nonfilling under proper technique indicates an obstructed ostium

Fig. 131.—Typical intrinsic filling defect of the right maxillary sinus. Unilateral instillation in prone position five mils oil. Exposure with head erect, x-ray beam horizontal. Only a small amount of oil entered the sinus, owing to the presence of a mass of polyps. The thin sheet of oil resting on the top of these, photographs densely because the beam traverses it horizontally. Note similar density of the drop on the velum palati. (A. W. Proetz, Annals of Otology, Rhinology and Laryngology, June, 1927.)

or a cell filled with some exudate or other matter. In any case in which some cells fill and others do not the presumption is that the nonfilling cells are the diseased ones.

"Instances are encountered of the unusually extensive pneumatization of the pterygoid process of the sphenoid, to which Sluder* recently directed attention in connection with eustachian salpingitis.

*Sluder, Greenfield: Two Factors in Catarrhal Deafness: The Lower Turbinate and the Sphenoidal Sinus. Paper read before the seventy-seventh annual meeting of the American Medical Association, Dallas, April, 1926.

Digitized by Illinois College of Optometry

"Mullin* has injected a pneumatized posterior clinoid process."

Low grade hyperplastic sphenoiditis has sometimes been benefited by the removal of the tonsils, particularly in cases accompanied by slight secretion of apparently purulent character. Examinations of these cases later showed the sphenoidal lesion unchanged. Headaches in these cases return, but sometimes not so often or so severe.

Mention should be made of change of climate or atmospheric or hygienic conditions as possible therapeutic influences. I have so far failed to recognize these as in any way potent factors for or against the development of hyperplastic post-ethmoidal sphenoiditis. Occasionally a patient thinks he is benefited by a "change of some sort."

Much has been written of late years on the benefits obtained from the use of vaccines of various sorts. Repeatedly I have tried vaccines, sometimes autogenous and sometimes stock, in cases of headache of ganglion and sphenoidal origin, and many otalgias that were apparently of sphenoidal origin. I regret to say, however, that so far I have had no success.

Should these means fail the sinuses should be opened. For this purpose intranasal surgery if properly done seems to me to offer all that is possible. Extra nasal surgery in some old and far advanced degrees of pathological alterations, (suppuration, granulation and necrosis) of the cavities, may offer possibilities beyond those of intranasal surgery. But in these cases of hyperplastic post-ethmoidal sphenoiditis, such conditions, so far as I know, are never found. The most advanced change I have so far found has been a broad based edematous, polypoid swelling without pus or recognizable secretion. This has usually subsided after opening the cells.

There is constantly a problem with these cases, in getting them mixed with the intracranial lesions. The subject is rather extensive. The reader is referred to the article of Dr. Harvey Cushing who laid a blanket charge upon the rhinologists as careless and incompetent. I attempted to explain some of the difficulties besetting the practice (Sluder[32]). Possibly if every case could be examined by an accomplished neurologist, as well

*Mullin, W. V.: Personal communication, dated May 1, 1927.

Digitized by Illinois College of Optometry

as an accomplished rhinologist, there would be less confusion. The question of operative technique and the meningitis which sometimes follows it, which Dr. Cushing denounces, is also beset with great difficulties in the present state of medical training.

In the course of Dr. Cushing's comment he stated that the lower half headache (Sluder's neuralgia) was in his opinion a spill-over from trigeminal neuralgias. It is inconceivable to me now as it was then[32] how they can be spill-overs from trigeminal neuralgias. Many of them have no pain in the trigeminal area. I have often noted that pain between the shoulder blades was the only pain present. The entire district supplied by the trigeminus is free of pain and the posterior half of the lower half headache is often present without the anterior half.

In the course of twenty-five years of practice which includes teaching in the Clinic at Washington University Medical School, I perforated the cranium in only one instance (1923). Both sides of this patient's nose were operated upon and were apparently identical. The patient died of a pneumococcus meningitis. Autopsy revealed a perforation ½ mm. in diameter on the right side in the post-ethmoidal-sphenoidal district. With this fact however lamentable it should be recalled that as a percentage it is exceedingly small, and this speaks much for the safety of this method of operation.

H. W. Loeb (1922)[2] has made a most comprehensive and thorough review of fatalities following operations upon the nose and throat not dependent upon anesthesia. This study consisted of 332 hitherto unreported cases. Meningitis was found to be the most common cause of death (125 cases) and hemorrhage the next most common cause (55 cases). In more than one-third of the cases of meningitis operation upon the ethmoid, with or without resection of the middle turbinate, was given as the cause of death. Since most of the ethmoid operations were accompanied by operation on the sphenoid the reports on the latter sinus did not materially differ. One fatality was reported from an intranasal antrum operation and fifteen from simple resection of the middle turbinate.

In the group of deaths from hemorrhage most of them were

Digitized by Illinois College of Optometry

due to tonsillectomy. Four fatalities resulted from sinus operations.

In his conclusions Loeb emphasizes: (1) the importance of a thorough knowledge of the anatomy of the nose; (2) the selection of the patient for operation; (3) technique and asepsis, and (4) post-operative care.

Surgery of the Paranasal Cells

The upper paranasal cells may be approached by two intranasal routes—an anterior and an internal. The anterior was probably sought in an effort to save the middle turbinate. It was first utilized by M. Schaeffer who punctured the wall of the nose anterior to the middle turbinate with a small curette. This usually enters the agger nasi or a prefrontal cell of the ethmoid. Through this he reached the uncinate process and removed it to gain entrance to the frontal sinus. He then proceeded backward to open the ethmoidal cells and further backward to open the sphenoid, operating in a direction from in front upward and backward, in a plane lateral to the middle turbinate which was left *in situ*. This was done with the desire to save the turbinate for its function. If this were not the idea of Schaeffer it has been that of its subsequent advocates (Uffenorde,[2] Pratt, and many others). Schaeffer's text is not clear as to whether he removed the uncinate process. Uffenorde, however, is very clear. The only condition in which that procedure seems to me advantageous is where there is an unusually wide middle meatus with a correspondingly wide nasal fossa. Here it is advantageous to save the middle turbinate to avoid subsequent drying.

I am one of those opposed to this procedure for several reasons. First, it is by no means the rule that it is the cells themselves that are diseased; e. g., a normal turbinate may be crowded to the lateral wall by a septum tubercle combined with a slight deflection or swelling; or hypertrophy of the turbinate may exist blocking some secretion which stops as soon as drainage is given. Second, in an active hyperplastic process that has included the bone in its activities, the use of the curette is followed by great bone reproduction which defeats the object.

Digitized by Illinois College of Optometry

Under these conditions it has been much more satisfactory to remove by a clean cut the diseased tissue, which can be done by the internal approach. Third, the anterior approach must be more dangerous than the internal approach. The latter removes the middle turbinate by a cut of the tissues from above and behind downward and forward instead of from below and in front upward and backward. Fourth, the internal approach may be most conservative. The removal of the middle turbinate takes as it were, the flap valve off the normal outlets of the frontal, maxillary antrum and anterior ethmoid. The more these outlets are left undisturbed, that is, the less their epithelial covering is injured, the more satisfactory the results. In cases of advanced disease—suppuration with granulations and necrosis—obviously all the tissues must be removed. But in simple suppuration simple drainage suffices. For these reasons my choice is the internal approach. This consists primarily in the removal of the middle turbinate which lies over (internal to) the openings of the frontal, anterior ethmoidal and maxillary cells. The simple removal of the pendulous turbinate must be considered the simplest and most conservative procedure.

The argument is made that it is desirable to conserve the turbinate. Experience here, however, proves that the removal of the turbinate is not followed by drying or the sensation of cold from the inspired air, as might be argued on theoretical ground; nor by any other disturbance within the nose. The next step in the direction of radical procedure is the high (cribriform) cut on the lateral wall which removes the innermost part of the ethmoidal capsule as well as the middle turbinate. This opens the prefrontal cells, the complete infundibulum and the nasal wall of the remaining ethmoidal cells. The complete radical procedure removes the remaining part of the floor of the frontal sinus with the remaining part of the ethmoidal capsule, leaving the paper plate. Mosher's[1] operation takes the anterior route but utilizes the middle turbinate as a landmark or guide, and then removes it. As a finished procedure the radical intranasal operation for the upper paranasal cells is rendered safer by utilizing the turbinate as a guide. I do not, however, believe that any anterior approach can be as safe as the internal. Pratt objects to the sacrifice of

Digitized by Illinois College of Optometry

the middle turbinate because the incision must needs open the sheaths of the olfactory nerve branches in the nose and thereby open channels for infection, with meningitis. The countless turbinate operations that are performed annually with the very small number of meningitis deny the validity of this claim. There must be an occasional infection. No surgery is free of this risk.

For the maxillary antrum the effort for drainage or ventilation is to leave an opening at its lowermost part into the nose. At the present time the older procedures which provided some other opening to permit washing seem to have been universally abandoned for self-evident reasons. Technique for the relief of the antrum may be divided into that which saves the lower turbinate and that which removes it in the effort to provide drainage or ventilation. The conservation of the turbinate here, is far more important than that of the middle turbinate for the upper cells and presents no difficulties or objections. In most noses where the middle turbinate has been removed for the relief of the upper cells it is *imperative* to save the lower turbinate if the nasal functions of moistening, warming and filtering the inspired air are to be preserved. Removal of it leaves a too wide channel permitting a direct blast of the dry cold impure air into the pharynx. The patient then suffers from a dry, more or less crusted, pharynx for life.

In addition to the above described procedure is to be recommended the removal of the floor of the frontal sinus in cases where it is found after the cribriform turbinectomy, that the inlet to the frontal sinus has been obliterated. This was first conceived and executed by E. Fletcher Ingals, who passed a small probe into the sinus to be used as a guide to limit the posterior cranial cut of a drill used to remove the anterior part of the floor of the sinus, which is here made of heavy bone. After the opening has been made sufficiently large, a gold tube which has been split in several places longitudinally for a distance of two-thirds cm. from its upper end and spread out to resemble a funnel, is placed in the opening. The spreading of the upper end is controlled at the time of introduction by confining the split parts in a gelatine cap. This facilitates its introduction. Later the cap melts, the end spreads out, and it

Digitized by Illinois College of Optometry

is in this way self-retaining. To prevent the tube from slipping up into the sinus it has a flange on its lower end.

The advantage of removing the floor of the frontal sinus has appealed to other surgeons who have modified the procedure more or less; e. g., Halle, Watson-Williams; and Lothrop has proposed to convert the two frontal sinuses into one by the removal of the frontal septum, and then to remove the floor of the combined cells with that part of the nasal septum encountered in the downward progress of the procedure. Lothrop's operation is external. Halle's and Watson-Williams' are intranasal. The difficulty met with in these procedures is to maintain an opening into the nose; i. e., to make one that remains permanent. Lothrop's undoubtedly makes the largest opening. Ingals avoids closing by the self-retaining gold tube. In contradistinction to these procedures is that (the author's) which lays open the full extent of the infundibulum but leaves its epithelial (permanent) linings undisturbed. Such an outlet or inlet remains permanent. The only thing which can close it is the advance of the hyperplastic osteitis under the membrane. When no communication between the nose and infundibulum exists the floor must be removed. My experience is that the patient has far less trouble with Ingals' tube in position. Killian's[1] and the other radical external frontal operations are not designed for this class of cases.

I have always thought that the surgery of the paranasal, especially the upper cells should be in the charge of the surgeon who is thoroughly learned in the anatomy of the parts and who possesses the skill to execute that which he should thoroughly understand. Shortcomings in either of these qualifications is most unfortunate for the patient for the reasons (1) that surgery imperfectly performed at the initial operation is difficult or often impossible of satisfactory correction later because of the loss of landmarks and the reproduction of the bone that is so hard that it is at times almost impossible to deal with satisfactorily. Of course a drill or a burr can cut bone of any degree of hardness, but when these instruments must cut upward and backward, the surgeon becomes timid and fails to reach the furthermost points at which the difficulties lie. (2) Surgery improperly performed for the relief of eye lesions,

Digitized by Illinois College of Optometry

not only fails to relieve, but may make them rapidly worse. I have seen this happen. Personally I cannot but feel that post-ethmoidal-sphenoidal surgery for the relief of eye lesions is always fraught with great responsibility. For this reason I feel that it should be executed only upon the basis of a definite diagnosis. To be satisfactory it must always be complete because we have no way to tell which of the post-nasal cells is doing the damage. For this reason the simple opening of the sphenoidal sinus from its natural opening cannot be recommended if we are to accomplish the greatest good for the greatest number. At the present time this procedure is recommended by an occasional author, because it is so easy and simple. I believe this judgment rests on an insufficient knowledge of the anatomy of this district. And while saying this, I am, moreover, fully conscious that an occasional headache or eye lesion may be and *is* relieved by this easy and simple procedure. But should it fail, as it often does, the second operation which must quickly follow, must be performed under much less advantageous conditions; to wit, reaction, swelling, bleeding and increased difficulty in keeping one's bearings. (For the anatomy bearing upon these questions, see page 140). Furthermore, the pathological process in the post-ethmoidal and sphenoidal sinuses so constantly involves both sinuses, that it is a difficult question to decide whether they are ever wholly separately involved. It is a question corresponding to whether the frontal sinus is ever involved without that of the anterior ethmoid. For these reasons I feel that the only procedure that embodies good judgment and security for all cases is the complete post-ethmoidal-sphenoidal operation as described in the succeeding pages. I furthermore believe that the best judgment calls for a complete cribriform cut of the nasal wall of the anterior ethmoid extended to the complete cribriform cut of the turbinate, thereby not only removing the entire middle turbinate but opening the entire ethmoidal capsule with the infundibulum to its full extent, whether these cells be involved at the time or not. A small stump (one-third cm.) of the posterior tip of the middle turbinate should be left. It is clinically negligible and serves as a useful landmark, should any subsequent procedure be necessary. I believe this to be the best judgment

Digitized by Illinois College of Optometry

because when the anterior half of the turbinate is saved it later enlarges so as to necessitate further surgical interference. Hajek[1] made this observation on the lower turbinate where the posterior half was saved in intranasal antrum operations. When the complete sphenoidal-ethmoidal-frontal operation is properly performed for the usual case, the result remains perfect for many years if not forever. This may, however, occasionally not be true when the hyperplastic process in the bone is of very high grade in younger patients. The bone reproduction then may be so great and rapid as to require secondary operation at a future time.

I have never seen any functional disturbances as the result of the complete operation.

In the procedure for the relief of the frontal sinus, I remove the middle turbinate three-fourths back in order to also free the outlets of the anterior ethmoidal cells completely. This leaves a small stump posteriorly which is helpful as a landmark should a subsquent operation be needed. It becomes hyperplastic or hypertrophic later but remains clinically negligible, because its position does not obstruct any of the outlets. This is not true for the anterior half of the turbinate which obstructs the frontal and ethmoidal outlets when it enlarges.

The Author's Technique

The author's technique[7] *for the upper cells* may be combined for all or separated into that for the single cells. Its advantage (and original feature) is that it cuts *always downward and forward,* that is, *always* in the direction of *safety.*

Anesthesia.—The operation may be executed under local or general anesthesia. It has always seemed to me that there is more bleeding under ether anesthesia, which adds much to the inconvenience and confusion of the surgeon. Under these conditions, it is easier for him to lose his bearings which may prevent its perfect performance or be disastrous. On the other hand the consciousness of the patient sometimes makes the satisfactory control of him difficult or impossible, especially in hysterical patients. This difficulty, however, is usually controlled by the administration of a small dose of morphine one-half hour before. Its effect is greatly intensified by the addi-

Digitized by Illinois College of Optometry

tion of a small dose of hyoscine (morphine ⅙ gr.—0.01 gm.—hyoscine ⅟₂₀₀ gr.—0.0003 gm.) In this way I have seen the greatest anxiety and apprehension allayed. Cocaine has often been impotent at the time of great fear (in my experience), and perfectly potent and satisfactory in the same patient who had previously had a quieting dose of morphine—hyoscine. For these reasons the psychical state of the patient should be carefully estimated. Much post-operative nervous depression—"neurasthenia" may be avoided if anxiety, apprehension and fear can be eliminated at the time of operation. These facts are well known to experienced rhinologists. I believe them, however, to always merit emphasis, and especially so, when the patient to be considered is one who has suffered the harassing headaches of these lesions for months and years. Most of these patients were long ago adjudged "neurotic" and well they might be. I know of few bodily states better calculated to make the ablest bodied "neurotic" than the endless severe suffering that many of these patients have endured, sometimes from childhood. The neurotic state is moreover frequently interpreted as the cause of the headaches, which seems to me, to add to the mental difficulties of the patient. Not infrequently they think themselves "half crazy," (and they seem so).

A feature that comes into consideration for all patients, is not only a satisfactory anesthesia but the amount of cocaine necessary to obtain it. The complete operation for the upper cells extends over so large a part of the lateral wall, that anesthesia by surface painting with a solution of sufficient strength is apt to be followed by cocaine absorption to such a degree, as to constitute poisoning. This happens by virtue of the extent of surface painted and the amount of cocaine used. In order to obviate this difficulty, I began in 1913,[24] the use of a nerve-trunk anesthesia, which requires much less cocaine and is applied over a much smaller area. The nerve supply of the nose in great part is from the nasal ganglion and enters through the sphenopalatine foramen. The remaining supply is the anterior ethmoidal nerve (B. N. A.) which enters through the longitudinal fissure of the ethmoid (Piersol, *Human Anatomy*, 1907, page 192, line 6) at the apex of the angle formed by

Digitized by Illinois College of Optometry

the roof with the anterior limit of the nose. At both of these points the nerves may be blocked by a small amount of strong cocaine solution applied to the membrane. For this purpose I set a small aluminum applicator which carries about one drop of saturated (90 per cent) water solution under the posterior tip of the middle turbinate, and leave it five minutes for effect on the nasal ganglion. It is then changed to rest just back of the tip in an upward and backward direction, to lie approximately over the trunks in the sphenopalatine foramen and allowed to remain another five minutes. I do this because the

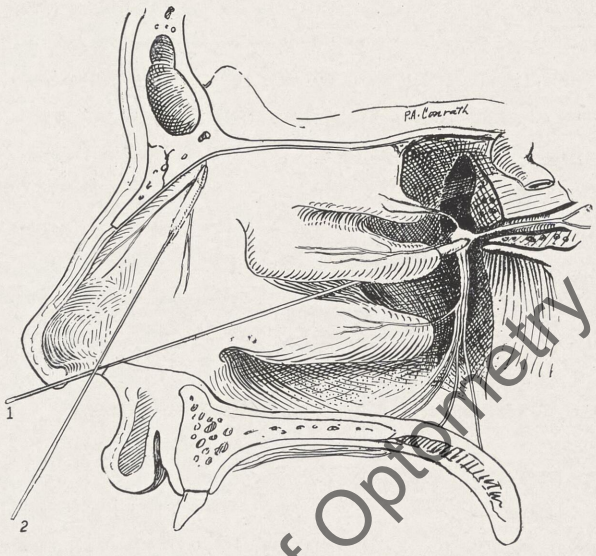

Fig. 132.—Position of applicators (*1*) for cocainization of the nasal ganglion and (*2*) for cocainization of the anterior ethmoidal nerve.

ganglion anesthesia may not always be complete in five minutes. The trunk application usually completes it. I have also tried both of these positions singly. I find the combination more satisfactory. At the time the posterior applicator is changed at the end of the first five minutes, I set the anterior applicator for the anterior ethmoidal nerve. I use a toothpick-like wooden stick carrying about one-half drop of the same solution, using the anterior limit of the nose as a guide, passing it upward until it reaches the roof, where it automatically lodges in the apex of the angle, allowing it five minutes in position. (Fig. 132.) Anesthesia thus secured is complete and compre-

Digitized by Illinois College of Optometry

hensive for the distribution of the respective nerves, namely, that half of the nose. I have repeatedly had patients show no trace of cocaine disturbance, and tell me afterward that they felt no pain from the complete upper cell operation. On one occasion I did the upper and antrum operations at the same time with such anesthesia. But usually I have not found the indications combined, necessitating both together.

The patient at the time of operation should be instructed that he will have three things to engage his attention. First, pain; second, the noise of the bone cutting; third, the pulling (force) required to put the knife through the tissues (which often is great). He will not confuse the first with the second and third, if his mind is directed properly.

No anesthesia has been so satisfactory at this (in my experience), and cocaine poisoning has been almost eliminated (in my experience) by its use. All cocaine anesthesia may, however, fail sometimes for two reasons. Acutely inflamed tissue will not become anesthetic by cocaine, nor can a terrified patient be anesthetized. The former is easier to understand. I have repeatedly been assured by the most intelligent but terrified patients whom I have operated upon, despite their mental state, with what was a superabundance of cocaine, that the pain was as though no anesthetic had been used. This has been true for all methods of applying cocaine. This is not so easily understood. Added to these is a small class in whom neither terror nor local inflammation explains the resistance of the tissues to cocaine. It is, however, fortunately a very small class.

An application of adrenalin solution is helpful in reducing swelling, giving a wider field of operation, as well as controlling bleeding, and possibly helping the anesthesia.

The most satisfactory nasal surgery (my experience) is a hospital operation in complete "twilight sleep." One-sixth or quarter grain morphine with $\frac{1}{130}$ gr. hyoscine are given together subcutaneously, with the stomach empty. Two more doses of $\frac{1}{130}$ gr. hyoscine are given. Forty-five minutes are allowed between doses. The room should be quiet and dark. The cocaine applications are then placed as above directed. Should the patient

Digitized by Illinois College of Optometry

still be stiff or restless ether may be administered to produce relaxation. No additional ether is needed.

The Operative Procedure

Anatomically the paranasal cells are designated according to which meatus of the nose they enter. This is more or less an anterior and posterior subdivision, and for the purposes of diagnosis this must remain unchanged. For surgical purposes, however, it seems to me that they may advantageously be thought of as upper and lower, the latter being the antrum of Highmore, the former being the remaining cells. This subdivision establishes a horizontal dividing line on the lateral wall at about its middle. Successful surgery of the antrum must leave a drain at the level of the nasal floor. The lowermost part of the upper cells is along the line separating them from the antrum; i. e., the horizontal midline. Successful surgery of the upper sinuses, however, is not achieved by a drain along this line, for the reason that there are usually cells which are limited to a part far above the midline. Successful surgery of the upper sinuses must lay open for drainage the upper cells in their entirety beginning at or very close to the cribriform plate of the ethmoid—the roof of the nose—opening at the same time the lowermost of these cells, that is, removing the lateral wall with the middle and upper turbinates above the midline.

This procedure may be conservative or radical. The former consists of the removal of the turbinate and the very superficial nasal layer of the capsule of the ethmoid. The radical operation consists of removing the capsule "part and parcel" including the orbital plate when desirable for drainage of the orbit into the nose, at any or all points from its anterior limit to its apex.

One comprehensive surgical procedure has been offered for this district. To this therapeutical end particularly was directed the intelligence of Dr. H. P. Mosher[1] when he proposed the "Surgery of the Ethmoidal Labyrinth." That procedure must of necessity be a radical one, although he does not recommend it for the extreme of radical; to wit, opening the orbit. He proposed it for the relief of cases in advanced stages of

Digitized by Illinois College of Optometry

suppuration and degeneration, not such cases as I have delineated. It is admirable for the cases he proposed it for, but it must needs cut upward and backward or backward and upwards. The procedure recommended by Dr. Otto Freer, in which he proposes to enter the frontal sinus by way of the bulla ethmoidalis, seems to me to be based on a wrong conception of surgery and insufficient knowledge of the anatomy of the parts. It is also fraught with the danger of upward and backward and downward and backward cutting without a guide and should be condemned.

It seems to me that the procedure that I now submit has some advantages that are not otherwise offered. It has been satisfactory in my hands for sixteen years. It may be limited for the frontal sinus, providing a very high cut of the middle turbinate which I have frequently mentioned in various texts as a "cribriform or infundibulum turbinectomy." The cut is actually 2 or 2.5 mm. from the cribriform plate and may be extended to the most anterior limit of the infundibulum. Or this very high cut may be carried backward to include the capsule of the ethmoid, under which condition not only is the middle turbinate removed, but the uppermost line of, and usually all the other ethmoidal cells are opened wide into the nasal cavity. And when desirable the entire anterior wall of the body of the sphenoid from its *uppermost* limits, into a possible pterygoid process prolongation, with *all* its *post-ethmoidal association*, and *much* of its *floor*, may be *removed*. In my judgment and experience it is the technique that most often may be trusted to open all of the cells, *regardless of unusual or anomalous positions*. It accomplishes the frontal inlet as Dr. Freer endeavors to, but by safe cutting. I *know, however, that cells may exist that not only cannot be opened from the nose but cannot be located by any means at present at our command.* They can only be recognized in the cadaver and then only by complete dissection. Everyone who has observed a reasonable number of specimens has seen such cells and been impressed by the futility that would attend any surgical effort to reach them; and everyone of reasonably wide experience has met cases where all efforts had failed to find and treat such cells. But there are many other cells that are placed in positions more or

Digitized by Illinois College of Optometry

less unusual that will be opened by a *technique which has for its primary plan an incision which will skirt the cribriform plate and remove the ethmoidal wall and the middle turbinate at its most anterior as well as its most upper limits and extend into the sphenoidal body at its uppermost part regardless of the natural opening, and then be extended downward until it has cut through its floor or found it to be impenetrable.* I have avoided the designation of sphenoidal sinus because such a term does not always comprehend the full body of the sphenoid. It (the body) may be subdivided, and shared by a post-ethmoidal cell. And it is this variation which I believe to be the most pernicious from the clinical side (for headache and optic nerve lesions), as well as anatomically far more frequent than is at present recognized clinically. This variation will (it seems to me) be satisfactorily dealt with by this proposed technique practically every time it is met. I have frequently opened two cells in the body of the sphenoid (once I opened three). Also *pre-frontal-ethmoidal cells* will be *opened* into the nose *as a rule,* if not uniformly.

Technique.—In 1907 I[3] published an elementary text in which I described a surgical method which was at that time novel. It consisted in approaching the turbinate from above on its inner side. Prior to that all surgical approach was from below laterally upward, removing it by scissors or snare or a combination of these or such working instruments. I at the time described a knife consisting of a handle, a shaft and a cutting end turned at a right angle to the shaft and sharpened so as to cut on the inside of the right angle, i. e., on the pull. It was also sharpened on a face parallel to the shaft which at the same time gave it far more strength than a hook could have were it sharpened on its concavity. I selected this shape in preference to a hook for those reasons, and the fact that great strength is necessary for the tasks to which this knife is put. The knife, although possessing great strength is so small that it may readily enter spaces which larger instruments could not. I believe it to be the smallest nasal instrument possessing great strength.

A glance at the lateral wall shows that the higher and the more forward the infundibulum is opened the wider and

Digitized by Illinois College of Optometry

freer will usually be the inlet to the frontal sinus. At the same time prefrontal ethmoidal cells will usually be opened by such an incision. For these reasons it has been advantageous, in my hands, to introduce the knife sagittally under the anterior third of the middle turbinate as far back as the un-

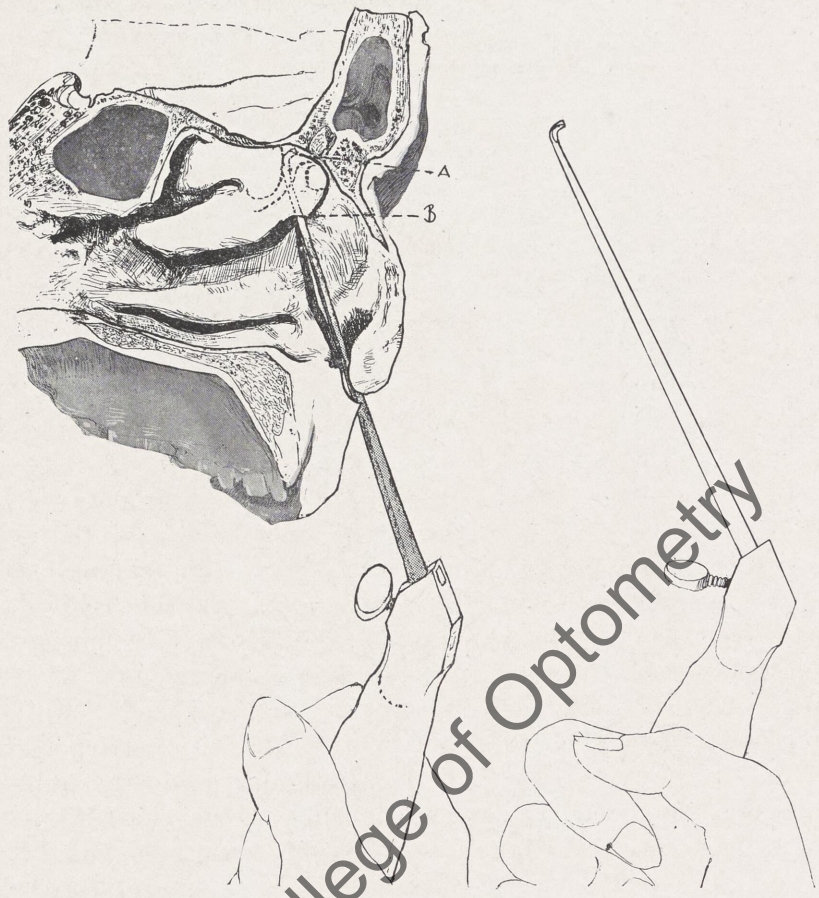

Fig. 133.—On the right the angle knife is shown in the sagittal plane ready for insertion under the middle turbinate. On the left it is shown in position for the forward and downward cut. It has been introduced into the infundibulum and rotated 30 degrees inwards, i. e., toward the septum nasi. The heavy line *A-B* shows diagrammatically the line of this first cut which may be accomplished in one stroke or two, according to the surgeon's election (I prefer two strokes usually).

cinate process, as high as the cribriform plate with its cutting edges facing forward. It is then rotated somewhat inward and draw forward and downward. (Fig. 133.) Consider-

Digitized by Illinois College of Optometry

able forward pressure is kept on it while it is being drawn downward. In this way the foremost and uppermost nasal wall of the capsule of the ethmoid (with the attachment of the middle turbinate) is cut open, and the prefrontal cells of the ethmoid are thereby thrown open, as the nasal wall of these cells is usually constituted by that part of the capsule, with the attachment of the turbinate. This must be considered the conservative technique. By these means, however, are put an inlet or outlet to the usual frontal sinus that comprehends the dimensions of the usual infundibulum; i. e., 6 mm. anteroposteriorly and 3 mm. laterally. Should this size be reduced to such a degree as to require some procedure more radical, the knife is then engaged in the hiatus semilunaris with its cutting edges forward or downward—usually in the uppermost limit. By a downward pull, the uncinate process will be removed, and the knife may finally be engaged in the floor of the anterior part of the frontal sinus. (Fig. 148.) This may be so thick and hard that it is with difficulty, or impossibly, handled by this knife. A large enough opening, however, is usually secured to admit a Good rasp or a burr. The burr is then introduced into the sinus and put in motion with a forward and downward pull. In this way I have slightly modified Ingals' ideal frontal sinus technique. This stroke of the right-angle knife, it will be seen, is safe, as it cuts away from danger (brain), or the knife in position, cutting edges facing upward and forward is likewise safe with a downward or forward pull, as it also cuts away from danger. It will cut into the buttress of the lower anterior part of the sinus.

For the anterior ethmoidal district the knife is reintroduced along the cribriform plate—its smooth elbow with a gentle touch, recognizing the smooth uppermost limit of the nose—to a distance 1 cm. In this position its two cutting edges face downward. It is now rotated until its cutting edges point outward and slightly upward. The upward turn is added to the outward for the reason that the outward and upward position permits of a more nearly horizontal pull. The slight upward turn keeps the line of incision much more near the horizontal despite the fact that the pull must needs be downward and forward or forward and downward. The safety of this cut is provided by two factors; i. e., the cells of the ethmoid in their

Digitized by Illinois College of Optometry

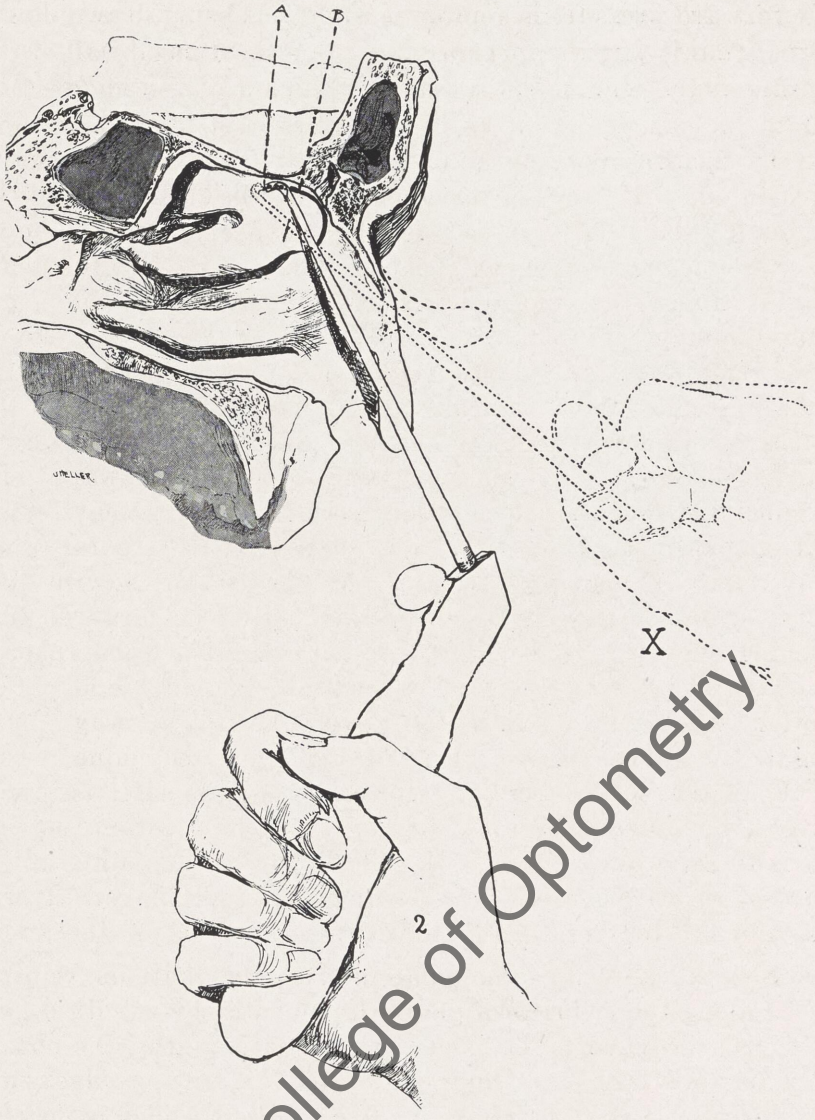

Fig. 134.—Shows the angle knife introduced between the septum and middle turbinate. It has passed 1 cm. back of the first cut along the cribriform plate. The dotted line *X* shows it to have been rotated outward until its cutting edges point 30 degrees above the horizontal. The tip of the nose has, at the same time, been forcibly elevated. The heavy dotted line *A-B* shows the line of cut.

extension into the roof of the orbit rise at once above the cribriform plate; and the length of the cutting arm of the knife which should be 2 mm. is too short to cut through the extent

Digitized by Illinois College of Optometry

of the nasal orbital thickness of the ethmiodal capsule under any circumstances. This incision is the first of two or three similar ones. (Figs. 134 and 135.) I prefer to divide it into

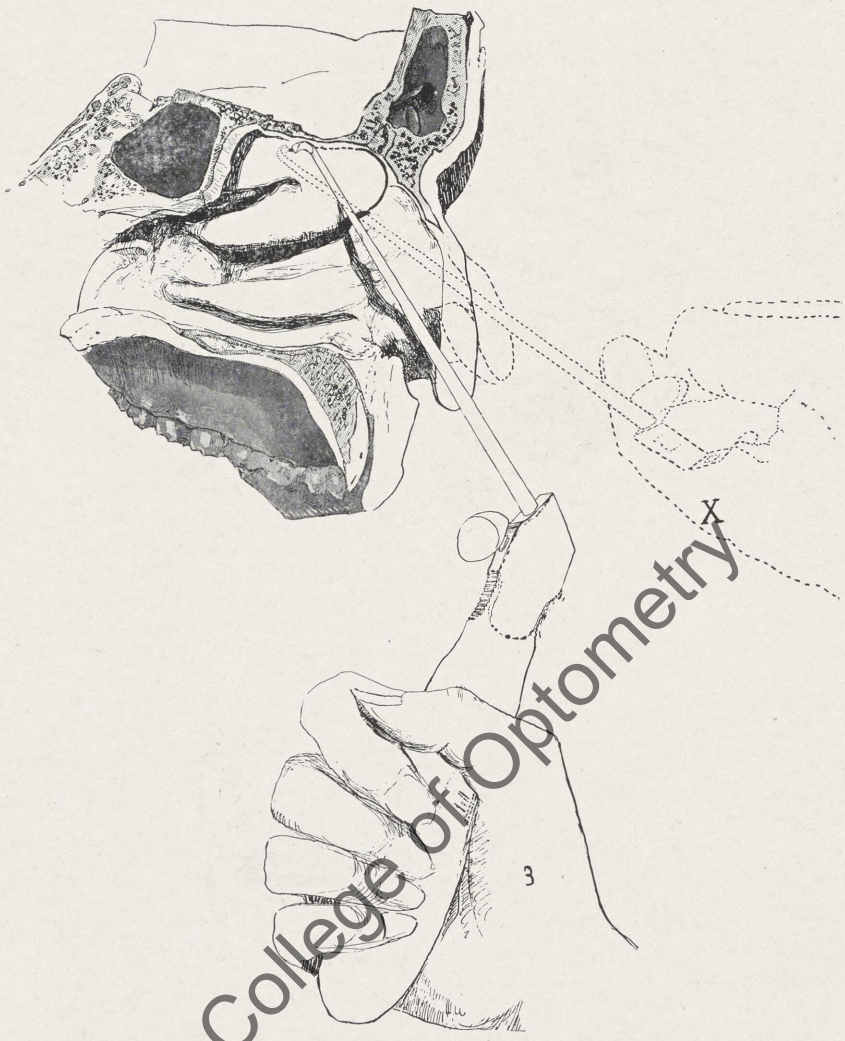

Fig. 135.—Same as Fig. 134, with the difference that the knife has been passed the second time along the cribriform plate to a distance 1 cm. back of the first cut.

two or three because I can keep my bearing upon the cribriform plate more satisfactorily by these shorter cuts than in one longer one.

Digitized by Illinois College of Optometry

Now the operative procedure is to be directed by the judgment of the surgeon. In my judgment the only turbinectomy should be a cribriform or infundibular turbinectomy; i. e., one

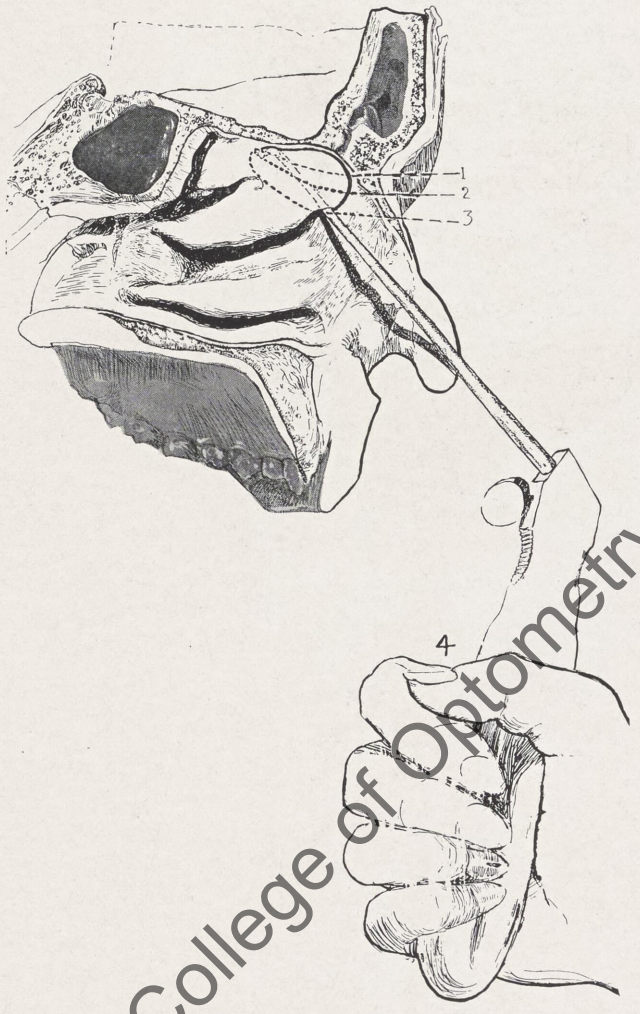

Fig. 136.—Shows the knife introduced sagitally under (lateral to) the middle turbinate for the purpose of cutting into the capsule of the ethmoid. The dotted line *1-2-3* shows the successive cuts from above downward. These cuts may be readily made to enter the orbit by inclining the cutting edges 30 degrees outward. In the conservative employment of this technique, this employment of the knife may be omitted.

that opens the infundibulum to its widest possibilities, for the reason that a lower cut leaves a stump that is physiologically

Digitized by Illinois College of Optometry

worthless and surgically difficult of later manipulation. This is not in reality a stump although in former years I considered it such.[3] It is that part of the ethmoidal capsule which makes the inner portion of the final entrance of the frontal sinus into the nose—the anterior part being the uncinate process, the posterior part being the bulla ethmoidalis, the external and internal parts being ethmoidal capsule. The removal of this inner part as high as possible usually gives an inlet to the frontal sinus 6 mm. anteroposteriorly by 3 mm. laterally. Some frontal sinuses enter the nose by a devious channel and cannot be

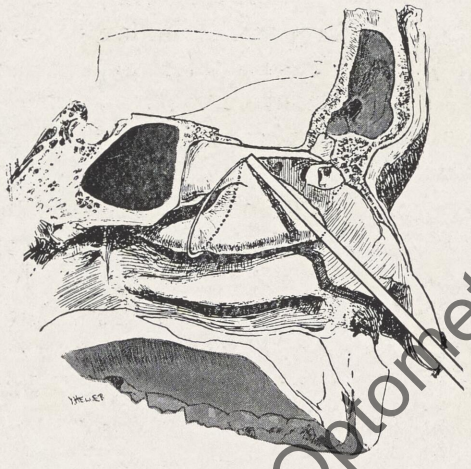

Fig. 137.—Shows the snare loop placed around part detached.

considered as usual (Figs. 14, 15, 16, and 17, page 38). If this upper internal part of the frontal inlet is not removed at the primary operation it seems to me it is unfortunate, as a secondary operation will almost surely wound the epithelial surfaces of the frontal inlet and then be followed by connective tissue development which will block the inlet. The primary high cut is usually accomplished without that result, leaving the hiatus semilunaris and infundibulum free of scar tissue. The secondary operation is usually of necessity done with more trauma to the hiatus regardless of whatever technique is employed. For this reason I emphasize the advisability of doing the foremost cribriform cut primarily if the anterior half of the turbinate is

Digitized by Illinois College of Optometry

touched at all, regardless of whatever else is to be done surgically. (Compare Fig. 138.)

The cutting edges of the introduced knife are now turned downward or downward and slightly outward (Fig. 136), and the incision is placed superficial (internally) or may be placed as deep (externally) in the capsule of the ethmoid as the judgment of the surgeon directs. For the simplest subacute suppurative cases, the superficial incision suffices. For most radical, e. g., an orbital phlegmon back of the transverse meridian

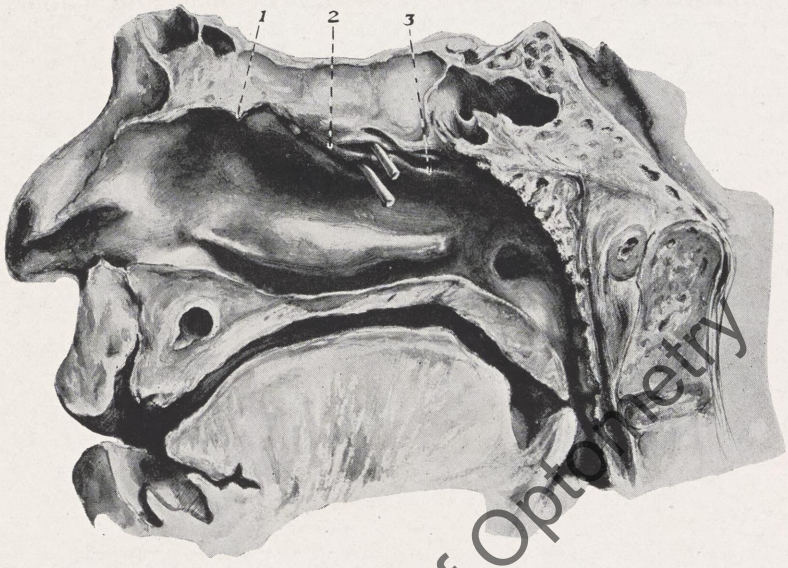

Fig. 138.—Showing the line *1-2-3* of amputation of the pendulous middle turbinate. No ethmoidal cells are opened by this procedure nor is the infundulum opened.

of the eye, the incision goes through the capsule into the orbit in its posterior half. This is readily and quickly done. The detached mass is then by means of the same knife (which may be turned somewhat transverse) pushed downward into the nose where the snare may be put around it and cut it from its attachments (Fig. 137).

The procedure may be varied by a superficial removal of the turbinate and then the excision of the capsule to any extent desired. In my practice I have had sixty-one orbital phlegmons produced by nasal sinus ruptures. All were opened intra-

Digitized by Illinois College of Optometry

nasally except two cases in children; these were treated by shrinking the nasal mucous membrane. It is obvious that the point at which the orbit is opened must be determined by what cell is presumed to have ruptured. In my experience this has far surpassed the results of external orbital drainage inasmuch as it drains by the same route that infected the orbit. None of these cases were opened externally. One frontal sinus case had to be operated upon three times before I got the drainage right.

Should the sphenoidal and post-ethmoidal cells also need the surgeon's care, I then (after the snare amputation of the middle turbinate) pass the angular knife very gently backward along the cribriform plate with its cutting edges downward. In this way its smooth round elbow glides along the cribriform plate until it meets the anterior face of the body of the sphenoid. This, it will be seen, is the uppermost point of the face and is independent of the natural opening of the sphenoidal sinus which is usually well below this point. It is my practice to also locate this point by placing the elbow of the knife on the lower part of the face of the anterior body of the sphenoid and gently follow it upward until it reaches the upper limit of the nose. In this way that point will have been located with double assurance. Gentle downward pressure is now made on the face of the sphenoid and the knife inclined slightly toward the septum. The first stroke perforates the usual sphenoidal face and cuts somewhat downward. The knife, cutting edges downward, is then introduced very gently into the opening so made and very gently extended as far back as the cell permits. It is rotated 15 degrees inward, and drawn downward and forward with any degree of force that may be needed. A septal prolongation of the sphenoidal sinus would probably be opened by this cut. I have never seen this clinically or anatomically. I know only Harry Neivert's representation of this variation. This incision will extend from the junction of the cribriform plate with the body of the sphenoid downward, a varying distance along the septum nasi, depending on the thickness and hardness of the bone. Should this incision not have reached the floor of the sphenoid, another similar one usually does (Fig. 139). Then the knife, edges down, is again passed along the cribriform plate and very carefully introduced back into the uppermost

Digitized by Illinois College of Optometry

limit of the opening already made. It is then rotated 30 degrees outward and brought out, forward and downward (Fig.

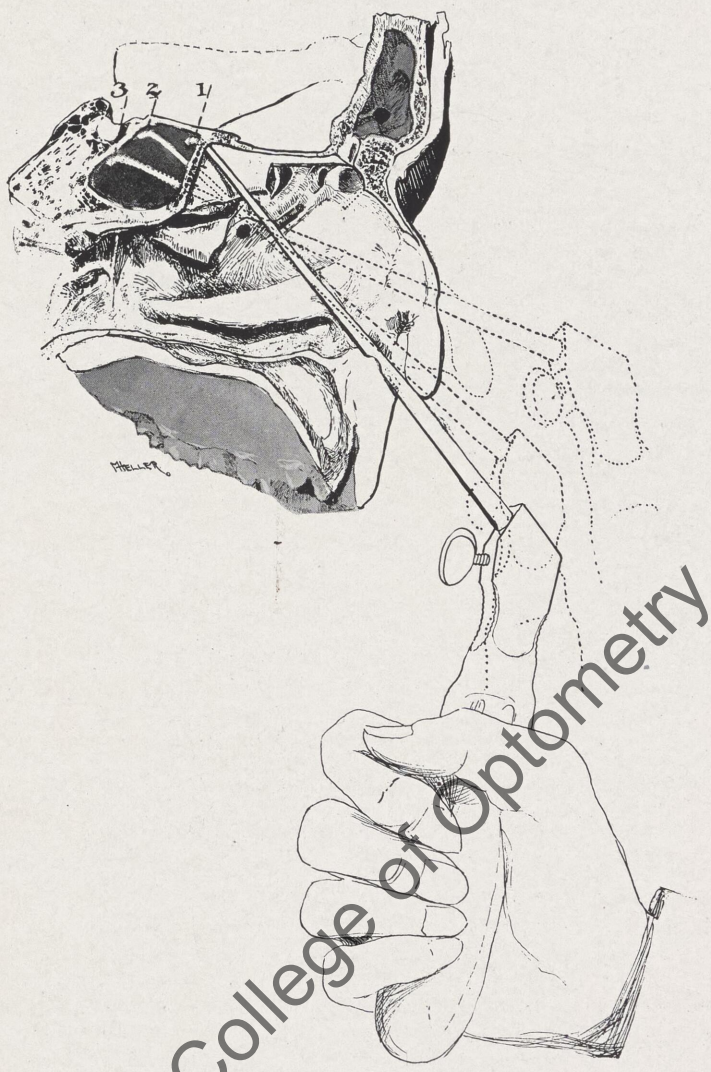

Fig. 139.—Shows knife *1* passed backward along cribriform plate penetrating anterior face of sphenoid at its top. The dotted lines *2* and *3* show knife passed back to posterior wall of cell and to have been rotated 20 degrees inward cutting downward to hug the septum nasi.

140). This incision includes a considerable part of the wall separating the post-ethmoidal from the sphenoidal cell, and it

Digitized by Illinois College of Optometry

has the advantage of beginning at the uppermost limit of the sphenoidal face. It has a distinct advantage over all methods which begin their procedure in or from the natural opening of the sphenoid, for the reason that often a post-ethmoidal cell

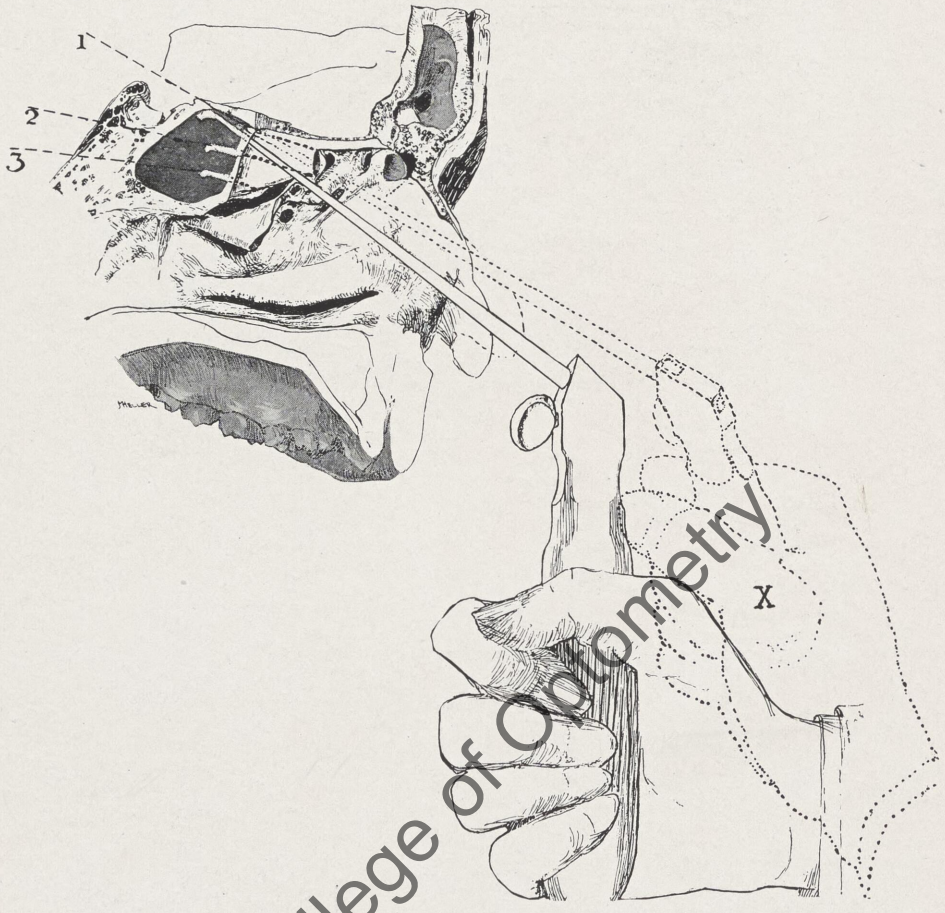

Fig. 140.—Shows knife to have been reintroduced through uppermost part of sphenoidal cut as shown in Fig. 139 to posterior wall of cell. It is then rotated 30 degrees outward (*X*) and carefully drawn forward and (necessarily) downward. The introduction of the knife to the posterior wall of the cell at its uppermost part insures the opening of many of the post-ethmoidal cells that are developed into the sphenoidal body. I believe this to be very important and one of the advantages to be secured by this technique.

occupies a part of the body of the sphenoid and is placed above the sphenoidal cell. Fig. 149 shows such a cell which would probably be opened by this technique and would probably not

Digitized by Illinois College of Optometry

be opened by any other technique now known. Such cells are exceedingly hard to deal with surgically and sometimes equally hard or impossible to find. Fig. 150 shows such a cell placed entirely above the line of the cribriform plate. This cell would



Fig. 141.—Knight-Leuder forceps.

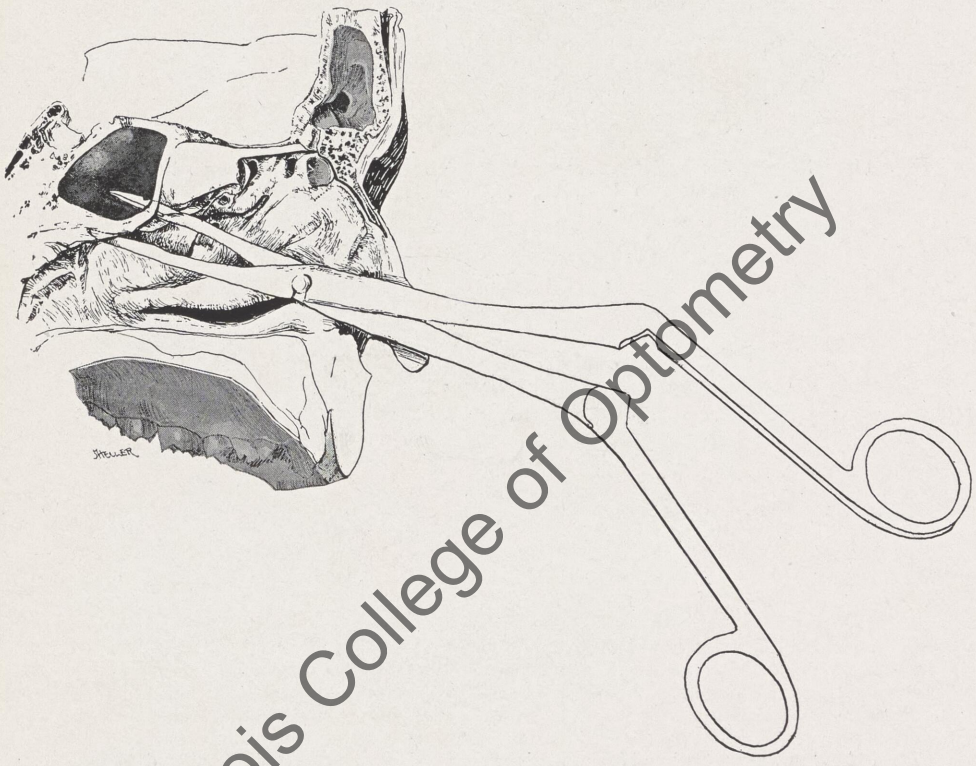

Fig. 142.—Shows the Knight-Leuder forceps (made especially for this purpose 3 cm. longer than the original model because this added length is often required) introduced into the opening in the anterior face of the sphenoidal body ready to bite out of the anterior half of the *floor* of the body. This is oftentimes easily done, but at other times the floor is too thick to be removed this way. It is removed by a rotary movement.

Digitized by Illinois College of Optometry

not be opened by this technique and I do not believe it could be recognized in life by the present means of investigation, except by taking an x-ray of the sphenoid after operation with probes

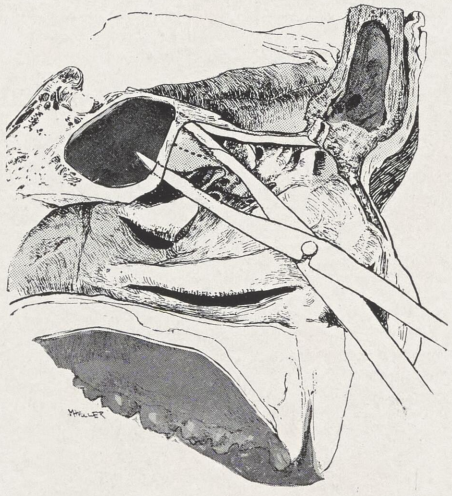

Fig. 143.—Shows the Knight forceps in position to bite out the post-ethmoidal wall which has been cut loose, as shown in Fig. 140.

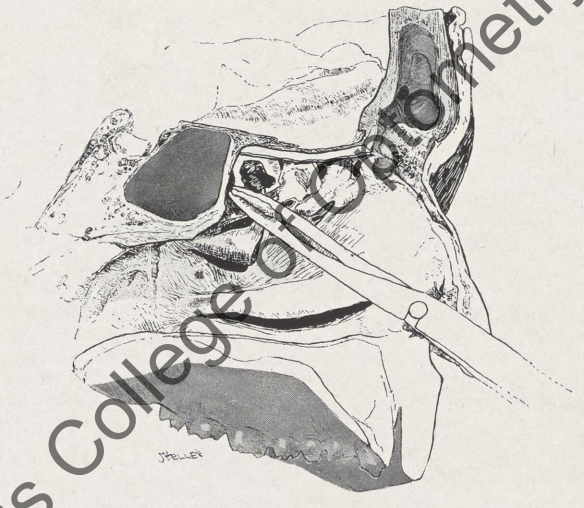

Fig. 144.—Shows post-ethmoidal wall in grasp of forceps. It is finally detached by a rotary movement.

in situ. Some such cells, however, have a lateral and downward extension which is opened by the second stroke of the knife

Digitized by Illinois College of Optometry

which is again introduced along the cribriform plate and inserted into the cavity in the body of the sphenoid, turned 30 degrees outward and drawn forward and downward. This second cut usually takes the post-ethmoidal nasal wall as well as most of the lateral part of the sphenoidal face and often the mass may be removed in one piece. For this purpose I use the Knight-Leuder forceps (Figs. 141, 142, 143, and 144), made, however, for this particular purpose, being 2.5 cm. longer than the original model. These forceps are then introduced into the

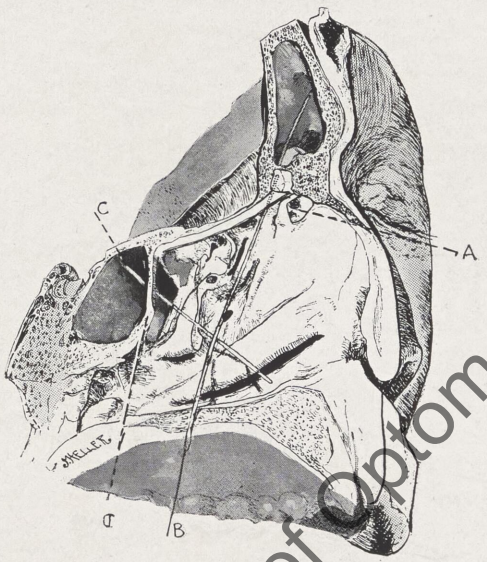

Fig. 145.—Shows a three-quarter view of specimen with operation completed. The anterior half has been left "conservative"; i. e., the wall is intact with all the openings free as far as 1.5 mm. of the cribriform plate. An infundibular cell, *A*, has been opened as shown first in Fig. 89. The posterior half is "radical"; i. e., the anterior wall of the sphenoid cell has been removed with its entire post-ethmoidal part (lateral part, which is one-half or two-thirds of its extent). The post-ethmoidal cells have of necessity been dealt with radically to accomplish this; i. e., their entire nasal side has been removed. Bristle *B* is shown passing from the nose into the frontal sinus. Bristle *C* is shown passing through the post-ethmoidal-sphenoidal opening. A strip of bone *D* has been left to indicate the position of the sphenoidal-vomer junction.

cavity of the sphenoid (Fig. 142), and so the floor of the sphenoid is removed in part. Everyone knows, however, that the floor often is so thick and hard that it cannot be removed by forceps. A drill which will do such service may be advan-

Digitized by Illinois College of Optometry

tageous in cutting downward. Fig. 146 shows a special post-ethmoidal forceps which is often of service.

In the performance of the post-ethmoidal-sphenoidal portion of the technique I prefer a knife smaller and slightly different from that used in the anterior portion, for the reasons, (1), that it is rendered much stronger; it cannot be broken in any of the service it may be put into; (2), a knife 1.5 mm. inside cutting edge cannot inadvertently cut into the orbit in this service unless wielded by some one neglecting the proper performance of the operation and totally ignorant of the anatomy here; (3), I feel that the angle of the sphenoid knife should not be turned the full 90 degrees from the shaft because such a

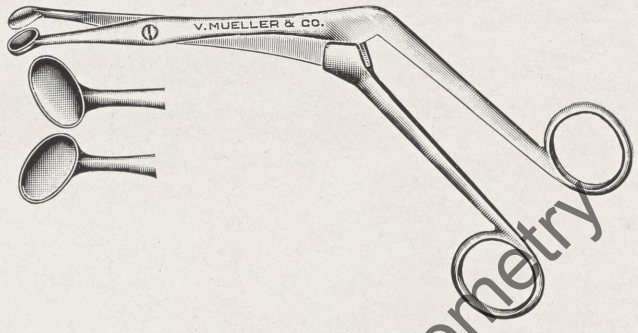

Fig. 146.—A three-quarter view of a post-ethmoidal forceps made right and left.*

knife could not be engaged in the face of the sphenoid. An angle of 68 degrees off the shaft which will make the cutting edge on the inside of the angle 112 degrees will bite readily into the face; and (4), a small knife 2.5 mm. in its entire cross measurement permits a much closer approach to the top of the sphenoidal face. One 6 mm. could not get so close by 3.5 mm. In this service a hook sharpened on its concavity would be much less advantageous because, if bent to a right angle, it would not bite into the face and if in 68 degrees to 112 degrees shape it would not execute the work so well and its point would break easily, when it would take the shape of the knife now proposed without being sharpened.

I feel that *special emphasis* should be laid upon the necessity of the surgeon knowing what are the *correct models* of

*Sold by V. Mueller & Co., Chicago, Ill.

Digitized by Illinois College of Optometry

these knives. For this reason I submit *dimensions* and drawings (Fig. 147*A* and *B*). Too large a knife has the disadvantage (1), of taking up space unnecessarily; (2), of biting more bone than it can cut; (3), of possibly cutting inadvertently into the orbit; and (4), of being much more apt to have its angle-cutting portion broken off in the operation. In this connection it must be emphasized that it is absolutely necessary that the knife be *tempered not too hard.* Should it be too hard it will always break with the work put on it in this operation. The *instrument maker* must *specially understand* this. It is far better to have it too soft. As such its cutting edges may not be as lasting, but

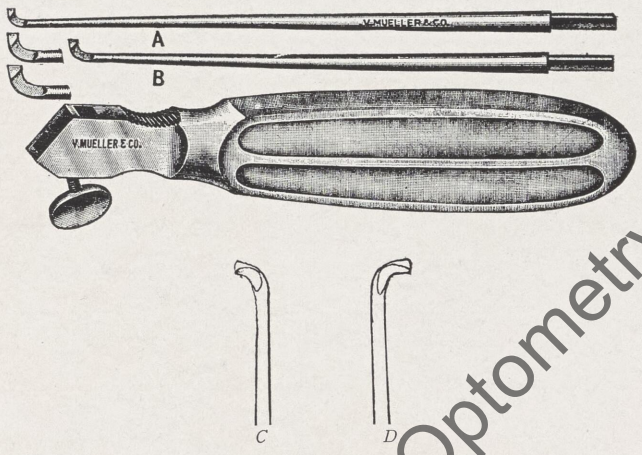

Fig. 147.—*A.* Sphenoid knife.* *B.* Turbinate knife.* *C* and *D.* Turbinate knives* made right and left. Some of my confreres prefer right and left knives. I prefer the straight knife.

it will not break. (I draw the temper of my knives by heating the tip to a cherry red in a Bunsen flame. They are allowed to cool in the air.)

Summary.—The intranasal surgery of the upper cells may be performed by this method in *any part* or the whole as *conservatively* or as *radically* as desired. The ability to place the incision safely 2 mm. below the cribriform plate in any part of or in the whole length of its extent seems to me to be most advantageous, and not a small part of this advantage is the power to extend this incision to the foremost limit of the infundibulum,

*Sold by V. Mueller & Co., Chicago, Ill.

Digitized by Illinois College of Optometry

thereby opening the inlet of the frontal sinus to its widest natural possibilities. It is most desirable to preserve the *natural* inlet here, and this is done by a cribriform turbinectomy which leaves undisturbed the histological epithelial covering of the normal inlet; i. e., the uncinate process, the bulla ethmoidalis, the hiatus semilunaris and infundibulum, regardless of the anatomical variations of the frontal inlet. Should these parts be wounded, as in a curettement, the resultant scar tissue blocks the inlet. The angle knife removes by cutting any desired tis-

Fig. 148.—Shows the knife in position for cutting away the uncinate process preparatory to Ingals' removal of the frontal sinus floor. Oftentimes the entire frontal floor may be cut away by the knife.

sue with the least possible trauma to the surroundings. In the sphenoidal district it opens the *uppermost* and *lowermost* possible parts of the face which has the advantage sometimes of opening also a *post-ethmoidal* cell which may occupy part of the body of the sphenoid. (Such a cell is often the cause of the entire clinical picture.) The angle knife is so small that it takes up the minimum room and so leaves the small field open to the best vision possible. Its execution is *always* in the direction *away* from the (brain) danger zone. I have not seen so far such satisfactory post-ethmoidal surgery by other methods. (This

Digitized by Illinois College of Optometry

district seems to me the most dangerous of all, for on the outer upper aspect runs the optic nerve and above is the optic chiasm and cranial cavity.) Satisfactory execution is necessary, particularly for eye lesions.

This entire performance may be accomplished within a short time. I have often finished the high frontal ethmoidal and sphenoidal combined operation in two minutes (including

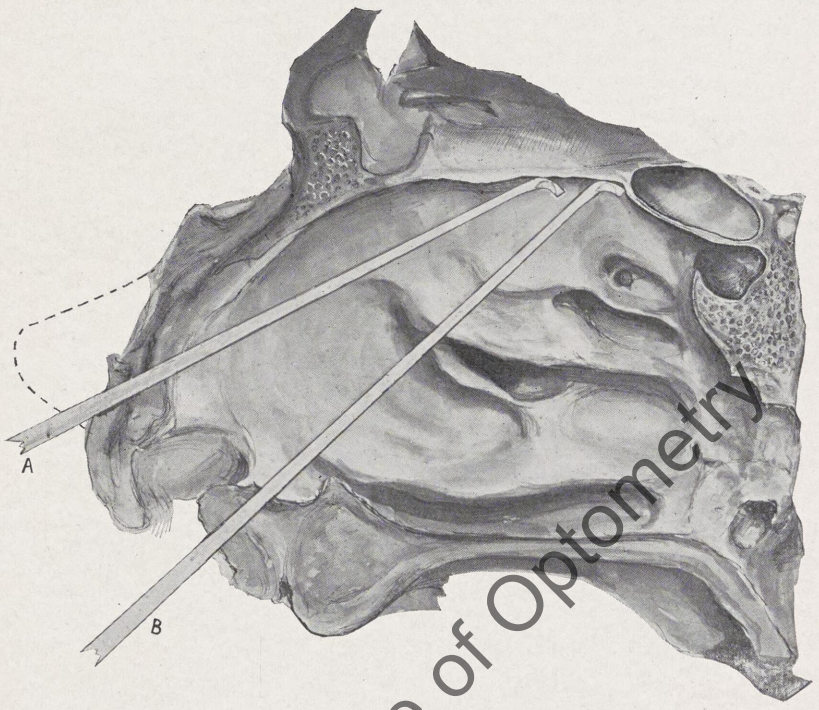

Fig. 149.—Shows knife approaching a post-ethmoidal cell which lies on the top of the sphenoidal sinus and occupies about one-half of the body of the sphenoid. The line *A* shows position of approach. *B* shows the position for cutting. From considerable clinical experience I believe this cell would be opened by this technique.

the post-orbital opening on one occasion). Twilight sleep allows the surgeon any length of time.

A septum nasi deflected into the affected side may add troubles for the surgeon. I have in such cases where the middle turbinate was not visible from in front in any part used a bivalve speculum specially constructed for the purpose. (See Fig. 41, p. 55.)

Digitized by Illinois College of Optometry

Fig. 150.—*A* shows the usual sphenoidal sinus and the usual cribriform plate with their usual relations. *B* shows post-ethmoidal cell *1* placed altogether on top of sphenoidal sinus *2*. Its lowermost limit is almost on the horizontal of the cribriform plate *3*. This cell could not have been opened by this technique, nor, in my judgment, by any other extent.

Digitized by Illinois College of Optometry

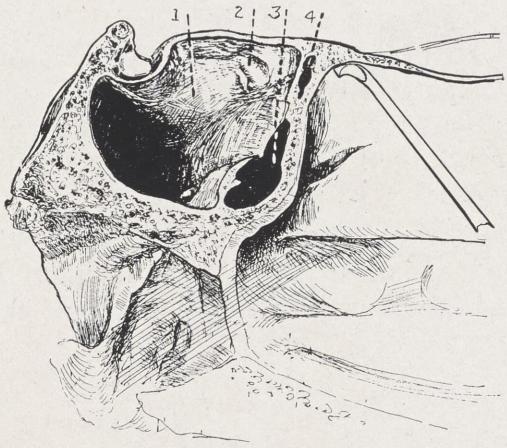

Fig. 151.—Showing the left half of specimen. *1*, right sphenoidal sinus extending into left side to border left optic canal *2*. *3*. Left sphenoidal sinus. A post-ethmoidal cell *4* also borders left optic canal. All three of these cells would probably have been opened by this technique operating on the left side.

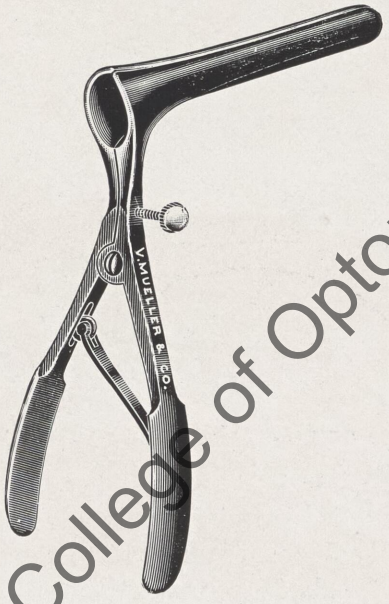

Fig. 152.—Sphenoidal speculum.* It is the primary bivalve nasal speculum made of tempered steel blades 88 mm. long, 9 mm. wide, knife edge thin near tip. It should have a set screw. It is a simple enlargement of the primary bivalve for this purpose as Killian's enlargement is for the purposes of septum resection. It is 13 mm. longer and 4 mm. wider than the usual model of Killian's. The sphenoidal knife used with this speculum is 25 mm. longer than the regular knife. By means of this speculum the route to the sphenoid may be forcibly widened when it is too narrow.

*To be had of V. Mueller & Co., Chicago, Ill.

Digitized by Illinois College of Optometry

The knives are also made right and left (Fig. 147 *C-D*). Some of my associates prefer these. My own preference is for the single, straight, original model. I recommend an extra (2.5 cm.) long shaft for use with the long blade sphenoidal speculum. A strong, large handle ought always be supplied for the knife.

A right-hand surgeon makes his turbinate cuts for the left side, cutting edges in the plane of the handle. For the right side the cutting edges are turned one quarter (90 degrees) into

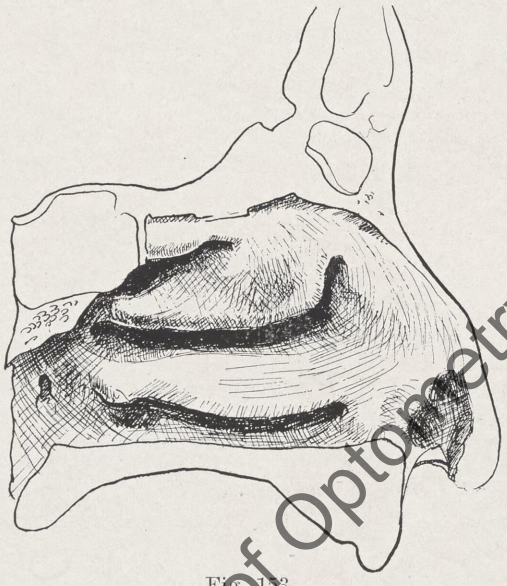

Fig. 153.

the right nostril. This makes them horizontal or transverse when the handle is on the middle line.

This technique is especially advantageous in tall noses. Some measure only 5 cm. from roof to floor, others measure 7.5 cm. Figs. 153 and 154 represent these proportional differences. High operating in the former is much simpler than in the latter. A technique which cuts downward and outward is obviously advantageous.

The lower the sphenoidal post-ethmoidal cut goes on the lateral wall, the more likely is brisk bleeding and shock because this incision approaches or reaches the entrance of the vessels

Digitized by Illinois College of Optometry

and nerves as they come through the sphenopalatine foramen. The bleeding is, however, usually slight at the time of operating, being controlled partly by adrenalin solution and often by the lowered blood pressure of shock which increases as the larger nerve trunks are cut. A normal blood clot then has time to form and close the vessels. It is advantageous to avoid packing the nose here because of the great discomfort of a pack put in tight enough to answer the purpose, and because of the

Fig. 154.

trauma it inflicts. Apposing surfaces are roughened and later synechias form. In patients with poor general strength, the pack that should usually remain 48 hours exhausts them more than the shock of the operation. This may be prevented largely by carbolizing the nasal ganglion before the operation (Sluder[24]), but as a rule of practice I prefer to put the patient (without pack) in a hospital for 24 to 72 hours, and not pack unless brisk

Digitized by Illinois College of Optometry

bleeding develops. Should it come on it is usually of such volume as to require immediate control. If the patient cannot be placed in a satisfactory hospital, I always pack the post-ethmoidal-sphenoidal district. Small doses of heroine prevent sneezing and so eliminate one factor that brings on bleeding. On the third or fourth day I begin the instillation of phenol oil, and on the seventh or eighth day I begin the alkaline saline wash. If this is begun too soon it conduces to bleeding, probably by dissolving the clots in the vessels. Synechias in the posterior district are usually negligible clinically. Should it be desirable to dispose of them, I wait until scarring is complete and divide them with a sharp knife. Usually the scar tension will pull apart the cut surfaces and let epithelium cover them. If they are in a district where a thin celluloid splint can be retained, this may be left in place from four to ten weeks assuring epithelial covering of both cut surfaces.

Digitized by Illinois College of Optometry

CHAPTER VII

SOME NEUROLOGICAL PROBLEMS IN RHINOLOGY

The recognition of a distinctive lower half headache (Sluder) which seems referable to lesions of the nasal ganglion and which is controllable by cocainization of the ganglia has gradually led to the observation of a number of bizarre neurological phenomena upon which laboratory experiment can have no bearing. Many of these are so strange as to seem incredible, yet once observed, the facts must be recognized and considered. Many of these phenomena were first recognized as effects of empirical cocainization of the ganglion, i. e., in cases where there were no evidences of disease in the ganglion district to suggest cocainization. The first question to arise is, "Were they not all manifestations of a general cocaine action?" Should this be answered in the affirmative, they are almost as interesting, being new observations on the action of cocaine. As a matter of fact, however, cocaine applied to other parts of the nose and throat does not have these effects.

My interest in these phenomena was first aroused by the fact that each of the symptoms which goes to make up the syndrome of lower half headache could appear separately (Sluder); namely, pain in the forehead, in the eye, in the upper teeth, in the temple, in the ear, in the occiput, in the neck, in the shoulder blade, in the shoulder, and rarely in the arm or forearm; and could be stopped by cocaine applied to the nasal ganglion district. In these cases there was a post-nasal lesion. In the beginning of these experiments I constantly tried cocainization of other parts of the nose as a control, but with negative results. Later, I became able to cocainize the maxillary (outer) side of the district for the anterior pains and the Vidian (inner) side for the posterior pain; the latter including earache and eyeache with photophobia. The results of such cocainizations are almost uniform. Cocainization of the midposition (the ganglion proper) stops both the anterior and posterior distributions of pain. I also found that strange and unusual, inexplicable

Digitized by Illinois College of Optometry

phenomena that were occasionally observed in these cases, such as, for example, lumbago could and did at times appear isolated and could be stopped by cocainization of the ganglion, particularly the Vidian side. Many times I proved that the maxillary side failed. I also found that some cases of lumbago could be relieved in this way where no nasal lesion could be recognized.

A little later (1922) L. W. Dean found that glossodynia could be relieved through the nasal ganglion. I then made the observation that pain in the tongue was not so uncommon in "lower half" headache whether of ganglion or sphenoidal origin. In 1918 I[28] published an observation to the effect that glossodynia was sometimes secondary to lingual tonsillitis and in 1923 I[23] published a report of such a case which did not recover in the wake of the tonsillitis but was relieved by a few cocainizations of the nasal ganglion. Intractable cases have been relieved by alcohol injections into the ganglion.

M. F. Engman has observed eleven cases of so-called burning tongue. No lesions of the tongue were observed except enlarged papillae from constant feeling for the sensation against the teeth, and all of the patients appeared in an almost terror-stricken condition because of fear of carcinoma of the tongue.

In Butlin's text on *Diseases of the Tongue* he gives the following brief treatise on nervous or herpetic hemiglossitis:

"In some of the cases, especially those described by Gueterbock, the affection had clearly a nervous origin, and the inflammation of the tongue was closely allied to herpes of the skin. In the first of Gueterbock's cases, a waitress, aged eighteen, had had a herpetic eruption on the face for fourteen days, with blisters on the tongue for five days. The herpetic vesicles on the tongue, which no longer contained fluid, were strictly limited to the right half of the tongue, extending to the tip, but not to the floor of the mouth. In the second patient, a lawyer, pain began in the ear, with facial paralysis, and on the third day there was a herpetic eruption all over the right half of the tongue. The eruption quickly disappeared, but recovery from the facial paralysis was protracted. In Mackenzie's case there was an eruption all over the tongue, along with herpes on the face. Salivation may occur with the outbreak. The affection may be limited to the lingual branch of the fifth nerve,

Digitized by Illinois College of Optometry

but this occurrence with facial paralysis suggests that the chorda tympani fibers are then involved. When hemigolossitis occurs with facial herpes, it indicates a lesion of the branches of the fifth nerve. The glossopharyngeal nerve is not alone affected, and the hypoglossal not at all. There is no special treatment beyond tonics and nonirritating mouth washes.

"Cases have occurred where an acute parenchymatous hemiglossitis has been very severe, as in Ballard's case, in which an old man, aged seventy-eight, suffered acute pain in the right occipital region, followed by sloughing of the right half of the tongue, as well as of the tip on the left side. The case indicates how difficult it is to draw the line between hemiglossitis and acute glossitis."

In August, 1926, Hoople discovered that cocainization of the nasal ganglion furnished an anesthesia which was satisfactory in opening peritonsillar abscess. He says that it is superior to local injection or topical application.

In 1922 I[34] proved that pain of mandibular surgical injuries was controllable at the nasal ganglion. L. E. Toney in 1923 proved this for toothache (caries) in the lower jaw, with no ganglion lesion. I published in 1922[33] the statement that earache from the eustachian tube and middle ear abscess could be stopped from the nasal ganglion and that despite this, paracentesis was painful. In 1922 H. I. Lillie published a text telling of otalgias and mastoidalgias that had been operated upon in vain through errors in diagnosis, and were relieved through the nasal ganglion. H. W. Lyman has observed the same unfortunate errors; the pains could not be relieved through the ganglion but were relieved by the treatment of sphenoiditis. F. K. Hansel (personal communication) observed a case of abscess of the tongue with otalgia which could be stopped by cocainization of the nasal ganglion.

Dr. Louis K. Eugenheim in 1922 (personal communication) had a patient, a man, age 50 years, with violent acute earache. It was so painful that the examination was difficult. There was a red drum with vesicles in the canal. He had given this patient a half grain of codein every hour without relief. He then anesthetized the nasal ganglion, which stopped all the

Digitized by Illinois College of Optometry

pain, some of which returned later, when he again anesthetized the ganglion, with complete relief and no return of symptoms. French K. Hansel had a similar case (personal communication) in which the pain was relieved by cocainization of the nasal ganglion.

W. M. C. Bryan in a case of herpes of ophthalmic and maxillary distribution with pain in the eyes showed that the ganglion cocainization stopped the maxillary and eye pains but did not affect the ophthalmic pain. Intrasphenoidal cocainization of the lateral wall stopped the pain of ophthalmic nerve distribution but did not stop the eye pain. He showed that the eye pain was transmitted through the nasal ganglion.

In 1924 L. H. Clerf showed that earache as a referred pain from laryngeal cancer, without nasal lesion, could be controlled through the nasal ganglion. In that same year L. K. Gundrum[3] found that the pain of tuberculous laryngitis could be controlled through the ganglion where no nasal lesion existed.

In H. M. Taylor's publication on the endoscopic removal of sand spurs from the larynx and the tracheobronchial tree he refers to certain cases with sand spurs lodged in the larynx that caused aphonia, dysphagia and often pain in both ears.

The observation of Leriche and Fontaine is interesting. They observed certain morbid phenomena in the throat after an operation upon the cervical sympathetic; dryness of the throat, hoarseness and difficulty in swallowing, associated with hyperemia and edema of the tongue, larynx, and pharynx. In a recent case in which the middle cervical ganglion only was removed, all the symptoms were as marked as after more extensive operations. They suggest that this ganglion may represent a vasomotor center for the larynx. In cases in which therapeutic hyperemia is indicated, as in laryngeal tuberculosis, removal of this ganglion might prove efficacious.

In 1923 I[14] showed that external cricoidynia without nasal lesion could be stopped through the ganglion. In 1925 Chas. Ludvey Davis proved that the pain of herpes above the eyebrow could be controlled by cocainization of the anterior ethmoidal nerve in a nose where no nasal lesion existed and that the pain of herpes of the brachial plexus could be stopped

Digitized by Illinois College of Optometry

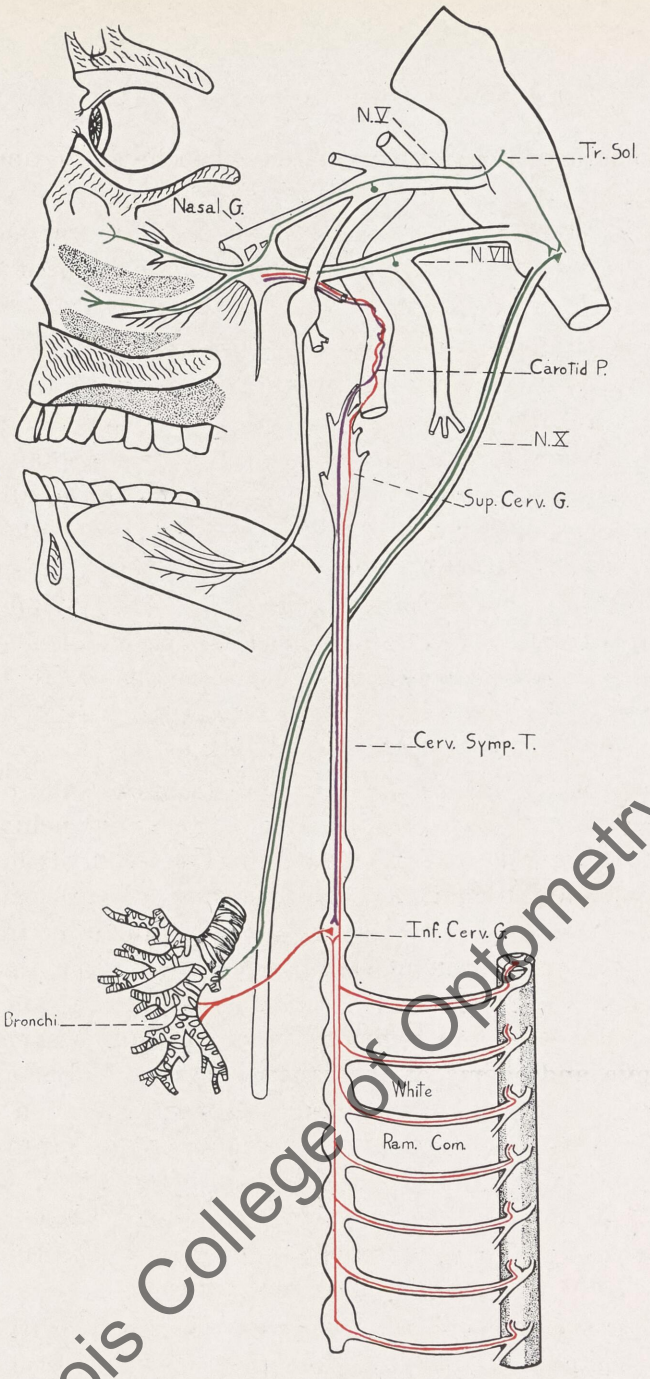

Fig. 155.—Green fibers are the sensory fibers of the trigeminus and the facial nerves showing their connections with the nucleus of the tenth nerve, and how the impulse can then be transmitted to the bronchi. The blue fibers represent the sympathetic system in its course from the nasal ganglion downward, passing through the upper cervical ganglion without being relayed to reach the lower cervical ganglion where it is relayed with fibers that pass into the bronchi. Red fibers are the general sympathetic system. The green fibers in their course are suggested by Dr. S. W. Ranson. The blue fibers from the nasal ganglion to the lower cervical ganglion are my suggestion.

Digitized by Illinois College of Optometry

through the nasal ganglion, without nasal lesion. In that year S. L. Ruskin[1] showed that the pain of herpes oticus was controllable through the nasal ganglion. In the same year he[3] also showed that intractable itching of the auditory canal was controllable in this way.

C. S. Rehfeldt in 1925 reported the control of intractable hiccough through the ganglion. He has since observed two additional cases, making a total of four such cases.

In 1927 F. K. Hansel (personal communication) had a similar case in which the hiccough was controlled by cocainization of the nasal ganglia. I have had two cases of intractable spasm of the face, throat, larynx and diaphragm which came on from voluntary exertion (speech) that I relieved, one by injection of the ganglion, one by sphenoidal operation. I had two others in which I failed.

In 1921 Bruno Goldschmidt-Osmund reported that all syphilitic headache is controllable from the ganglion district. He also reported tachycardia as a phenomenon referable to this district. W. M. C. Bryan in a personal communication told me that he stopped a malarial headache by cocainizing the ganglion.

In 1924 I[26] relieved a spasm of the esophagus of ten days' standing through the ganglion. I[25] have relieved many patients with ophthalmic migraine, some complete pictures, through the ganglion where there were lesions about the ganglion. In one case I relieved an old migraine by injecting the ganglion where no lesion existed. I[6, 9] have relieved asthma by injecting the ganglion and by sphenoidal surgery. Two of these patients had chronic bronchitis with emphysema. In one case of stuttering (unrecorded) cocainization of the ganglion seemed to give some relief but the experiment was not satisfactory—the cocainization failed. I could draw no conclusion. I[15] have relieved three cases of writer's cramp by injecting the nasal ganglia and two cases of pronounced motor weakness of the forearm and hand in the same way (Cases 37, 38). One was a surgeon who was otherwise well (Case 42). He could no longer operate.

In 1925 L. K. Gundrum[1] relieved an old asthma with old intractable eczema by injecting the ganglion. Hiram Byrd[1] in

Digitized by Illinois College of Optometry

1926 relieved pain of an infected wound of the hand, sciatica, and uterine cancer pains by cocainizing the ganglion. H. L. Pollock produced a bad sciatica by injecting the nasal ganglion. The general condition of the patient including a headache was made much worse.

Photophobia is frequent as a part of "lower half" headache and sometimes is intense. I have also known patients to complain of a very painful sense of intense light when no light was present. I have seen this as a part of the sympathetic syndrome and as an isolated phenomenon.

These bizarre phenomena are impossible of explanation, but they permit of speculation.

Aside from the nervus terminalis, of which very little is known in man, the nose is supplied by the trigeminus, the facialis, and the involuntary nervous system. The nervus terminalis is not connected with the nasal ganglion as far as is known. C. Judson Herrick[1] states that it accompanies the olfactory nerve and its function is wholly unknown. All the others are connected with the nasal ganglion.

The cases of pain in the upper jaw and teeth and around the eye are readily explained as referred or projected pains by the maxillary nerve, the lesion being in the ganglion district. Upper jaw toothache may be blocked in the maxillary nerve as it passes through the ganglion. But the pain of lower jaw toothache controlled through the ganglion is not so easily explained. The pain of herpes above the eyebrow (supraorbital) controlled by cocaine to the anterior ethmoidal nerve *at rest* in a nose without recognizable lesion is also inexplicable. To be sure they are terminal branches of the same (ophthalmic) division of the trigeminus, but in Dr. Davis' case cocainization of the ganglion with its maxillary supply, which is also another branch of the trigeminus, failed to give relief. This was true in Dr. Bryan's case also. In Dr. Toney's case cocaine to the anterior ethmoidal nerve gave no relief of lower jaw toothache, but cocaine to the ganglion with its maxillary supply uniformly stopped the toothache. But here, as in Dr. Davis' case, it is cocainization of another branch of the maxillary nerve and not the one directly supplying the teeth. The relief of pain in one branch of a nerve trunk by cocainization of another

Digitized by Illinois College of Optometry

branch of that trunk *at rest* is new. In one of the cases (Dr. Toney's) the involuntary nerve supply is known to be a part of the connection. In the other case (Dr. Davis') it is impossible to assume this as a part of the anatomy or explanation of the clinical result.

In the cases of earache it may seem easier to explain the cases of relief by or through or from the nasal ganglion. In this connection the observations of J. Ramsay Hunt[1, 2, 3] should be familiar. Dr. Hunt has put forth a plea and proof for the facial nerve being a mixed nerve with the geniculate ganglion as the counterpart of a posterior root spinal ganglion and the nervus intermedius (Wrisberg's) as its sensory root. He showed that herpes oticus follows disease of the geniculate ganglion just as intercostal herpes follows disease of the spinal ganglia. He calls attention to the fact that geniculate herpes oticus is limited to the tympanic membrane, the auditory canal and within the helix; that the trigeminus supplies the skin anterior and the upper cervical nerve supplies the skin posterior to this sharply limited zone. He also calls attention to the fact that in cases of herpes the lesion is not limited to one ganglion but that the near-by ganglia take part in a lesser degree, which, however, is insufficient to produce herpes, and that this fact explains the distribution of pain beyond the herpetic eruption. He explains the facial palsy in some of the cases by the fact that the geniculate lesion is in a rigid bony canal which does not permit swelling without pressure on the facial nerve. Dr. Hunt moreover thinks that some cases of otalgia are explained by lesions of ganglia of the acoustic nerve within the internal ear. Dr. Hunt refers to a case of otalgia from reflex dental irritation reported by D. B. Delavan. The otalgia was attributed to the affection of the sensory system of the seventh nerve. A persistent crossed reflex otalgia on the right side was relieved by the removal of the diseased roots of the left lower molar tooth.

These excellent observations of Dr. Hunt are most instructive and in every way helpful, yet in the relief of earache through or by cocaine to the nasal ganglion where no lesion exists and a definite middle ear abscess explains the earache, we are again confronted by perplexities much akin to those found

Digitized by Illinois College of Optometry

in the trigeminal distribution. That a ganglion lesion may give rise to earache as a referred or projected pain is understandable. The great superficial petrosal nerve is the sensory pathway to the geniculate ganglion and the sensory mechanism of the facial nerve. In the relief of earache caused by a middle ear lesion where cocaine is applied to the nasal ganglion, this application is peripheral to the lesion so the relief of herpes oticus pain as such is not easily explained. The cases of Dr. Lillie and Dr. Lyman may be explained on the basis of referred pains. Dr. Ruskin's case of itching auditory canal may also be explained as a referred phenomenon. Dr. Hunt's suggestion that some otalgias may be referable to the ganglia of the auditory nerve raises the thought that some of the otalgias that I have relieved where no nasal lesion existed were, or at least may have been, of that origin. I say this because of the effect of some of the applications noted above.

In consideration of the relation of the fifth nerve to the middle ear the observations of H. R. Lyons[1] are most interesting. He reports four cases of so-called secretory otitis media, in which the ear disturbances followed operation upon the Gasserian ganglion for trifacial neuralgia. The pathological condition in the ear consisted of a transudation of serum into the middle ear. There were no marked inflammatory changes; deafness and fullness in the ear were more prominent symptoms than otalgia which was usually slight. Two of the patients also had corneal ulcer. The most plausible explanation seems to be founded on the possibility of a trophic disturbance and this is explained on the basis of the numerous nerve connections between the fifth nerve and the middle ear.

Louis Hubert[1, 2, 3] has given an excellent presentation of the phenomenon of otalgias. In connection with the sensory system of the facial nerve comes the thought of the part it may and probably does play in the atypical major neuralgias of the trigeminus. As is well known, there are occasional cases that have as a predominent part of the syndrome a definite tic-douloureux, but in these cases there is pain beyond the distribution of the trigeminus. The Gasserian operation may be perfect and stop the recurrent stabbing pains in the trigeminal distribution but a great degree of constant pain may remain.

Digitized by Illinois College of Optometry

These are probably explained by the facial and the deep sensibility of the face to which Loyal E. Davis called attention. I have seen such cases where there was a definite recurrent lancinating pain usually in the maxillary, rarely in the mandibular, nerves, but otherwise they seemed to be "lower half" headaches, treatment for which succeeded. I have seen recurrent stabbing pain in the mastoid and worse at a point 5 cm. back of it (see above), with no pain in the trigeminal area, relieved through the nasal ganglion.

There remain many of the above mentioned phenomena that apparently do not call into question the properties of the trigeminus or the sensory mechanism of the facial nerves. Some of these are motor phenomena. Spasm of the esophagus (Case 40) at the third, fourth, and fifth dorsal vertebrae, cardiospasm (S. L. Ruskin—personal communication), diarrhea, frequent micturition, general spasm of the face, throat, larynx and diaphragm, motor weakness of the upper extremity, writer's cramp, and eczema are phenomena that I am unable to associate with either of these nerves. There is also the occasional case of "nodular headache" (Case 26). The only remaining nerve supply to be thought of is the involuntary system. The nasal ganglion has the cranial, autonomic and sympathetic supplies. The anatomy and physiology and nowadays the treatment of the involuntary system are so complicated and the literature so extensive that they are impossible of full comprehension by a rhinologist busy in the practice of his profession who has neither ability nor time to take up any laboratory study. Moreover it would be an absurd waste of his time for him to enter a field already occupied by the best minds of our generation, who have spent their lives in preparation and work upon these questions. Clinical observation, however, is a field open to the humblest of us and must needs be a matter of routine for all medical practitioners, and each of us must speculate at times in an effort to understand or explain some of our observations. The pathology of the involuntary system is apparently so little and poorly known as to be negligible.

In order to utilize the involuntary system in an effort to understand any of these phenomena it is necessary to assume powers or functions for it that are unknown at present and

Digitized by Illinois College of Optometry

that are impossible of laboratory experimental proof or denial. They are matters of speculation and so far as I can foresee must probably always remain as such.

The well-known functions of the involuntary system; e. g., vasomotor, secretory, and the innervation of the nonstriated muscles; do not help us much in these questions. For a long time it was affirmed that it was an efferent (motor) system only. At present sensory (afferent) fibers are spoken of by many of the authorities at work in this field. Neurons that have their cell bodies in the spinal ganglia are admitted by all to accompany the involuntary pathways, yet stimulation of the central end of the cervical sympathetic cord at the time of a sympathectomy for angina pectoris gives no response on the part of the patient. This experiment was done in March, 1926, in the surgical service of the Barnes Hospital, St. Louis, by Dr. Evarts A. Graham. This is in harmony with the histological and physiological evidence concerning the composition of the cervical sympathetic trunk in animals. In the cat it has been clearly demonstrated that it contains no sensory fibers. Ranson[2] says that the impulses that travel over these fibers do not under ordinary conditions give rise to sensations, but expend themselves in the production of visceral reflexes.

A collective review of the cardiac nerves in angina pectoris has been most comprehensively reported by S. W. Ranson.[1] He presents what is known concerning the rôle which these extrinsic nerves play in angina pectoris. "On the basis of the known facts of anatomy and physiology it is not possible to explain the beneficial results of cervical sympathectomy in angina pectoris. Whether the pain is due to stretching of the aorta, to spasm of the coronary arteries, or to anemia of the myocardium, the pain indicates that there is an irritation of sensory fibers in the heart wall or the immediately associated arteries. The sensory fibers from the cardiac plexus carry afferent impulses to the brain along the vagus nerve and to the spinal cord along the cardiac branches of the middle and inferior cervical sympathetic ganglia, the sympathetic trunk, white rami and upper three or four thoracic nerves. The chief pain in angina pectoris is referred to the chest wall and the inner side of the left arm in the area of cutaneous distribution

Digitized by Illinois College of Optometry

of the first three or four thoracic nerves." Referring to the demonstration of Head in 1893, Ranson states that since pain in visceral disease is referred to the areas of cutaneous distribution of those segmental nerves from which the viscus in question receives its afferent innervation, it is evident that the pain in question is radiated through these upper thoracic nerves and the corresponding white rami. In some cases there is pain and tenderness in the head and neck. This, Head attributes to afferent impulses which reach the brain along the vagus nerve and cause referred pain in the areas of cutaneous distribution of the trigeminal and the third and fourth cervical nerves. In an interesting case of syphilitic aortitis reported by Penfield these pains in the upper part of the neck and head persisted after removal of the middle and inferior cervical and first thoracic sympathetic on both sides. This can best be explained, in line with Head's work, as a reference from the vagus. In regard to operations upon the cervical ganglia he speaks, among others, of the work of Jonnesco who removed the middle and inferior cervical ganglia with good results. Coffey and Brown found that the same results could be obtained by sectioning the sympathetic trunk and superior cardiac nerve below the superior cervical ganglion or by excising this ganglion. The afferent fibers from the heart are not damaged by this operation. The good results are explained on the hypothesis that the pain impulses are caused by arterial spasm and that this spasm is prevented by interrupting the vasoconstrictor fibers for the coronary vessels at the superior cervical ganglion and the superior cardiac nerves.

In Lilienthal's report of three cases of cervical sympathectomy for angina pectoris certain ocular phenomena were present which are worthy of note. In the first case the upper and middle cervical ganglia were removed. An immediate contraction of the left pupil and ptosis were noted as soon as the patient aroused from the anesthetic. In the second case there was very slight pupillary asymmetry five or six weeks after the operation. Following the operation in the third case there was a distinct Horner's syndrome, but no sweating of the face. After the operation on the other side of the neck the face became symmetrical because of a double Horner's syndrome. Ex-

Digitized by Illinois College of Optometry

amination of the fundi showed the nerve head of the right eye negative. The arteries were narrow with a brilliant reflex, and caused an indentation where they crossed the veins. To the temporal side of the nerve head, there were numerous minute spots of degeneration in and about the macula, and to its temporal side there were numerous hemorrhages, fresh and old, and spots of fibrous exudate. In the left eye, the nerve head and vessels were the same as those on the right side, but the hemorrhage and spots of degeneration were very few.

A most interesting experiment on the cervical sympathetic is that reported by Grahe and Metzger. They applied heat and cold to the anterior triangle of the neck and noted the changes as produced in the retinal vessels and oculopupillary mechanism. Ethyl chloride spray or a bottle containing ice water was used for the cold effect. A bottle of hot water for the heat effect. Their conclusions are summarized as follows:

(a) Freezing a circumscribed area of the anterior triangle of the neck with a spray of ethyl chloride is followed within a few seconds by a maximal constriction of the capillary and precapillary vascular region of the retina. After 8 to 10 minutes this constriction changes to a dilatation. After return to normal there is an increased sensitiveness to light. The flow of blood is accelerated with constriction.

(b) Slight freezing causes primary vessel dilatation after a short latent period; according to the strength of the cold effect the return to normal appears with transitory constriction and with changing circumscribed dilatation and constriction.

(c) Freezing of the nape of the neck produces like changes in less degree.

(d) Warm applications cause vascular dilatation which often in a few minutes changes to a spastic contraction.

(e) Under the effect of intense heat (as much as can be borne) immediate contraction appears.

(f) Mechanical irritation of the nasal mucous membrane (with cotton) causes a constriction during the irritation which after one to one and a half minutes changes to dilatation. After 6 to 10 minutes there is a return to normal.

These reactions were observed on the side of the applications but they were present in less degree on the opposite side.

Digitized by Illinois College of Optometry

Oculopupillary symptoms (changes in width of the palpebral fissure, pupil and position of globe) appear and are to be interpreted as stimulation or inhibition of the sympathetic. They are processes parallel to the vessel reactions.

Marked irritation produces primary constriction. Weak irritation produces primary dilatation which returns to normal after a brief negative phase of varying duration.

In the discussion of Lilienthal's paper Dr. George J. Heuer, of Cincinnati, referred to a patient operated upon by his associate, Dr. Reid. In this case the superior, middle and cervical ganglions, together with the cord connecting them were removed. Several months after the operation the patient returned complaining of pain in the face which very strongly suggested trigeminal neuralgia. Various sensory tests showed that his face was not totally but partially anesthetic, this partial anesthesia involving his tongue and the inside of his cheek. He also had disturbances in taste. In other words, he had the sensory disturbances not completely like but similar to those which follow division of the sensory root from trigeminal neuralgia. It was also found that he had sensory disturbance over his left arm, extending to his fingers; he did not appreciate touch or pain, and he did not have the ability to distinguish two points; he had inability to distinguish the form of objects in his hand. He also had sensory disturbances over this thorax to the costal margin.

Huer states that it would appear from Ried's statements that there may be an explanation for these irregular cases of trigeminal neuralgia; that they may, in other words, be examples of sympathetic ganglion neuralgia. In this connection he refers to a patient who had not been relieved from trigeminal neuralgia by sensory root division. Pressure on the superior cervical ganglion provoked attacks of pain which radiated over the distribution of the fifth cervical nerve which were quite similar to the pain from which he had been suffering. He suggests the possibility of relief from the pain by cervical sympathectomy.

Buch apparently showed that under pathological conditions the sympathetic nerves transmit painful sensations. Heitger[1] made the statement that he had had several cases of angina

Digitized by Illinois College of Optometry

pectoris which were relieved by treatment of the sphenopalatine ganglion. That is in confirmation of the work done by the California men who are relieving the pain of angina pectoris by cutting the cervical sympathetic.

In addition to these neurons (see above), Ottoroni Rossi gives a description by Dogiel of neurons that have their trophic centers in the autonomic ganglia whose peripherally directed processes end in the terminal apparatus of the viscera; and their centrally directed processes run through the rami communicantes to the spinal ganglia where they form terminal arborizations about some spinal ganglia cells, chiefly those of Dogiel's Type II. The visceral impulses conveyed by these neurons are collected from the spinal ganglion cells, the centripetally directed processes of which transmit through the spinal cord upwards. Dr. Rossi states that these observations are defended by the minority of neurologists. His findings did not support Dogiel's observations. The neurons which Rossi describes have their cell bodies in the spinal ganglia. L. R. Müller says that we are permitted to assume that stimuli which pass through the sympathetic are conducted through the anterior roots; that those of the parasympathetic (autonomic of some authors) pass through the posterior roots. Albert Kuntz says that according to one school of physiologists the sympathetic nervous system contains no afferent neurons, yet local reflexes are known to occur in the walls of the digestive tube in the absence of extrinsic nerves. This fact suggests the presence of afferent neurons in the enteric plexuses. Furthermore, the morphological relationship as described by him in 1913 and Müller in 1920 suggests that the enteric plexuses constitute a local reflex mechanism involving both afferent and efferent neurons. Le Blanc and Van Wyngaarden state that the sympathetic in cats has bronchial dilators and vasoconstrictors which pass through the stellate ganglion.

According to these ideas there is a mechanism to explain many of the referred pains in nasal ganglion lesions; e. g., the occiput, neck and shoulder pains. The upper cervical ganglion is connected with the first four spinal nerves by slender cords which belong to the gray rami communicantes. It gives off pharyngeal nerves and the superior cardiac nerve. The middle

Digitized by Illinois College of Optometry

cervical ganglion is connected by gray branches with the fifth and sixth spinal nerves. It gives off a thyroid and a cardiac branch. The lower cervical ganglion often unites with the first thoracic. It is connected with the two lowest cervical nerves by gray communicating branches. It gives off the lower cardiac nerve. Whether the referred pain is over a direct pathway or is relayed by synapses in the ganglia will probably never be known. The anatomy shows plausible pathways for the referred pains in the occiput, neck, shoulder and upper extremity. It does not definitely explain the pain which in some of my cases was caused by the injection of the ganglion with alcohol and passed down the vertebral column to the coccyx or into the lower extremity as far as the great toe. J. J. Shea tells of a case in which irrigation of the sphenoidal sinus produced sciatica. H. L. Pollock unfortunately produced sciatica in one case by injecting the nasal ganglion (see above).

One of the excellent recent works on the involuntary nervous system *Die Lebensnerven,* by L. R. Müller, 1924, section by O. Platz "Die Leistungsprüfung des vegativen Nervensystems" does not mention any afferent properties in the nasal ganglion.

In order to attempt to explain some of the phenomena not included in the consideration of possibilities associated with the trigeminus or the facialis or brought forth in any discussion of the involuntary nervous system, it is necessary to assume some additional powers for it that are unfortunately impossible of laboratory proof or denial. It is necessary to assume powers of inhibiting the perception of pain, and of the power of exciting it, and of a power over motor phenomena that is even more difficult to comprehend. These powers apparently depend on an intact general transmission pathway. The power of inhibiting the perception of pain is apparently shown by blocking the nasal ganglion in cases of lumbago when no recognizable post-nasal lesion exists or in the case of Dr. Byrd[2] of trauma of the hand. Dr. Heitger[1] tells of relieving the pain of angina pectoris (also brachial neuritis[2]) by cocainization of the nasal ganglion. This is unquestionably the blocking of the transmission pathway of sympathetic nerve pain, the lesion starting it being coronary. W. R. Brandon reported a case of

Digitized by Illinois College of Optometry

contractured ulnar paralysis which was relieved by treatment of the nasal ganglion. It is obviously very difficult to always separate pains that may be veritable sympathetic pains from others of simple sensory origin. In the lumbagos that I speak of they were unquestionably of simple sensory origin (arthritis in some cases). Dr. Byrd's case was of traumatic sensory origin. It is a definite question whether the result in these cases is obtained by blocking the transmission pathway in the nasal ganglion or is an influence in some way projected into the centers for the perception of pain.

That the pain of all eye lesions may be stopped by cocaine to the nasal ganglion independent of post-nasal lesions is a fact that has been repeatedly observed. That a ganglion or sphenoidal lesion may cause violent eye pain has also been observed repeatedly. Photophobia may be caused by a number of eye lesions and be stopped at the ganglion regardless of post-nasal lesions. It has also been observed in ganglion and sphenoidal lesions. Post-nasal lesions have been known to make the most painful sense of intense light when no light at all was present and the eye normal. The eye is supplied with sensation by the first division of the fifth but that nerve does not convey sense of pain from the eye as shown by Dr. Bryan's case. It is noteworthy also that Dr. Bryan's case was herpes of the first and second divisions and surely of Gasserian ganglion origin. The great eye pain in that case was certainly connected with the second division. The eye and post-nasal district were normal. So clearly was that shown that it raises the question whether the second division does not have more of a part in this phenomenon than might first appear. Further thought, however, recalls the fact that the Gasserian ganglion is joined on its inner side (first division side) by filaments from the carotid plexus of the sympathetic, which raises again the question of what part the sympathetic may play in the production of pain in the eye, and the idea that it requires an intact pathway of the involuntary system for the transmission of the sense of pain when it may be stopped in the nasal ganglion by blocking it at that point. At this time it may be well to recall again that the sense of eye pain and photophobia, whether of organic ocular origin or as a referred phenomenon,

Digitized by Illinois College of Optometry

can be stopped at the nasal ganglion. C. Judson Herrick[1] cites the work of Henry Head, saying that epicritic sensibility is a more refined sort of discrimination than protopathic and is regarded as a later evolutionary type. It includes light touch on the hairless parts of the body, particularly, and the discrimination of the intermediate degrees of temperature. Cutaneous localization and the discrimination of the distance between two points simultaneously stimulated (the compass test) are functions of this system; but pain sensibility is not included, this being wholly protopathic. Herrick is inclined to agree with Trotter and Davis who were led to somewhat different conclusions. They do not regard the protopathic and epicritic series as served by distinct systems of nerves, but as different physiological phases of the same nerve fibers and organs (page 84). On page 299 he says that most sensory nerves may upon occasion function as pain nerves. He also says that Head is of the opinion that the painful impulses do not reach the cortex at all in their simple elementary form but that the painful sensations are essentially thalamic. On page 258 he speaks of "pain nerves (if such exist separately)" and the pain tract in the spinal cord whose anatomical distinctness seems well established and which also seems to have a special significance for painful reactions in the thalamus. On page 259 he speaks of the apparatus for pain being incapable of acting as rapidly as are those of some other sensations. If a sensitive corn on the foot be struck a sharp blow, one will feel a very distinct tactile sensation an appreciable interval before the painful quality is perceived, the latter, however, soon swelling up into consciousness and obscuring the tactile quality entirely. This is an illustration of the fact that even the highly protective exteroceptive painful stimuli pass through a mechanism of slower reaction time than the primary exteroceptive sensations with which they may be associated.

These ideas taken from such high authorities in neurology raise the question whether we are dealing with pain nerves in this effort to understand the mechanism of these phenomena. Especially is this true when one thinks of separate pathways and possibly separate nerves for the transmission of pain. Many of them may pass through the nasal ganglion.

Digitized by Illinois College of Optometry

But there remain in this list motor phenomena that are not at all associated with pain (Case 40) and some complex reflexes (Case 42) and some unquestionably sympathetic pains (angina pectoris), the lesion of which is far removed from the nasal ganglion, and the still more strange phenomena of nodular headache and ophthalmic migraine. (Cases 61 to 67.)

It is difficult (or impossible) to understand how a general spasm of the face, throat, larynx, gullet, and diaphragm may be stopped by treatment of the nasal ganglion (or sphenoid), in cases without any headache or now understood ganglion symptoms. One case was post-nasally negative and one had a high grade hyperplastic lesion. Should one think of the post-nasal lesion as the starting point of an impulse through the great superficial petrosal when that nerve was at rest as far as sensory phenomena went or still more at a peripheral point of a motor nerve which by segmental overlapping may involve the seventh, ninth and tenth cranial nerves for motor phenomena, it is hard to understand why all sensory phenomena should be left out and why or how the eighth nerve should escape or why they should not overlap above (the sixth). One obviously wonders how the lesion could involve the motor fibers of the seventh (great superficial petrosal known to be mostly sensory) and leave out all sensory fibers or at least sensory phenomena. The release of a spasm of the esophagus at the level of the third, fourth and fifth dorsal vertebrae, through or from a normal nasal ganglion district, may be thought of as accomplished by some impulse sent into the vagus nucleus. It is, however, difficult to describe such an impulse to one's satisfaction. Dr. S. L. Ruskin (personal communication) relieved a cardiospasm in the same way.

Such a complex reflex as hiccough is not possible of explanation. It is well-known that it may be most serious and intractable. Cases are known to resist all kinds of treatment and after the entire materia medica has been exhausted, the hiccough may stop after hours or days and the last tried remedy is given credit for the "cure." Nasal ganglion treatment may prove to be merely one more measure added to the list. Dr. Hansel's case and Dr. Rehfeld's cases are, however, well defined, but only five in number. They were of approximately

Digitized by Illinois College of Optometry

fifty hours' duration. B. Deutsch reports one of thirty years' standing. The most unfortunate are obviously those that supervene in the course of some serious malady and kill the patient by exhaustion. I can think of no neurological influence in these cases except some (occult) power exerted through the involuntary system.

The pain of angina pectoris I fancy to be admittedly of cardiac sympathetic origin. Dr. Heitger[1] has controlled it in or through the nasal ganglion. This is remarkable inasmuch as the ganglion is not in the line of reference (upper extremity). It may be (one may think it must be) in the line of transmission to perception (thalamus); or that unknown (call it occult) power of the involuntary system to interfere with protopathic pain perception must be thought of and this accomplished by blocking it at that point.

"Nodular headache" in my experience is not a frequent complex. I have seen eight cases. They were all headaches from post-nasal lesions, with the pain controllable from the nasal ganglion. Nodules would appear under the skin of the neck, sometimes under the scalp, usually at the height of the pain. Their appearance followed the distribution of the lymphatic glands as given by Bartels. In one case they disappeared in two hours after the pain was stopped (right) at the ganglion. On the other side in this patient (left) the control of the pain was not complete that day and the nodules lasted twelve hours, to disappear only as the attack subsided which was the usual course. In other cases I failed to get such a response. They subsided only as the patient in general became better. The nature of these nodules is not known. Auerbach and others have cut them out but could draw no conclusions from the examination of them. By some observers these nodules have been thought to be the cause of the headache. To me they seem to be an accompaniment of it and a result of some action on the part of the involuntary nervous system but not the cause of it. Myalgia of the sternocleidomastoid and the trapezius is usually a part of "lower half" headache. It is apparently a protopathic pain and may give rise to such soreness that motion and even light touch are very painful, almost intolerable. It have repeatedly stopped it at or from the nasal

Digitized by Illinois College of Optometry

ganglion. It may be intermittent and isolated. I have seen it pass as golf cramp and violin cramp and wryneck and stopped it (for years) by injecting the nasal ganglion. Aswadurow and Syöstrom believe it to be the cause of the headache and connected with the upper cervical ganglion, which they say is tender to pressure in these cases. I have often tried to determine this. When the pain is not present, pressure over the ganglion is not painful, but when the pain is present, pressure at that point is painful but no more than at other points in the painful distribution. These cases definitely have the posterior pain of the "lower half" headache which may or may not be isolated, i. e., the anterior distribution being absent. It may continue long after the anterior part has stopped. Such cases are those in which the nodules appear. Aswadurow has described pupillary changes in these cases. I have not seen such cases, although I have seen the "myalgias" in hundreds.

Ophthalmic migraine has always been a most mysterious syndrome, which when complete begins as hemianopia or scotoma with or without colors, followed by headache usually of "lower half" type, later by nausea or vomiting, then aphasia, then hemiparesis or hemiplegia. The complete picture does not occur often. I have seen nine such cases. The aphasia and hemiparesis are usually omitted. An infinite number of minor variations have been described. The scotoma may be the only manifestation of the attack. In one case the scotoma appeared last. I have seen many migraines. All except one had post-nasal lesions. I have relieved these cases by treatment of the nasal ganglion or the sphenoid. In some the relief has lasted ten years but these must not be considered "cured" because a post-nasal inflammation *can* produce the attack again and sooner or later this will almost surely happen. Migraine is usually spoken of as hereditary; i. e., the parents or grandparents, one or more, had such attacks. I believe the hereditary feature to be on the part of the involuntary system rather than on the part of the post-nasal lesion. It is also thought to stop after the menopause in women and with advancing age in men. There are many cases in which no heredity can be determined and which do not stop with advancing age. I have seen the hyperplastic lesion in the nose also undergo involution after the

Digitized by Illinois College of Optometry

menopause. In one case that I have observed from time to time for twenty-seven years this was clearly shown to go hand in hand with an intractable "lower half" headache. In this case I saw the primary infection, an acute suppurative pansinusitis in a strong healthy woman twenty-six years old. The attack was very severe. The suppuration stopped; the headache continued. All nasal surgery was finally done for its relief. All sinuses were still open, but the hyperplastic lesion which began in the wake of the primary attack continued well marked in the post-ethmoidal-sphenoidal district until the menopause at forty-eight years. This was three years ago, and since then the post-nasal lesion has *disappeared,* and the headache which was never absent for more than ten days at a time has *stopped.* Once in these three years (six months ago) she had a severe acute post-nasal inflammation with headache for eight days. She is still a strong normal woman. To be sure, this case was not an ophthalmic migraine, because of the endlessly recurrent headache; however, it may well be classed as a vulgar migraine. (Liveing states they are classifications of the same disorder.) Much of the time she had severe myalgia of the sternocleidomastoid and trapezius, right and left. She has autumnal hayfever with severe asthma. Seven years ago I injected the nasal ganglia. In this time she has not had asthma and last year the hayfever was much the mildest in her experience of many years.

There are probably a number of causes for migraine. All that I have seen, however, had definite postnasal lesions, i. e., nasal ganglion or sphenoidal except one. A woman 65 years of age had had ophthalmic migraine (aphasia and hemiparesis missing) since her girlhood. Fourteen years prior she developed a major neuralgia of the left trigeminus which was cured by Gasserian ganglion operation. Seven years prior to my observation she developed an ordinary general headache from a sigmoid-rectal narrowing, nonmalignant. This headache came on in the early morning each day. Dr. R. Walter Mills who sent the patient to me instructed her in abdominal exercises which moved her bowels and uniformly stopped this headache for the day. She continued to have migraine every four to ten days. It appeared right- or left-sided regardless of the Gasserian ganglion operation. The most painstaking observations of her

Digitized by Illinois College of Optometry

nose over a period of three months failed to reveal any lesion. It was normal as far as clinical recognition was possible. Despite this and the fact of the Gasserian operation, cocaine applied to the nasal ganglion district stopped the migranous attack. Other parts of her nose gave no result with cocaine. Injection of the nasal ganglia stopped the migraine for two years when she passed out of observation. In that time she had one severe coryza which reestablished the migraine. It subsided in the wake of the coryza. The morning digestive headache continued. This case has some interesting features. (1) There were three distinct painful phenomena in her head. (2) The Gasserian operation which cured the major neuralgia of the trigeminus (tic-douloureux) had no influence on the migraine; (3) nor did the digestive lesion. (4) The migraine was stopped by injection of the nasal ganglia despite the fact that no clinical lesion existed in that district. The facial and the involuntary nervous systems were the only supply on the left side. It is difficult to deny the part that any one nerve may play in these cases. So far as I am able to judge, however, the facial took no part in the migraine (no earache). This leaves only the involuntary system to have been affected by the treatment. The responsibility of the sympathetic in the etiology of migraine was first advanced by du Bois-Reymond. He thought it related to the cervical sympathetic. In his case there was enlargement of the pupil with pallor. Other cases are described (Flatau) where no pupil changes occurred and no pallor existed (redness in fact). It may be that the cervical sympathetic as an etiological factor will cause pupillary changes. The cases that I have seen as stated above did not have them. If the sympathetic be the etiological factor as is fairly shown in the above cited case, in all probability it (migraine) may be started from various parts of that system. Probably the other parts of the involuntary system also have the property of exciting the attack. The starting point could not be determined in this case. In the nasal ganglion both the autonomic and sympathetic are found. Whether the migraine be started in one or the other system, both transmission pathways may be blocked there, and should it be proved that an intact pathway is necessary for the development of the attack we have the explanation of how the clinical

Digitized by Illinois College of Optometry

result is obtained. I have not seen post-nasal cases that reminded one of kinship to epilepsy. If the involuntary system be accepted as that by which migraine is produced, one must think of an impulse sent into its center in the hypothalamus and transferred to the pain center and the visual center which are closely related, but how nausea, aphasia and hemiparesis may be produced is not easy to even speculate upon.

Hiram Byrd[2] has advanced an ingenious idea for the development of painful sensation, to the effect that a "pathological impulse" exists in the nasal bloc (the general nose) or elsewhere, and that it remains below the level of consciousness until some injury happens. Then it is sent into the region of lowered resistance to be perceived as pain. I fancy it must be sent over the transmission pathway of the involuntary system. In that hypothesis the pain of trauma as now understood must be denied. The painful impression is established only after the arrival of the pathological impulse. According to Dr. Byrd this impulse may be the cause of painful sensations but not of motor phenomena.

Dr. Byrd[2] has made some interesting clinical observations. I think, however, that (1) some of them are referred pains from the post-nasal district; (2) that some are explained by the transmission of pain by the involuntary system; (3) that some deal with special pain nerves (probably); (4) and that, where the "pathological current" responsible for the clinical manifestation that he has observed, it should give rise to the motor phenomena that have been observed as controlled in, through, or by means of, the nasal ganglion. In an obscure field like this it is as yet impossible for one observer to be familiar with all possibilities. I have not as yet had the material that permitted confirmation of Dr. Byrd's observations.

In a conversation with Dr. Jonathan Wright he made the following note:

"In this connection it may be well to remark that the physical chemical process is one of lipoalbuminous nature by the interposition of the process as entirely distinct from the electric force itself, but the formation of surfaces by the first current sets up an apparatus for another current so that we thus get a delay that would tend in the total time consumed

Digitized by Illinois College of Optometry

to equalize the speed of the electric current with the nerve current. This sort of mechanism finds support in the processes of infection through cellular surfaces at the periphery of the body or between internal cellular surfaces. It may be grouped under the general concept of a change of surface tensions. In the course of recovery from acute and chronic infection processes of inflammation of the mucous membranes, especially of the tonsil, but also noted in other places of the respiratory system, there is the production out of neutral fats into soap and probably cholesterin and lecithin. Stains for these have shown such lipoid combinations in much greater abundance than in normal membranes which have not recently been in a state of inflammation. They probably represent the end stages of resistance of the surfaces to infection. We thus find a connection by transferring this conception to physiological changes in the synapses and ganglia of the nervous system a reasonable explanation. A working hypothesis of this kind will at least furnish a support for lines of future research on the physiology and pathology of the processes with which we have to deal in this connection. It is interesting and suggestive that we thus are able to call into service the same forces which deal with surface immunity, reproduction of cells and of mechanical processes of muscle contraction which are associated with the appearance of lactic acid."

In thinking of the pathological impulse one at once recalls the observations of Müller and Dahl as a possible explanation when all clinical observations fail to recognize a lesion as a possible starting power for the "impulse." They found the nasal and otic ganglia cells degenerated in adult human life but not in early life. The clinical manifestations in early life are, however, not different from those of later life so far as the post-nasal district is concerned. They are, however, not so frequent, nor is this entire problem so frequently met with in childhood. Dr. Byrd excludes the sphenoid as a starting power for the impulse. According to my observation for all that relates to the nasal ganglion clinically it is an indivisible part and parcel of the post-nasal lesion. The clinical manifestations may arise from one or the other, or both. (The reader should be referred to Dr. Byrd's texts.[1, 2, 3])

Digitized by Illinois College of Optometry

Recently E. F. Müller published some most interesting observations upon the involuntary nervous system. He found that intradermal (not subcutaneous) injections of minute quantities of physiologic sodium chloride solution, distilled water, lactalbumin milk, or even air caused an immediate sudden fall in the leucocytes of the vessels of the periphery. Later, they are sent to lesions at some remote point. "For example, if in chronic gonorrhea strong or weak stimulants of the skin are employed, an abundance of young, fresh leucocytes are produced and can be found in the excretion of the urethra where they were previously found only in very small numbers." It is of further interest that the beginning of the leucocytosis is connected with a similar parasympathetic (autonomic) influence on the dilatation of the blood vessels of the bone marrow system. Additionally there is the significant determination that even entirely nonspecific agents, such as sodium chloride solutions will effectually increase the blood sugar if injected intradermally. Summarizing, when excitants enter the body two great systems of organs participate in setting up the ensuing reaction, either alone or in combination with others, one, the bone marrow system, the originator of the properties and cells prerequisite for resistance, and probably also the originator of the ferments of specific resistance; the other, the involuntary nervous system, the conductor of impulses of stimulation from an infected area to the myeloid system and at the same time the regulator not only of the vessels but also of their leucocytic content.

Besides this first increase of leucocytes at the site of infection, there is later observed a decided increase in the number of leucocytes in the entire blood stream due to an increased activity of the myeloid system. This produces not only the elementary cells but also their specific ferments.

"The resulting increase in cell production of the myeloid system may spread to involve all portions of the bone marrow capable of transformation. If this process continues undisturbed, it will produce a total increase of normal, fully developed myeloid cells, presenting the clinical symptoms of typical leucocytosis."

Dr. Müller naturally believes that the involuntary nervous

Digitized by Illinois College of Optometry

system conveys the impulses both afferent and efferent, and that it is the parasympathetic (autonomic) system through which the results are achieved. In experiments with insulin he found that epinephrin, which stimulates the sympathetic system, interfered with its (parasympathetic) action and that atropine, which paralyzes the parasympathetic, interferes with it or nullifies it. In Dr. Müller's observations it is obviously conspicuous that there is afferent action of the involuntary nervous system. His observations are possible of proof. They are intensely interesting and far reaching in their possibilities. They show that afferent impulses that are not sensory or motor in the ordinary sense are transmitted by the involuntary system, and at some central point (hypothalamus) are transferred to another division of that system to result in activity of the myeloid system.

It may be argued that in the above discourse there are too few cases included to permit of conclusions or arguments, which is true. Many cases in the observations of many trained clinicians will be necessary before formulas or statistics will be possible. The constancy of phenomena and exceptions to the rules require this. I have no idea that phenomena mentioned above will prove any more constant than phenomena in other fields of medicine, but there is no unique case (in my experience) where the clinical picture becomes fixed in the mind of the observer. He more readily recognizes it when next presented. He recognizes it under conditions that before did not attract his attention. All of the above phenomena with one or two exceptions have been recognized by more than one observer.

Should one think that these phenomena (or some of them) are wrought through the involuntary system, it does not become easier to picture to oneself the nature or mode of the process. The diversification of the phenomena is primarily difficult of comprehension. To me the manifold referred phenomena that have been witnessed by many observers in cases where recognizable lesions existed in the nasal ganglion district are indeed interesting and not always easily explained. But the remarkable, bizarre effects that are seen in cases where no lesion is recognizable and where there are no symptoms to suggest

Digitized by Illinois College of Optometry

such a lesion are verily astounding, no matter how the observer may try to explain them. I fancy Dr. E. F. Müller's observations will be readily admitted to this class. It seems to me that the above cited phenomena are no more surprising as to speculation than his are as to facts. Most surprising effects are obtained by cocaine or alcohol blocking in cases in which the ganglion district is clinically normal or at least where it is at rest so far as symptoms go or so far as clinically recognizable lesions exist. Some of these phenomena have well known involuntary nervous system connections; e. g., with the vagus (autonomic), namely, spasm of the gullet, which is motor; pain of laryngeal tuberculosis and external cricoidynia, which are sensory. These would be more readily understandable as referred phenomena in cases in which ganglion lesions existed, but in laryngeal pain of organic origin the sensation is not travelling to the periphery; it is travelling to the brain and is stopped at another place in the periphery. In other cases there is no connection with the vagus or any other involuntary connection more than the fine ramifications of that system that extend throughout the whole body. In this class are eye pain and lumbago of organic local origin. These sensations are travelling to the brain; stopping them in the nasal ganglion is at another point in the periphery. These cases have no nervous anatomy to explain them unless it is the involuntary system. The motor phenomena—spasm of the gullet, writer's cramp, spasm of the face, throat, larynx, and diaphragm, weakness of the upper extremity and contractured ulnar paralysis—seem to me even more difficult to explain.

In an effort to understand these phenomena one thinks of several possibilities. (1) Are they produced by an inhibiting influence interposed in the transmission pathway? This question is at once vague because of the difficulty or impossibility to conceive what is the pathway. This question obviously relates to sensory phenomena. It is irrelevant to the motor phenomena unless one can conceive of motor pathways utterly unknown and of a nature that there is every physiological reason to disbelieve. It must be evident that this question can have bearing upon or relation to referred pain in cases with a recognizable lesion in the ganglion district. (2) Are they pro-

Digitized by Illinois College of Optometry

duced by an effect of cocaine that is stimulating instead of paralyzing? This seems to be answered in the negative by the fact that many times they have been made permanent by the injection of alcohol into the ganglion district. Alcohol is destructive. Regeneration is slow. (3) Do they depend on an intact involuntary pathway? Could they be produced by blocking that pathway at some other point? Motor as well as sensory phenomena may be included here. This may sometimes be affirmed or denied. It is not out of range of possible experiment. The relief of angina pectoris by removal of the upper cervical ganglion seems to argue for affirmation. As a referred pain from the heart, one would assume it to be transmitted through the lower cervical ganglion. The control of this phenomenon in or through the nasal ganglion adds plausibility to this argument. (4) Are we dealing with the transmission pathway of nerves whose function is the transmission of painful sensation only? Obviously the motor phenomena without pain cannot come into this question. I know of no way to argue affirmation or denial of this question. (5) What is the mechanism by which anesthesia of one branch (at rest) of a sensory trunk stops pain in another branch; e. g., anesthesia of the anterior ethmoidal, stopping the pain of herpes of the supraorbital branch of the trigeminus or cocainization of the anterior tip of the middle turbinate stopping pain after tonsillectomy, as I have often done? Dr. Byrd[2] has stopped pain in tonsil wounds through the nasal ganglion. (6) Do these phenomena come to pass by virtue of the proximity of the central nuclei of the respective nerves involved, i. e., by segmental overlapping? I should think this very likely. But one at once is perplexed when he tries to think of the nature of the influence through or by which they are effected. Any known action of cocaine fails to explain it and the destructive action of alcohol leaves one equally at loss. In this connection, however, the close association of the involuntary and pain centers in the hypothalamus and thalamus is to be noted. Should one think of cocaine being absorbed into the nerve sheath and then conveyed to the centers, it should also be remembered that cocaine applied to other parts does not have the same effect.

Many facts are cited above, and many questions have been

Digitized by Illinois College of Optometry

raised concerning them with no answers given. There are four outstanding items. (1) The widespread referred pain which seems to be undoubtedly from the nasal ganglion. (2) The bizarre control, by means of the nasal ganglion, of pain which seems irrelevant to the nasal ganglion. (3) The bizarre control, by means of the nasal ganglion, of motor phenomena which seem irrelevant to it. (4) The control of pain in one branch of a nerve by anesthetizing another branch at rest. (a) The referred pain may be explained by assuming afferent attributes for the involuntary system either by segmental overlapping of nuclei or by reference transmission independent of the nuclei. What part special nerves for the transmission of the pain sense may play in this seems to me impossible to even speculate upon. The trigeminus is not the system through which these effects are obtained, nor is the facial, although no estimate of it seems to me possible. (b) The control, through the nasal ganglion, of pain which is apparently irrelevant to it seems to me explicable only by means of some power of the involuntary system that at present is incomprehensible. To call it a pain-inhibiting power is not readily comprehensible when one recalls that the result is obtained by blocking. It is not easy to give it a name. I should think it is done in the centers (hypothalamus, thalamus, involuntary and pain centers). (c) The control of motor phenomena through the nasal ganglion seems more difficult to understand. Possibly it is related to the (b) pain control. (d) Comprehension of the mechanism of the control of pain in one branch of a nerve by anesthesia of another branch at rest is beyond my powers of speculation.

In a recent publication of the results of experiments on animals to determine the relation of the cervical sympathetic to the larynx Kakeshita draws the following conclusions:

"(1) In dogs, cats and guinea pigs anastomoses between the cervical sympathetic and the laryngeal nerves could not be demonstrated.

"(2) By microscopic examination of these nerves, according to the method of Weigert, no nonmedullated fibers could be recognized.

"(3) The cervical sympathetic contributes no motor fibers to the laryngeal muscles.

Digitized by Illinois College of Optometry

"(4) The cervical sympathetic does not participate in the secretory sensory or trophic innervation of the larynx.

"(5) The cervical sympathetic contains vasomotor fibers which reach the larynx by way of the periarterial plexus.

"(6) The sympathetic is not concerned in the tonic innervation of the laryngeal muscles in which accessory nerve elements are demonstrable."

A great deal of other very interesting work also has been done on the sympathetic nervous system, not only in the form of experiments, but for the relief of a great many diseased conditions, especially of the lower extremities. Among the various diseases treated, the following are particularly worthy of note: Raynaud's disease, spastic paralysis, malignant hypertension, polyarthritis, trophic and post-traumatic ulcers, causalgia, various edemas and certain skin diseases. Adson and Brown reported on the treatment of Raynaud's disease by bilateral ramisection and ganglionectomy in conjunction with bilateral perivascular sympathetic neurectomy of the common iliacs. The operation was followed by vasodilation with increased arterial flow. The subjective and objective symptoms of the disease were relieved. Measurements of the skin temperature and calorimetric studies of heat radiation of the feet indicated hyperthermia and definitely maintained vasodilation.

In Adson's report on "Ramisection for Spastic Paralysis" he states that this operation does diminish spasticity. He quotes Royle[1, 2] who stated that muscular rigidity is the greatest factor in the production of disabilities and deformities in conditions of spastic paralysis. Boecke proved that voluntary muscles are supplied by nonmedullated fibers from the sympathetic nervous system.

In this connection the report of Coman on *Observations on the Relation of the Sympathetic Nervous System to Skeletal Muscle Tonus* is interesting. His experiments on animals led to the deduction that inasmuch as none of the conditions essential for the proof of the sympathetic innervation of skeletal muscle could be observed, the conclusion is evident that there is no direct relation between the sympathetic nervous system and the development or maintenance of postural tonus in cross-striated muscle.

Digitized by Illinois College of Optometry

The relation of the sympathetic nervous system to skeletal muscle, however, is explained by Gantt who summarizes the work of Orbeli by saying that the sympathetic nervous system exerts a profound influence over the physicochemical changes occurring in skeletal muscle, accompanied by a modification of the functional ability of that muscle. These changes influence, it seems, the conditions of the motor end-plate, calling forth transformations in the efficiency of the corresponding muscles. This forms a sort of regulatory mechanism for the expenditure of muscle strength, and governs the condition of impulses by the motor nerves. From this point of view, the sympathetic innervation of skeletal muscle is an adaptive innervation through which the functional ability of the muscle is determined.

The observations of Kanavel, Pollock and Davis on the relation of the sympathetic nervous system to muscle tone seem to indicate that histologic evidence points to the dual innervation of skeletal muscle by the cerebrospinal and sympathetic nervous systems. They also state that the sympathetic nervous system may have some function dealing with the metabolism of muscle so that under certain conditions the contractility of muscle may be changed by the removal of sympathetic impulses. Such a function would probably be chemical in nature.

In the treatment of malignant hypertension by lumbar sympathectomy Rowntree and Adson[2] found a relief for vascular spasm by removal of the vasoconstrictor influence of the sympathetic nerves of the vessels of the leg. The operation was followed by a sensation of heat and burning in the legs. The feet were hot, dry and of a rosy red color. There were no changes in the reflexes. Application of heat caused pain but no sweating. There was an increased heat production and radiation of 30 per cent associated with definite and considerable increase in surface temperature. The blood pressure was lowered but again became elevated. Adson and Rowntree[1] also employed this operation for the treatment of polyarthritis, with the idea of obtaining results through an increase in the circulation and heat production. Very definite improvement was noted and the results were encouraging.

In Ranson's[3] publication on the anatomy of the sympathetic nervous system with reference to sympathectomy and ramisec-

Digitized by Illinois College of Optometry

tion he states that periarterial sympathectomy has caused renewed interest in the innervation of the blood vessels, but the results seem to indicate that the vasoconstrictor and sensory fibers for the peripheral vessels accompany the main arterial trunks into the limbs and this is in conflict with all that is known regarding the innervation of the blood vessels.

Despite Leriche's assumption that the constrictor fibers for the cutaneous blood vessels take a course analogous to the splanchnic vessels, Ranson believes with Kramer and Todd that there is no fundamental difference between man and laboratory animals and that constrictor fibers accompany the spinal nerves, very few accompanying the larger arteries for any distance toward the periphery.

No satisfactory explanation has been found for the hyperthermia following following periarterial sympathectomy nor for the relief of pain afforded some patients thereby. The blood vessels possess sensory fibers, but these run centrally in the spinal nerves. Ranson suggests that the relief from pain may depend on the hyperemia and resultant improved peripheral nutrition.

From an experimental study on the effect of the sympathetic nervous system on the peripheral vascular system Mosser and Taylor drew the following conclusions: "(1) Periarterial sympathectomy in dogs and cats has uniformly failed to produce hyperthermia. (2) Alcohol injection of the sciatic nerve in sufficient strength to produce motor paralysis has resulted in a constant hyperthermia. (3) The minimum concentration necessary to produce paralysis produces a maximum hyperthermia. (4) Recovery of motor function occurs in practically all cases, even though concentrated solutions are used. (5) The procedure is worthy of clinical trial."

Digitized by Illinois College of Optometry

CHAPTER VIII

SURGERY OF THE MAXILLARY ANTRUM

Surgery of the maxillary antrum may be radical or conservative. The former which opens the antrum in some way that permits the curettement of its lining membrane for the relief of advanced pathological changes consequent to suppuration, granulation and necrosis with polyps is never required for the relief of the uncomplicated hyperplastic changes so far as I know. Should the outlet to the antrum become closed as in the cases described by Lynch, the simple opening at another place for ventilation answers the purpose. The well-known Caldwell-Luc and the Denker radical operations therefore need no description here. The procedure which has all the advantages and no disadvantages for this purpose is one which I described in 1909. Furthermore it answers for most of the suppurative cases.

The Author's Antrum Operation

The idea of entering the antrum through the nasal wall and later of conserving the lower turbinate in antrum surgery has occurred to various surgeons. So far as I know the first completed procedure of this kind was at my hands in July, 1906. In February, 1907, Hirsch conceived and performed what is practically the same operation. He reported his procedure in the *Wiener Medizinische Wochenschrift,* July 4, 1908. My report was in the *Laryngoscope,* December, 1909. He confined his operation to the lower meatus. Mine includes the middle meatus also. Aside from this, there are some other small variations in our techniques. Both have as cardinal idea the conservation of the lower turbinate with drainage or ventilation.

The operation of opening into the antrum of Highmore through the lower meatus of the nose was first described by M. Schaeffer in 1885, next by Mikulicz in 1886. It seems to be known usually by the name of the latter. Lack describes and

Digitized by Illinois College of Optometry

suggests leaving a cannula in position so that the patient may wash through it.

Rhinologists now seem agreed that the intranasal operation is the choice of the conservative methods, both as affording permanent drainage and doing away with the necessity of habitually wearing a plug in the alveolus. Should these conservative means prove insufficient, and a radical operation be required later, the opening into the lower meatus will not have been in vain. Its great drawback is the removal of a considerable portion of the lower turbinate, which is followed by drying of that nostril. Furthermore, the stump is very apt later to become hypertrophied, in which case it may have to be removed with the disadvantage of causing increased dryness of the nose. Hajek[2] emphasizes this tendency to hypertrophy, and offers the explanation, that it is probably a result of congestion following lesions of the blood vessels incidental to the resection.

At the meeting of the American Medical Association, Section of Laryngology, held in Chicago, June 1, 1908, while discussing Canfield's "Submucous Resection of the Lateral Wall of the Nose," I described my own modification of the "Mikulicz" operation. The operation, as I then described it, and as I have performed it for the past sixteen years, is often simple in execution; and, when properly done, assures a permanent, free opening, for drainage. It avoids, moreover, the subsequent drying, which is the only drawback to the lower meatus operation. It involves only an insignificant lengthening of the time required in operating.

Within the past five years I have modified the procedure (heretofore unpublished) by which the membrane of the lateral wall is turned into the antrum.

The procedure consists of cutting the lower turbinate by means of scissors from the lateral wall as far back as its posterior third or fourth. The detached part is then pushed up out of the operative field. Should there be any difficulty in retaining it in that position the long blade of the speculum, Fig. 156, is introduced between it and the lateral wall. The short blade rests on the frontal process of the maxilla. It is then slowly and forcibly opened, pushing the detached portion of the lower turbinate against the septum and still further until both turbinate

Digitized by Illinois College of Optometry

fragment and septum are pushed into the opposite nostril. This leaves the lateral wall of the lower meatus in good view. A vertical incision is then made on the lateral wall just back of the frontal process of the maxilla. An elevator is then introduced under the membrane and periosteum (Figs. 157 and 158) which are readily raised as a rule. The bone of the lateral wall just back of the frontal process is then perforated either by the barb blade of the forceps shown in Fig. 156, or by an independent perforator such as that shown in Fig. 157. Should an independent perforator be used the barb blade of the forceps (Fig. 156) usually may be easily introduced into the opening either as a separate barb or with the two blades locked in forcep fashion. The initial opening into the antrum is thereby made and may be readily enlarged by a Knight forceps or whatever the surgeon may elect. The final opening should include the

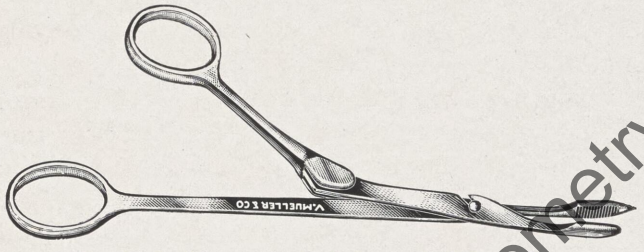

Fig. 156.—The author's intranasal forceps.*

entire antral wall of the middle and lower meatus. The membranous wall which has been elevated should be intact. It is now divided in a horizontal line at its middle (Fig. 159). The upper part is turned up into the antrum, and the lower part is turned down into the antrum, covering the wounds of the bone made in the removal of the wall. A loose pack of thin gauze is then placed in the cavity to hold the membrane in place (Fig. 161). The turbinate is now put back into its original position and a thin splint of compressed cotton (Simpson's splint) is placed between the turbinate and the septum. As the splint expands by the moisture it holds the turbinate in place; or the anterior end may be sewed in place (Fig. 162). It usually adheres in place in 48 hours. The thin strip of gauze which packs the cavity should have a free end in the lower

*Sold by V. Mueller & Co., Chicago, Ill.

Digitized by Illinois College of Optometry

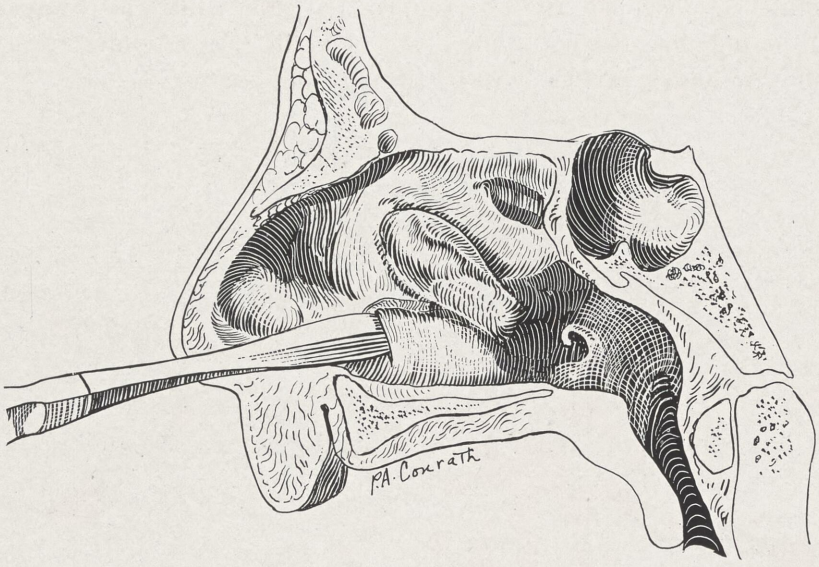

Fig. 157.—The lower turbinate has been detached with straight scissors at its anterior two-thirds, and pushed upward. A sharp-pointed elevator is used to perforate the lateral wall of the nose with the point well forward.

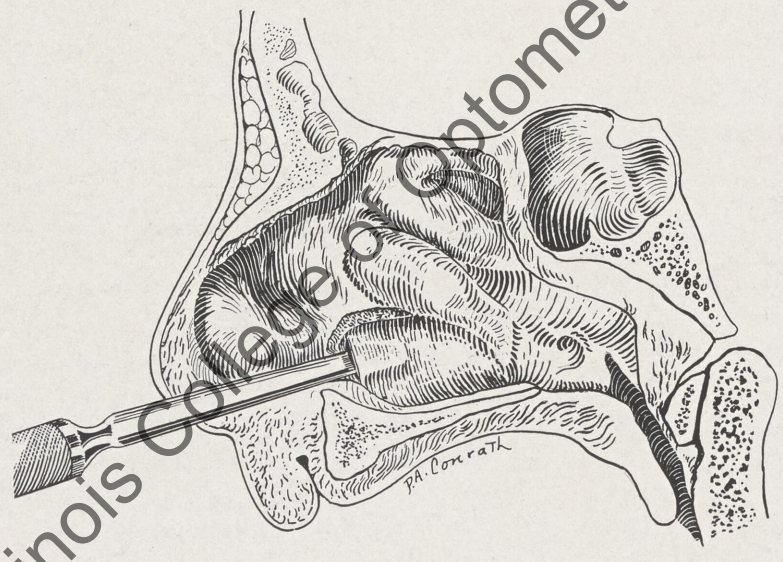

Fig. 158.—Showing an ordinary septum elevator which has entered the perforation shown in Fig. 157. This instrument is used to elevate the membrane from the lateral wall of the nose, as in submucous resection of the septum.

Digitized by Illinois College of Optometry

meatus which permits its removal in 48 hours. Should the turbinate be loosened by the removal of the pack the Simpson splint may be again put in place to hold the turbinate for another 48 hours when it will be found adherent.

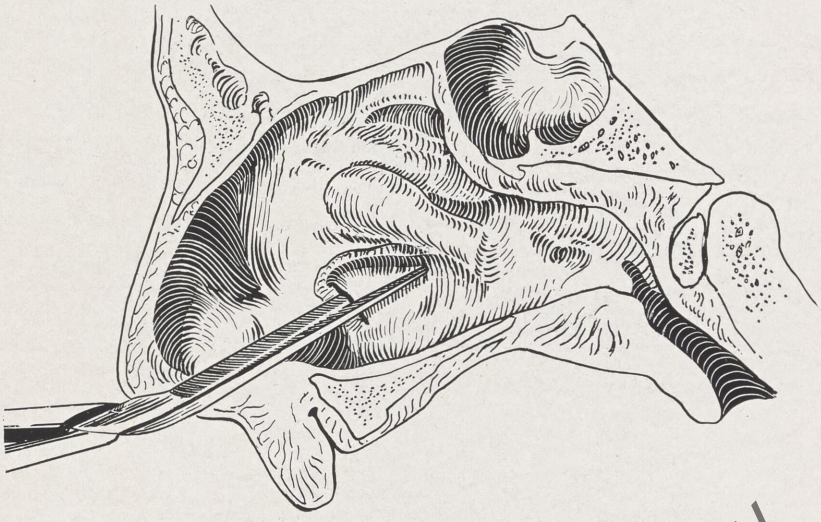

Fig. 159.—Shows a pair of scissors used to divide the membrane at its middle after it has been elevated as shown in Fig. 158.

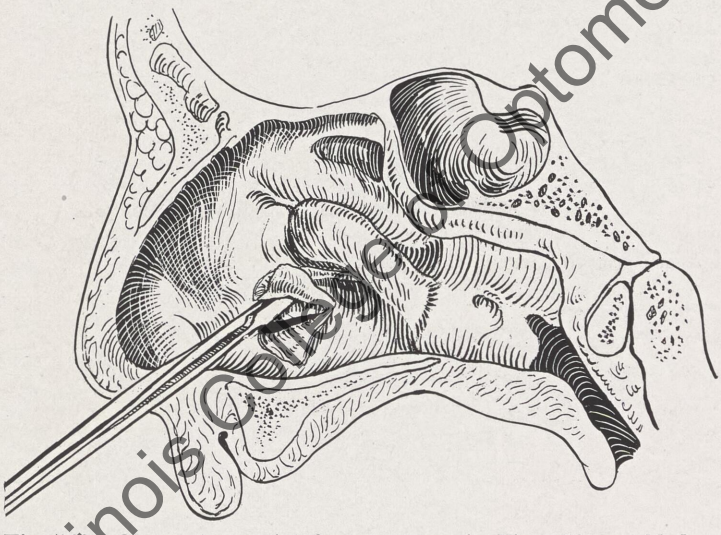

Fig. 160.—Shows the special forceps shown in Fig. 156, one blade of which has been introduced into the antrum, the other under the nasal membrane already elevated. The forceps may be introduced as obstetrical forceps, each blade singly. Sometimes this is a great advantage.

Digitized by Illinois College of Optometry

Fig. 156 shows a separable forceps, helpful in making a quick effective entrance to the antrum from the nose. When the wall of the lower meatus passes outward as well as backward it is often difficult to secure a satisfactory beginning for the opening because an ordinary biting forceps fails to effect the first bite—it slips. In order to overcome this difficulty I have made one blade of these forceps lance-like. It is separated from its cup-shaped fellow. It is passed through the anterior limit of the nasal-antral wall just as a straight

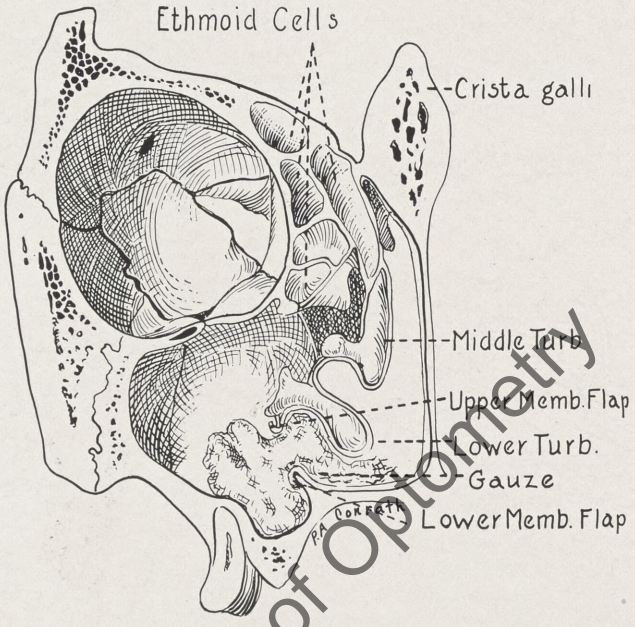

Fig. 161.—Showing the lower turbinate brought down into normal position. Gauze has been packed through the opening in order to turn the upper and lower membranous flaps into the antrum with the idea of possibly making the opening more permanent.

needle used in the exploratory puncture of this cell. While it is in this position its cup-shaped fellow is introduced and locked just as the blades of the obstetrical forceps are introduced separately and locked before they are put to service. A strong bite is then put upon the instrument and by a to-and-fro lateral rocking movement a considerable part of the wall is loosened and removed. The blades should be tempered and the cup sharp as great power is needed in these forceps when the wall is thick.

Digitized by Illinois College of Optometry

If the cup is not sharp it will slip. After the first entry has been satisfactorily made it is usually not difficult to reenter it and enlarge it, by these forceps or any other the surgeon may prefer (Fig. 160). The detached part of the lower turbinate is next pushed down into the lower meatus, while he removes as much of the wall of the middle meatus as he wishes. In this manner it is possible to remove the entire inner wall of the antrum as far forward as the nasal process of the maxilla. There will still remain the ridge on the nasal process, for the reattach-

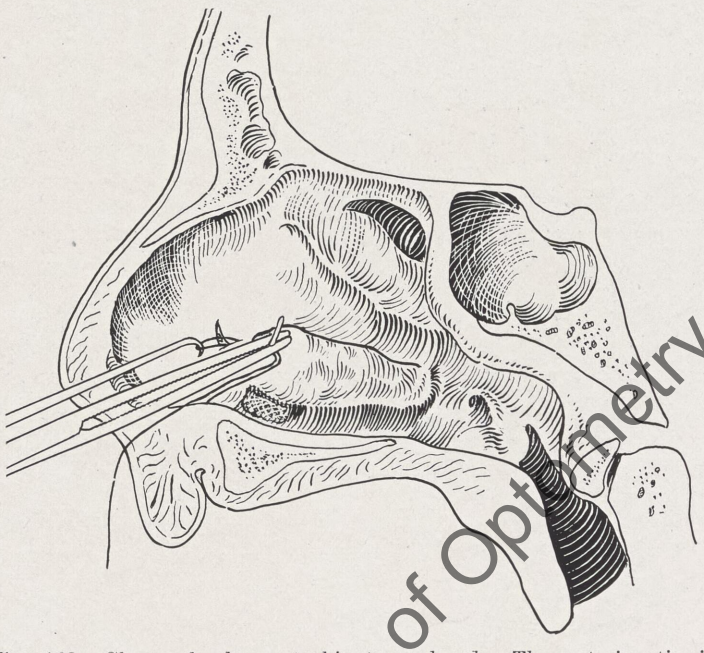

Fig. 162.—Shows the lower turbinate replaced. The anterior tip is being sewed back into its original position. A short curved needle is used for this purpose. A small hook is seen detaching the thread to draw it forward. One stitch suffices.

ment of the lower turbinate, which is now replaced in its original position, carefully apposing the cut surfaces at the anterior end. I have never seen the bone fail to unite, or undergo degeneration. No subsequent hypertrophy has been observed. Some of my cases are of ten years' standing. The replaced turbinate in no wise interferes with the drainage, or with the final good results. It does away absolutely with any subsequent drying. This is a great advantage in cases both of medium and wide nos-

Digitized by Illinois College of Optometry

trils, where some drying is sure to follow any removal of the turbinate. It is *especially* advantageous also in cases in which the *middle turbinate must be* or has been removed to drain a frontal or ethmoidal empyema. In these cases it conserves the heat and moisture functions of the nose, which would be lost were both turbinates removed. In atrophic rhinitis it is especially indicated.

In noses whose caliber is a little too wide or a little too narrow the angle of inclination of the turbinate may be altered in reattaching it, making it less acute for the former and more acute for the latter. This is readily done by tilting the bone upwards by a pack of gauze or cotton put underneath its body after it has been sewed in place, or by pressing the body slightly outwards by a pack between it and the septum. These packs must be continued throughout the healing, the bone afterwards remaining in its new position.

It is my habit to remove the entire inner wall of the antrum—opening it into the middle as well as the lower meatus—replacing the lower turbinate as above described. I believe it is best to remove the wall of the middle as well as of the lower meatus, for the reason that an opening limited to the lower meatus will often close up.

Digitized by Illinois College of Optometry

CHAPTER IX

ORBITAL ABSCESS

A few observations concerning orbital abscess are not out of place in this monograph. The conclusions are limited, however, to my personal experience. In the course of my private practice I have had sixty-one cases of orbital abscess.

The orbit and the nose are intimately associated, being separated by very thin bone which usually may be likened to an eggshell. The floor of the frontal sinus above and internally, the paper plate of the ethmoid, a small part of the sphenoid, and the roof of the maxillary sinus, make up these parts in common. The floor of the frontal sinus is usually limited externally by the supraorbital notch. Sometimes, however, it is much larger, extending to the external angular process of the frontal bone laterally and passing back to the lesser wing of the sphenoid. The apex of the orbit is made up in its upper and internal aspects by the sphenoid bone through which the optic canal passes. External to the canal is the supraorbital fissure, through which the third, fourth, first division of the fifth, and sixth nerves, and ophthalmic vein pass.[4] It should also be borne in mind that at this point the ophthalmic vein forms the most anterior limit of the cavernous sinus. The pneumatization of the spenoid varies. Usually the cell makes up the most posterior part of the orbit internally. It may, however, be very much larger and even surround the optic canal, extending into the greater and lesser wings of the sphenoid. With these intimate relations, it is obvious that surgical complications must necessarily arise, and in my experience rupture of a paranasal cell into the orbit has been the most frequent cause of trouble. Infected penetrating wounds should also be remembered in this connection. The cell most frequently involved as the etiological factor in orbital abscess is the frontal. The next in frequency are the anterior ethmoidal cells. Only once have I seen the post-ethmoidal cells as the etiological factor. I have never seen the maxillary antrum or the sphenoid

Digitized by Illinois College of Optometry

as the source of orbital abscess. It is obvious from the many communicating veins and dehiscences that are found in specimens that any one of these sinuses may be the etiological factor without rupture. Birsch-Hirschfeldt has found and shown bacteria (Fig. 163) passing from the paranasal cells into the orbit, and various authors have emphasized the venous and lymphatic connections as the explanation of orbital abscess complicating paranasal cell disease.

History.—The usual history is that of nasal discharge, which is almost always purulent. The bacteria that usually accompany pus are found. Severe headache, such as may be referred to the cells involved, is usually a precursor. Twice in young children I saw an orbital abscess of frontal sinus origin which was not preceded by headache. It was evidently an extension of the inflammation through the bone and periosteum. The headache usually reaches great intensity and suddenly stops. It stops with the rupture of the cell. The swelling in the orbit takes place quickly, and the picture is almost specific according to the cell that ruptures. In the beginning the swelling may be very great but upon incision it is not found to be purulent. It is more properly expressed as a phlegmon. Three or four or more days later the swelling suppurates and becomes superficial in the eyelid, or sometimes, in the case of the frontal sinus, it may form a fistulous tract above the eyebrow.

Diagnosis.—As stated above the picture varies according to the cell in which the infection originates, and according to the location of the infection in front or back of the transverse meridian of the globe. The rupture of the frontal sinus quickly causes an ecchymosis of the upper lid and conjunctiva, which may possibly be confused with exophthalmos because of the swelling. There is, however, no exophthalmos. The globe is dislocated outward and downward. This may not always be so easily recognized because of the swelling of the upper lid and tear sac. The anterior ethmoidal cells produce a picture that varies according to the position of the cell that ruptures. If the cell is anterior to the transverse meridian of the globe, it produces outward dislocation without exophthalmos. If it is posterior to the meridian, exophthalmos is added to the lateral displacement.

Digitized by Illinois College of Optometry

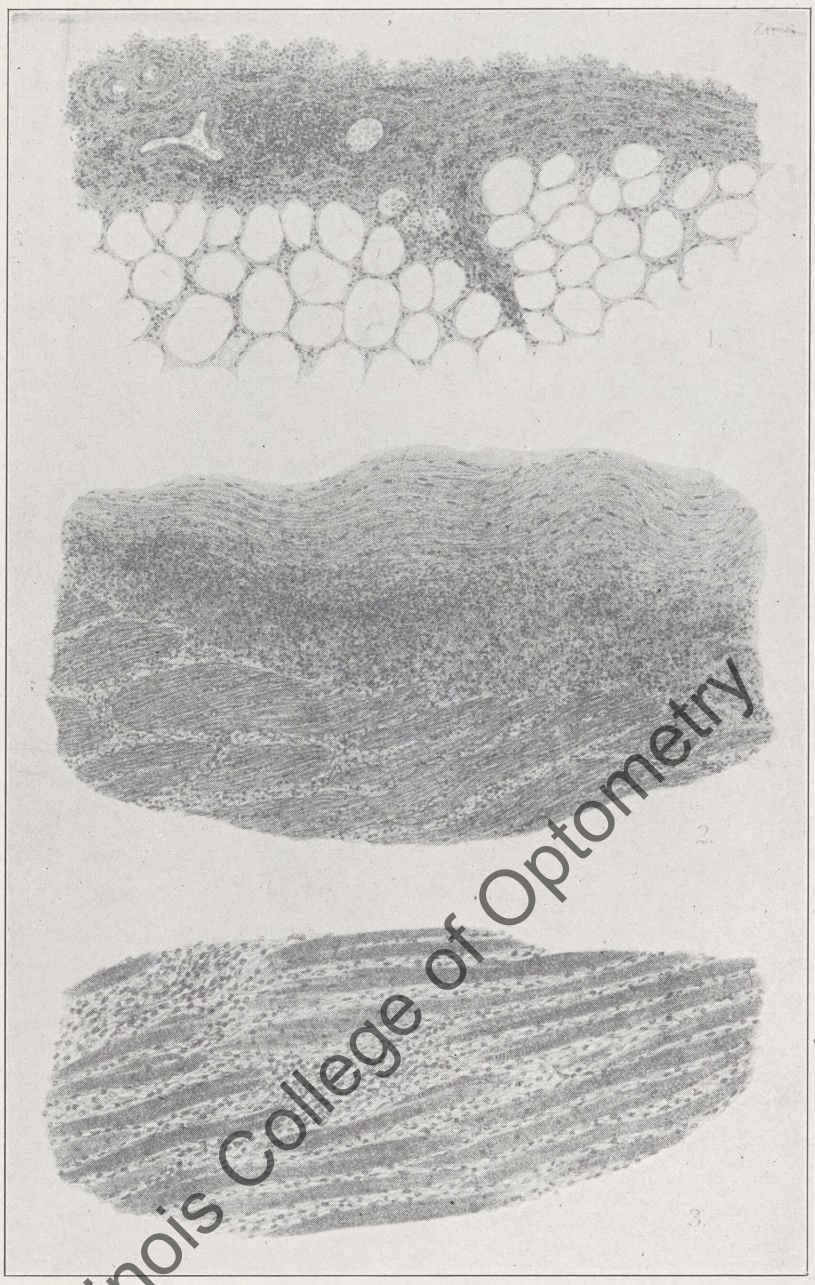

Fig. 168.—Extension of the inflammatory process (*1*) through the periosteum into the orbital fatty tissue; (*2*) to the optic nerve; (*3*) into the internal rectus muscle. (Birsch-Hirschfeldt, Graefe-Saemische Handbuch, 1907.)

Digitized by Illinois College of Optometry

What has been said holds equally true for the posterior ethmoidal cells according to the position of the cell. Being further back, however, the exophthalmos is likely to predominate and the lateral displacement be less, and if the cell be sufficiently far back, the picture is that of exophthalmos alone. This would hold equally true of the sphenoid. Should the maxillary sinus be the source of infection, the dislocation would be upward and it would be accompanied by more or less swelling of the lower lid, according to whether the point of origin was in front or in the back. The maxillary sinus, however, extends far back into the orbit and this point should be remembered because of the reasons enumerated above.

The differential diagnosis lies between orbital abscess and thrombosis of the cavernous sinus, and is obviously very important. Orbital abscess almost uniformly ends in recovery. Thrombosis of the cavernous sinus is fatal. Once, however, I saw a case that was apparently thrombosis of the cavernous sinus that recovered. It was preceded by paranasal cell suppuration, fever, headache, exophthalmos on the right side, bacteriemia (staphylococcus), two days later exophthalmos of the left side, and congestion of the retinal veins. It was a violent illness. I have heard of such cases but there has always been some feature of uncertainty about them.

Orbital abscess is almost always unilateral. Thrombosis of the cavernous sinus is unilateral in the beginning, but in a short time, however, it passes over the transverse sinus in the circle of Willis and becomes bilateral. Both produce exophthalmos. Thrombosis of the cavernous sinus, however, is always without lateral displacement. Orbital abscess of paranasal cell origin is always accompanied by more or less lateral displacement. When the cells near the apex of the orbit are the etiological factor, there is little or no displacement and the differential diagnosis must be made from other phenomena. Abscess of the orbit usually is not accompanied by bacteriemia or by swelling of the central vein of the retina. Thrombosis of the cavernous sinus is accompanied by both.

Authors have described disturbances of vision and retrobulbar neuritis complicating orbital abscess. I have not seen

Digitized by Illinois College of Optometry

these phenomena, which may be explained, however, by the fact that my cases were in patients in private practice who had consulted the physician almost at once after the development. Detailed descriptions of many complicating phenomena are to be found in the recent excellent monograph of Dr. Marcus Hajek, *Pathology and Treatment of the Inflammatory Diseases of the Nasal Accessory Sinuses,* fifth edition, English translation by Joseph D. Heitger and French K. Hansel, 1926, St. Louis, The C. V. Mosby Co. He quotes very largely from Kuhnt whose monograph *Ueber die Entzündlichen Erkrankungen der Stirnhölen und Ihre Folgezustände* was published in 1895, also from Ziem whose work was even earlier. It leaves one in doubt as to how much of the chapter is Hajek's personal observation. Dr. Hajek's monograph deals with the inflammatory diseases of the paranasal cells, almost exclusively with the suppurative lesions. He has always been in doubt about the part that nonsuppurative lesions play. His point of view is one of skepticism regarding the frequent etiological part played by paranasal cell disease in ophthalmological involvements. He demands that the paranasal cells be suppurating or involved with mucocele before they are considered as causative factors in eye lesions. Long neglected cases undoubtedly furnish many of the observations of Kuhnt and Ziem, and possibly some of the cases were not long neglected. In this connection it must be recalled that the practice of rhinology in those years did not have its present diagnostic acumen or its present therapeutic efficiency.

Treatment.—Obviously the treatment in the beginning must be directed to the nose. Shrinking of the mucous membrane will sometimes open the cell, permitting an outlet into the nose. Rarely this may be sufficient, as was true in the two children to whom I referred above as cases of probable extension of inflammation through the bone. In these cases shrinking of the nasal tissues was followed by recovery from the orbital abscess without further treatment. In the other cases the phlegmon or abscess had to be cut into. The quicker the incision is made the better. In some of my cases external incision was tried but proved to be unsatisfactory. All cases were drained into the nose and with the exception of one, recovery resulted in from

Digitized by Illinois College of Optometry

one to two or three weeks. In the case in which the result was not known the man passed out of my observation about three days after the drainage was established and was never heard from. I feel very definitely that drainage into the nose is by far the most satisfactory method. This method drains the abscess by the route of the infection. In all of these cases the middle turbinate was removed and the capsule of the ethmoid or the floor of the frontal sinus perforated into the orbit by means of a small angular knife shown on page 263. As emphasized in other parts of this monograph this small knife possesses great strength and cuts only downward and forward. I believe that these points are advantageous here. Another advantageous feature of the use of the knife is the rapidity with which it may be used. The operation may be done under cocaine, twilight sleep, or under general anesthesia.

I should like to mention one of my cases that did not result primarily from a ruptured cell. It was a perforating wound of the orbit which became infected.

J. B., laborer, age 50 years, referred to me in 1899 by Dr. A. E. Ewing. Three years prior, in the course of some work that required blasting, his orbit was penetrated by a sliver of limestone (at the outer canthus), and the wound became infected. It had a free outlet for drainage and he was troubled very little by it. Rapidly, however, there formed a swelling which pushed his eye downward, and finally outward. At the time I saw him he had a profuse discharge of pus from the middle meatus of that side, with many polyps present. A solution of methylene blue was introduced into the fistula at the outer canthus, and it was seen to pour over the polyps from the middle meatus of that side of the nose. The polyps were removed later from the middle meatus and the frontal sinus perforated into the orbit, making a communication about three-fourths of an inch in diameter. The case went along for four or five weeks, when finally the fistula at the outer canthus closed and remained closed. The swelling which dislocated the globe subsided to about one-third or one-fourth of its orginal volume. There never was any disturbance of vision. The purulent discharge from his nose ceased in about three months. The polyps

Digitized by Illinois College of Optometry

did not return. I continued to observe the patient, however, at irregular intervals for five years.

This case is interesting inasmuch as the nasal picture is identical with those primarily of nasal origin. The left side of his nose was normal, but the right side, having been penetrated by pus from the orbit, behaved in all particulars as though there were primarily a sinus infection on that side. It is also interesting to note that a good result may be obtained in cases of long standing where the drainage into the nose is satisfactory.

Digitized by Illinois College of Optometry

CHAPTER X

CASE HISTORIES

Case histories are submitted with some effort to conform to the pathological lesion. It has however seemed to me more interesting to keep in mind the predominating feature. This will explain why the categories overlap in many places, also the seeming neglect to separate nasal ganglion cases from the sphenoidal cases. This may appear more logical when it is recalled that the lower half headache is the most striking manifestation of both lesions as has been made clear in the body of the text. I have deliberately recorded many features which at first thought may appear so rare or infrequent as to deny the justice of their report. When they have been the only cases I have stated this fact. In recording unusual cases I am justified by the precedent of the most famous neurologists of recent times; to wit, Dr. S. Weir Mitchell, Sir Wm. R. Gowers, and Dr. C. W. Suckling, and others who have recorded unusual cases, no explanation for which could be given at the time. They justified the record of facts by the hope that the future might discover their causes.

In the following case reports all negative and insignificant findings, such as Wassermann and urine reports, blood pressure, blood counts, x-ray plates, etc., have been omitted.

VACUUM FRONTAL HEADACHES

Case 1.—Miss A. B., 28 years old, referred to me by Dr. A. E. Ewing, Oct. 20, 1898, for frontal headache with asthenopia; examination showed a large tuberculum septi crowding the middle turbinate of each side tight to the lateral wall. Both turbinates were removed in November, 1898. Examination by Dr. Wright showed normal turbinates. I append Dr. Ewing's report. This patient shows age by change in the skin with almost no change of feature. She has never had any recurrence (January, 1926).

Digitized by Illinois College of Optometry

"Patient received Oct. 23, 1897. In this case I (Ewing) was for a long time deceived, the tenderness not being sufficiently marked to be regarded by me as decisive. When the patient first came to me there was marginal blepharitis complicated with conjunctivitis, also hypermetropia with astigmatism. The eyes had been inflamed from time to time for several years, and at times there was a good deal of headache. With correction of the refraction and care of the lids, the inflammation in the main disappeared, and the headaches were greatly lessened, but there was always inability to use the eyes by artificial light. The relapses of conjunctivitis were also frequent. Afterwards the headaches became more frequent, and were made worse by any use of the eyes in near work. As the patient was a teacher, some use of the eyes was imperative. There was some weakness of the interni which I corrected with prisms, to be worn in near work in addition to the spectacles which corrected the refractive error. For a time these served fairly well, with periods every two or three weeks during which the eyes could not be used even with this aid. The headaches gradually became more frequent, and were finally almost constant.

"Eventually, when I had almost concluded that my patient was a confirmed neurotic, I detected during a slight exacerbation of the conjunctivitis a positive tenderness in one orbit. A rhinological examination by Dr. Sluder revealed closure of the frontal sinus. Under appropriate treatment for this condition the headaches and the conjunctivitis have entirely disappeared, the prisms have been discarded, and the eyes are used freely day and night."

Case 2.—L. M., aged 15, consulted me September 22, 1902. For 5 years he had had a great deal of trouble from headache and his eyes (asthenopia), which interfered with his education. He had been sent to Texas to live in the open air on a ranch, thinking that would stop the headache and relieve his eyes so that they might come into service.

All effort to relieve him failed, and he was brought to me for examination.

It was found that the middle meatus of each side was closed by the middle turbinates being pushed into the lateral wall by the tubercle of the septum. Ewing's sign was very

Digitized by Illinois College of Optometry

clearly marked. The case seemed perfectly clear as a closure of the frontal sinus without secretion.

December 29, 1902, the left middle turbinate was removed. January 19, 1903, the right middle turbinate was removed. The wound healed uneventfully, the headache stopped, and his eyes went into service, which permitted the complete education of the young man, according to the standards of the family. He went through college and became a celebrated athlete. For some time he has been in business in St. Louis, and from time to time I see him. He remains free of headache. His eyes are as serviceable as anyone's. He shows his age more by the alteration in the skin than in change of feature. The bony configuration of his skull changes very little (1927).

The turbinates were normal (Dr. Wright).

This case is a sharp contrast to Case 3, where the uncinate process and the bulla became approximated after a short time, necessitating the removal of the floor of the frontal sinus with a burr.

Case 3.—M. E., 40 years old, consulted me Dec. 20, 1903, because of symptoms almost the same as Case 2.

Removal of the middle turbinate gave relief for nine years when the inlet to the frontal sinus was obliterated by enlargement of the bulla to approximate the uncinate process as high up as the cribriform plate. On Oct. 10, 1912, I removed the uncinate and floor of the frontal sinus, making a large opening which so far has remained open (1927).

Clinically, the case is an active hyperplastic anterior ethmoiditis. She shows age markedly by change of bony feature.

It is not possible at present to connect the external face which changes in features as age increases, with the activity of the hyperplastic process within the nose. I have, however, observed it often.

Case 4.—Mrs. J. B. C., 33 years old, referred by Dr. M. H. Post, October 26, 1910, for frontal sinus vacuum headache of 15 years' standing, with asthenopia, high grade. March 16, 1911, I removed by high (cribriform) cut, the left middle turbinate. It showed (Dr. Wright's examination) a hyperplastic (bone and soft parts) process. The right side was less troublesome and

Digitized by Illinois College of Optometry

not operated upon. She got well and remained so until sent to me again by Dr. J. A. Flury July 8, 1915, with a well-marked hyperplastic sphenoiditis, nonsuppurative, more marked left side, accompanied by moderate maxillary and Vidian neuralgia with a haziness of the retina and a blurring of the disc of both eyes with vision left 6/9, right 6/6 metric. She was given a 1½ per cent alkaline saline solution to pour into the nose three times a day and a phenol spray. Improvement began in two weeks. September 13, 1915, she reported herself to be "well." Dr. Flury reported the fundi V. right and left normal.

I have three similar cases beginning 15, 17, and 20 years ago, respectively, as frontal vacuum headaches.

The middle turbinate bones showed hyperplasia of bone and soft parts (Dr. Wright). They remained well after operation until the past 3 years, since which time they have developed a hyperplastic post-ethmo-sphenoiditis, one with polyps above the middle turbinate line. All have lower half headache in great degree and very often; but no fundus changes.

In one case a major epilepsy ceased after a post-ethmoidal-sphenoidal operation. He has been well for 17 years (1918).

Case 5.—S. R., aged 23 years, consulted me in 1898 because of intractable low grade frontal headache made worse by use of the eyes. She was referred to me by Dr. John Green. Effort to relieve the eye condition was unsuccessful. Nasal examination showed the middle turbinate crowded to the lateral wall by the tubercle of the septum. She had been passed as a neurotic by the neurologists. Very little hope was held out for any benefit except possibly by the lapse of time. Removal of the middle turbinate relieved the frontal headache, stopped the general nervous condition and restored her eyes to full usage. She remained free of pain for six years, at which time she suffered a frontal sinus infection with pus. She had a low grade headache with this, which lasted two weeks and subsided practically without treatment. Twice she has had suppurative infections of the frontal and the anterior ethmoidal sinuses. The case has been of great interest in observation showing the gradual increase of volume of the bulla of the ethmoid, a thickening of the uncinate process of the ethmoid and a swelling of the membrane. Now

Digitized by Illinois College of Optometry

she has a considerably swollen membrane, the inlet to the frontal sinus is considerably narrowed and she suffers more or less discomfort with each coryza. Of greater interest, however, is the observation that twelve years ago began the appearance of swelling with polyps above the line of origin for the middle turbinate. Since that time, of greatest interest, is the posterior pain which has developed since the inflammatory trouble has been above the middle turbinate and backward. At present she has a very well-marked hyperplastic post-ethmoidal sphenoiditis which with each coryza causes the formation of polyps in considerable number and volume. In the interval between the coryza the polyps disappear, all except one which is in the anterior ethmoid and which becomes very much smaller. Much of the time she is free of all pain. Any little inflammatory trouble in her nose which might otherwise not be recognized is registered as headache either frontal or occipital. This case is to me very interesting showing the gradual extension of the process from a hyperplastic anterior ethmoiditis of low grade to the posterior district where the typical lower half headache has been repeatedly produced. In this case a cut which removed the middle turbinate was placed up or nearly to the cribriform plate, the cut which I have repeatedly spoken of as a cribriform turbinectomy. The nose still shows an inlet to the frontal sinus of ⅛ inch. In the beginning the inlet was ⅜ inch. Doctor Wright's report of the middle turbinate examination was that it showed a moderate grade of ostitis or periostitis.

Case 6.—Mrs. N. H., aged 45 years, consulted me April 1, 1900, because of headache and great discomfort in the use of her eyes. The middle meatus of each side was found to be closed. The anterior half of the middle turbinate was for that reason removed. This gave considerable comfort in the daily use of the eyes; but a recurrent headache of great severity continued at intervals. This arose from hyperplastic post-ethmoiditis.

The patient was not seen again for a number of years, when she stated that she thought that she was getting better. Examination in 1917 revealed the fact that the post-ethmoiditis had involuted to such an extent as to appear gone altogether. It appeared normal. She made the statement that she was now

Digitized by Illinois College of Optometry

practically free of the intense headaches that had recurred at intervals of two or three weeks.

To my mind, this case is a combination of the vacuum frontal headache, which was relieved, and considerable benefit gained, by opening the frontal inlet, and of a hyperplastic post-ethmoiditis which, as life went on, that is, passed the menopause, slowly involuted.

At the present time she is free of such headaches.

This patient had been examined by all kinds of intelligent medical men, and all kinds of treatment had been instituted and pursued. The case was classed by neurologists as a vulgar megrim. To my mind, she was relieved in later life on account of a rarefying ostitis, in the post-ethmoidal-sphenoidal district.

ANTERIOR ETHMOIDAL NEURALGIA

Case 7.—Mrs. N., sister to patient described as Case 9, whom I had seen many times with acute coryzas, came February, 1909, with what appeared to be a coryza of ordinary severity; she complained, however, of pain as in a typical case of nasal ganglion neuralgia. One application of cocaine afforded complete relief, and there was no recurrence of pain. The coryza was otherwise common-place and uneventful.

Since that time I have seen Mrs. N. many times for various troubles. One, an enlargement of the thyroid, which seemed to be secondary to a lingual tonsillitis. The lingual tonsil was treated, resulting in a lessening of the volume of the thyroid and the cessation of the nervousness and weakness of the hyperthyroidism which was at the time quite pronounced. She had no more ganglion neuralgia until the winter of 1916 and 1917. Then in the wake of what appeared to be an ordinary coryza she again complained of pain described briefly as a "lower half headache," severe, accompanied by violent sneezing and a sense of very strong mustard in the nose, lacrimation and marked asthenopia. The entire picture was marked; but knowing that she had passed through such an attack of a much milder nature on an occasion before, I felt that she would probably survive this attack without injection of the ganglion, which I therefore postponed.

Digitized by Illinois College of Optometry

The course of the condition ran a series of ups and downs, more or less lasting throughout the autumn and winter. The symptoms subsided in the middle of spring.

Locally, her nose showed a perfectly clear post-ethmoidal sphenoiditis of what I suppose might be termed the catarrhal type; that is, there was no suppuration, no swelling of the membrane; the appearance was simply one of redness with serous secretion; throughout the attack cocaine to the ganglion stopped the pain and relieved all symptoms for a number of days at a time.

In this patient of course the position of the nasal ganglion remained unchanged throughout these years. From the time of the first pain manifestation until this now reported, she has passed through many coryzas of ordinary severity, none of which, however, excited pain, except in one instance when she consulted me February 29, 1920, because of acute coryza with headache and discomfort in her eyes. Cocainization of the anterior ethmoidal nerve relieved the discomfort in her eyes, but had no effect on the headache.

Such a case seems to me to argue that the organism that produces the coryza must vary from time to time, and that there is a special organism or, possibly, more than one, that has a predilection for the nerve tissues; and that there are others that pass through their course with just as much appearance of inflammation as the other attacks, but which cause no symptoms on the part of the nerve tissues.

Case 8.—S. M. J., aged 25 years, was sent to me by Doctor Vilray Blair on March 1, 1915. She suffered very severe headache. Doctor Blair in the effort to alleviate the pain had injected with alcohol the second and third divisions of the fifth nerve of that side, but although a perfect peripheral anesthesia was secured, the pain continued unchanged. Nasal examination showed an ethmoiditis anterior and posterior; operation for which was successful, relieving the pain. This case is of interest showing how total anesthesia of the peripheral nerve distribution may not carry with it relief from the pain produced by suppurative sinuses.

Digitized by Illinois College of Optometry

NASAL GANGLION SYNDROMES

LOWER HALF HEADACHE, MAXILLARY AND VIDIAN NEURALGIA, TIC DOULOUREUX, GLOSSODYNIA, HERPES OF THE TONGUE, PARAGEUSIA, OTALGIA, ASTHMA, MOTOR PHENOMENA, SYMPATHETIC PHENOMENA, NAUSEA, VOMITING, DIARRHEA, VERTIGO, ETC.

Nasal Ganglion Neuralgia

Case 9.—Mr. S., 45 years old, consulted me November 23, 1903. For ten years he had suffered from headache which incapacitated him for business two or three days of almost every week. Nothing in his general health or life was at fault. He defined the distribution of pain as beginning at the root of the nose on the right side, taking in the upper jaw, and extending backward to become emphasized at the tip of the mastoid and for a distance of 5 cm. posterior to it. This point was always tender to pressure. The attacks were not always of equal severity. During a milder attack he could continue his business. In severe attacks the pain extended to the neck, shoulder, and shoulder blade of the same side, and was so intense as to compel him to go to bed. They were accompanied by vomiting. These severer attacks lasted from twelve to twenty-four hours. Examination of the nose showed a dusky red swollen area in the right olfactory fissure about 1.5 cm. in diameter, roughly circular, beginning on the anterior wall of the sphenoidal cells and extending forward (the sphenopalatine foramen district).

Applications of a 2 per cent silver nitrate solution were made to the affected area two or three days a week for about three months. It finally became normal in appearance. With the improving appearance of this area went hand in hand a lessening of the frequency and severity of the attacks of pain, until they ceased. Since that time he has enjoyed freedom from painful attacks except at the time of coryza. Coryzas of medium severity are accompanied by a moderately severe attack of pain, as described before. He had one more severe coryza which was accompanied by great pain.

After I had learned to associate these neuralgic manifestations with the nasal ganglion, and to apply the anesthetic in its immediate neighborhood (October, 1907), I was always able

Digitized by Illinois College of Optometry

to stop the pain during coryzas. With this patient anesthetizing the ganglion aborts the attack. During three years he had one slight attack from coryza.

In February, 1925, he had a coryza with well-marked sympathetic syndrome; sneezing, profuse watery discharge, lacrimation, slight photophobia. It lasted two weeks.

At the present time he is well.

Nasal Ganglion Neuralgia

Case 10.—Miss S., 27 years old, consulted me June 13, 1906. For many years "off and on," she had suffered from pain in the head, which she described as paroxysmal, beginning at the root of the nose, involving the upper jaw and teeth (occasionally also the lower jaw and teeth), extending backward to the tip of the mastoid, and becoming most intense about 5 cm. posterior to this point.

These paroxysms recurred sometimes two or three times a week; and when at her best, at intervals of two or three months. Examination of the nose was negative in every particular. She made the observation, however, during an attack, that the cocaine which had been sprayed into her nose, a four per cent solution, had relieved her of the pain.

In the absence of a definite diagnosis, but continuing the spraying of the nose with cocaine, it was found that each application appreciably mitigated the pain. Under this treatment, in apparently much improved condition, she passed from observation. About three months later she returned for treatment of a severe coryza, which in ten days localized itself in a suppurating inflammation of the post-ethmoidal and sphenoidal sinuses of both sides. Almost simultaneously the old pain reappeared, on the left side, involving the root of the nose, the cheek, the mastoid tip, and a little behind it, the neck, shoulder blade, shoulder, and arm—all in great severity.

Remembering the position of the nasal ganglion, in close proximity to these sinuses, and the widespread distribution of its branches and connections, I felt that this distribution of pain was possibly due to the inflammation or its products extending to or acting upon the ganglion; and, if this was true, that

Digitized by Illinois College of Optometry

cocaine applied (soaked) over the sphenopalatine foramen might probably prove effective in at least mitigating the pain.

The experiment was tried, and succeeded even beyond expectation. Since then I have applied the cocaine for her at the same site in severe recurrent attacks, probably twenty times; always relieving the pain and usually aborting the attack.

I have also done some experimenting in these cases, but particularly in this case. During an attack an application of a single drop of dilute solution 4 per cent cocaine, through the region overlying the ganglion, was followed by only the faintest relief. This dilute solution was then replaced by a drop of a 10 per cent cocaine solution, with more relief. A drop of 20 per cent solution was then applied, with further lessening of the pain. A drop of a more saturated solution (about 67 per cent) was then applied, when the relief would usually become complete. Applications to *other areas gave negative results.* In very severe attacks the pain would stop except at the point 5 cm. posterior to the tip of the mastoid, where, although greatly mitigated, it never quite disappeared; a very slight pain always remained here. The applications were allowed to remain in position twenty minutes.

This patient suffered greatly from repeated attacks until December 1, 1908, when I began injections of alcohol, making the attempt to put the alcohol in direct contact with the ganglion. A straight needle directed upward and outward under the posterior fourth of the middle turbinate will reach the sphenopalatine fossa just where the ganglion lies. The needle must, however, be passed obliquely through the lateral wall of the nose, which in this case was so hard as to make the procedure impossible. I thereupon drilled through the bone, thus removing the obstacle to the passage of the needle into the pterygopalatine fossa and opening an easy route for subsequent injections. The injection of the alcohol aggravated the characteristic pain already described, but the exacerbation was transitory and was followed by relief.

After a course of ten injections the relief seemed complete; but, after somewhat more than three weeks of freedom from pain, the patient contracted another severe coryza, with suppurative inflammation of the post-ethmoidal and sphenoidal

Digitized by Illinois College of Optometry

cells of both sides, rekindling the old pain now for the first time also on the right side, although with less severity than on the left side. One application of saturated cocaine solution on the right side, posterior to and slightly above the posterior tip of the middle turbinate stopped the pain and it did not recur. On the left side relief was more tardy.

Miss S. recently had another "explosion," which was relieved by one drop of saturated cocaine solution to the ganglion with the exception of a rather severe pain, which persisted in the shoulder blade of that side. On the next day the cocaine application was repeated, with complete relief of the pain.

At present she is free of pain except at times of a coryza. Then it develops in her teeth and between her shoulder blades where it feels like a "ball of fire."

Although the injection of the ganglion and the opening of the post-ethmoidal-sphenoid is technically satisfactory for this woman, she continues to suffer very greatly from severe pain that extends to the coccyx and sometimes causes lumbago. It is always stopped by an application of a small amount of 20 per cent cocaine. She is, however, an example of how intense, and unfortunate and difficult some of these cases may be.

Nasal Ganglion Neuralgia

Case 11.—Mr. B., 35 years old, came to me September 24, 1907, with a high grade deflection of the septum, which I resected. The operation was in every way uneventful and satisfactory. May 14, 1908, he returned with an acute suppurative inflammation of the post-ethmoidal and sphenoidal cells on both sides, accompanied by a headache referred to the parietal eminence and occiput on both sides, which lasted seven days. Three days later pain developed, which he described as beginning in the root of the nose, taking in the maxilla, extending backward into the occiput, and downward into the neck and shoulder blade. It improved under applications of 0.4 per cent formaldehyde solution over the sphenopalatine foramen. Patient was completely well June 23, 1908, and remained so with the exception of some occasional disturbances from coryzas.

Digitized by Illinois College of Optometry

Sphenoidal Empyema

Case 12.—Mrs. P., 55 years old. Diagnosis, sphenoidal empyema. Pain in occiput, left, 6 months. Relieved by operation. Referred by Dr. A. E. Ewing. Dr. Wright's report: Sphenoidal tissue—bone shows some hyperplasia and there are marked inflammatory products in the soft parts. Middle turbinate shows marked inflammation of mucous membrane in its deeper layers and considerable hyperplasia of the periosteum along the bone areas; the bone itself is perhaps slightly thickened and the area of its distribution is considerable. In some places the bone seems to be very much thickened and the veins which it contains are gorged with blood.

Maxillary and Vidian Neuralgia

Case 13.—Mrs. E. C., 30 years old, became my patient February 10, 1907, for acute empyema of right frontal sinus, which recovered as an ordinary severe coryza. It recurred several times with much pain, and in November, 1908, I removed the middle turbinate high up, which gave a large outlet to the sinus and cessation of all symptoms. A low grade hyperplastic process in the anterior ethmoidal and frontal regions existed then, or was started that year, and had extended backward to involve the post-ethmo-sphenoidal region. Severe pain of maxillary and Vidian distribution began to develop, occasionally, in 1911 and 1912, and became more frequent and severe. Occasionally a coryza caused post-ethmo-sphenoidal suppuration. A Hajek post-ethmo-sphenoidal operation was done on the same (right) side in 1913, followed by irregular intermittent treatment with marked relief from pain. Later in 1913, she began to complain of constant slight watery discharge from the left nostril, which proved to be secretion from the membrane in general. The sphenopalatine foramen district, however, began to show changes and treatment—silver, acetic acid, cocaine—was directed to it. The secretion continued and increased. She had an occasional ganglion neuralgia of the left side. On November 15, 1914, I injected the nasal ganglion, left, with phenol-alcohol, and since that time she has been *free* of *discharge* and has not, so far, had a recurrence of pain.

Digitized by Illinois College of Optometry

Lower Half Headache—Vidian Neuralgia

Case 14.—J. S. consulted me Oct. 20, 1914, because of severe pain in the lower half left side of the head, which he had suffered as long as he could remember.

Examination showed a perfectly well-marked inflammatory patch over the left sphenopalatine foramen. I found that cocaine stopped the pain.

It was therefore decided to inject the ganglion, which was done only once. It stopped the pain. It has not returned.

I feel special emphasis should be laid upon the character of the pain. It was a more or less constant pain, but mixed in with it was a perfectly clearly defined tic which came as a stabbing to the lower half of the head, neck and shoulder at intervals not more than a few hours apart. This was particularly marked in the posterior distribution of the pain, the anterior distribution being for the most part free of the tic.

To my mind, this case is particularly interesting as an exposition of tic of the Vidian; i. e., relative to the Vidian nerve taking on the sharp recurrent stabbing attacks that characterize many cases of trigeminal neuralgia.

I have, in all, ten cases in which the posterior pain was of this type, where the posterior disturbance was a tic pure and simple, without the general course of more or less constant pain.

The patient was sent to me by Doctor Sidney I. Schwab.

Paresthesia of Upper Extremity from Injection

Case 15.—Miss B. O., aged 35 years, slender, frail, neurotic woman. Wassermann negative; no organic lesions discoverable. She was my patient for fifteen years, sometimes for acute sore throat, sometimes for nasal obstruction; latterly for neuralgia of the lower half of the head, neck, shoulder, shoulder blade and arm.

Cocainization of the ganglion helped the pain in her head and neck but made a very unpleasant tingling sensation in her arm.

The pathological lesion was a post-ethmoidal sphenoiditis, not especially hyperplastic, but rather high grade, manifested

Digitized by Illinois College of Optometry

by a marked redness, with only a slight degree of swelling and little serous secretion.

The injection of the ganglion was followed by a fair degree of relief from pain. The inflammatory post-nasal condition is better. The tingling in her arm remains.

Effort has been made by Doctor Walter Baumgarten to help the condition by diet free from animal protein.

It did not accomplish the result. Internal medical treatment in general did not relieve the nasal condition.

The case is of interest because of the tingling sensation in the arm. I have repeatedly heard such paresthesias described as "itching" or "burning." This, however, is the only instance in which it was produced by the injection.

Nasal Ganglion Injection Failure

Case 16.—Mrs. G., was seen by me in the Hopkins Hospital on Oct. 15, 1909, with what seemed to be a high grade nasal ganglion neuralgia. She was presented to me by Doctor Harvey Cushing. Prior to my examination, however, Doctor Bordely had operated upon the sphenoidal district. I injected the nasal ganglion or at least attempted to inject it in the acute inflammatory reaction which followed Doctor Bordely's surgery. The result was a failure. Doctor Cushing later removed the semilunar ganglion. In this patient the straight needle as I passed it in, went an unusual distance. My feeling about it now is that the sphenoidal face was unusually thin and I crossed the sphenomaxillary fossa to inject into the cavity of the sphenoid. Whether the injection of the sphenomaxillary fossa at that time would have been helpful or not of course I cannot say. It is a failure, the anatomical explanation of which is given in the preceding text.

Death from Meningitis

Case 17.—Mrs. Buc., 40 years old, consulted the Nose and Throat Clinic, O'Fallon Dispensary, Washington University Medical Department, for severe headache, worse on left side, extending to neck and shoulders. All examination was negative. After considerable effort I diagnosed a post-ethmoidal-sphenoidal inflammation, right and left, and later, February-July,

Digitized by Illinois College of Optometry

1910, opened both sides. The reaction was severe. After some months she was better, and finally became comfortable. A coryza without suppuration later reestablished the pain, which on the right side was stopped by intrasphenoidal applications of 10 per cent salicylate of methyl, and much improved on the left side. Applications of cocaine inside the left sinus quickly produced total anesthesia and analgesia of the areas supplied by all the divisions of the fifth nerve, with a marked sense of stiffness of the lower jaw of that side, which I took to be the effect of the cocaine upon the motor function in the third division. Dr. D. E. Jackson, of the Pharmacological Department, Washington University, agrees with me in this conclusion. The right side ceased to be painful after eighteen months, which was shortly after the applications of methyl salicylate were begun. The left continues to be intermittently painful to a considerable degree, but is markedly improved by methyl salicylate, and remains vastly better than before this treatment was begun. She frequently complains of stiffness of the lower jaw on that side. Only once did this case show a tendency toward edema with polyp formation at the time of acute inflammatory attack, and then only slight.

Intrasphenoidal observation in this case at the time (1914) of the severe ear pain has shown greatly reddened Vidian and maxillary tract. As the pain subsides, the redness of these districts disappears; or as the redness disappears, the pain subsides. Cocainization within the sphenoid is uniformly satisfactory—it stops the pain. Application of strong cocaine dropped within the sphenoid paralyzes the entire fifth nerve distribution for sensation, with a stiffness of the lower jaw.

She continued to improve under treatment, seemingly doing well until Dec. 15, 1915, when her husband telephoned that she had had a very violent headache that day; and that evening began to vomit without any preceding nausea. I immediately suspected an intracranial disturbance, and sent a consultant to examine the patient.

My assistant reported that the internal medical man had determined that it was gallstone; and that the case seemed to be one of gallstone, and that she seemed very much better.

Most unfortunately, an accident in my affairs at that time

Digitized by Illinois College of Optometry

delayed me four days in my effort to keep in touch with the progress of the case. At the end of this time, I was informed that she had developed a meningitis and had been sent to the infectious hospital.

Inquiry was made there concerning the case. It was reported that she had died; but that no autopsy had been performed.

Examination of the spinal fluid had been negative.

The case seemed unquestionably to be one of extension of infection to the cranial cavity from the sphenoidal sinus. It was most unfortunate that I could get no autopsy report.

In my experience I have had eight cases to follow more or less their course, that have ended by some mysterious meningeal process. One proved to be a glioma of the middle fossa of the skull. It developed about a year after the sphenoidal operation which had saved both eyes; a high grade optic neuritis.

Trigeminal Hypalgesia, Paresthesia, Hypesthesia, Pupil Dilated—Sphenoiditis

Case 18.—Miss H. M., 35 years old, referred by Dr. F. R. Fry and Dr. A. E. Ewing, March 10, 1914. She had suffered violent headaches as long as she could remember, recurrent at irregular intervals (type of vulgar megrim) but getting worse. My diagnosis: Hyperplastic sphenoiditis (nonsuppurative right and left). Dr. Fry's report: She has a parasthesia hypesthesia and hypalgesia in distribution of fifth nerves which I feel certain is of organic genesis. The different kinds of impairment are coextensive at present. The left pupil is a little larger. They react fairly well. Dr. Ewing's report of eye conditions March 5, 1914, vision 20/15 right and left. Slight blurring of disc margins pathological (?). Slight paresis of right side of face. Advised to consult Dr. Fry. Post-ethmoidal-sphenoidal operation of left side June 5, 1914; of right side February 11, 1915. On June 1, 1915, Dr. Fry reports a return to normal of above stated changes and Dr. Ewing reports disc normal, possibly a slight blurring still of left disc margin. A note dated July 6, 1914, at the time of a coryza shows the left disc to have been swollen 2 diopters. This lasted three weeks.

Dr. Wright's report: Sphenoidal wall shows a marked

Digitized by Illinois College of Optometry

chronic inflammation with involvement of periosteum; and bone to a moderate extent. Middle turbinate: There is a chronic fibrous hyperplasia of the soft parts involving the walls of the arterioles. The bone shows no marked changes. June 1, 1915, free of pain, except slight occasional occipital headache. She has at times a low grade tingling sensation of right side of face.

Sphenoiditis and Tic Douloureux

Case 19.—Miss J. S. consulted me Feb. 10, 1914, complaining of a severe tic of the second and third divisions of the right side. Examination revealed a high grade suppurative sphenoiditis. The tic had lasted several years and the patient had had peripheral injections with no result. The sphenoid was opened on Feb. 15, 1914, and the patient remained free of tic for three years. In a letter recently she announced that the tic returned and all efforts to relieve it failed, until finally a semilunar ganglionectomy was done. The case is of interest to me, showing a tic which seemed to be clearly of sphenoidal inflammatory origin. It is also interesting to note the duration of the relief that had not been obtained by any other means. It is also interesting to note that such cases once affected may go on until a ganglionectomy is required.

Tic Douloureux

Case 20.—Miss J. S., 50 years old, was referred to me Jan. 10, 1913, by Dr. T. H. Halstead for a right tic douloureux of the maxillary and mandibular nerves. Peripheral injections had not been satisfactory. She had a right suppurating sphenoid. The post-ethmoidal-sphenoidal operation was done Jan. 15, 1913. The result was relief from the tic until 1917 when it had recurred and a semilunar ganglionectomy was done. The symptoms of this patient seemed to me to originate from the sphenoid. It shows the progress of the "tic" when once well started.

Case 21.—W. B., 45 years old, consulted me January 20, 1914, because of neuralgia, described as lower half headache.

Examination of the nose revealed an acute post-ethmoidal sphenoiditis, more marked at the site of the sphenopalatine foramen. Cocainization of the ganglion stopped the pain.

Digitized by Illinois College of Optometry

He was delighted, as it aborted the attack which usually lasted ten days.

He had suffered such headache at intervals all his life. It occurred probably at the recurrence of coryzas. He had a low grade hyperplastic post-ethmoidal sphenoiditis. With each of these attacks he developed a severe tic douloureux of the maxillary and Vidian nerves, establishing a *lower half tic.* Cocainization of the ganglion relieved the tic. It recurred after the cocaine wore away, but usually very little.

On another occasion, Dr. B., came to me because of a tic in the mandibular nerve.

As far as the ordinary nose is concerned, the mandibular nerve is not related to the sphenoidal sinus, or the nasal ganglion. Cocainization of the nasal ganglion here did not in any way influence the third division. The experiment was tried, and failure was absolute. The next day he discovered a tooth was responsible for the tic.

It is interesting to note that in this case the patient developed a tic always, whether he developed the constant headache or not. Apparently different lesions of the peripheral distribution of the trigeminus produced the tic.

Nasal Ganglion Phenomenon

Case 22.—Mrs. F. M., 32 years of age, consulted me February 17, 1922, because of nasal ganglion syndrome with nausea from a bad molar tooth which she thought was suppurating. No pus was seen. Cocainization of the ganglion stopped the nausea and the bad taste. I saw this patient only three times.

Nasal Ganglion Phenomenon

Case 23.—Mrs. C. A., 40 years of age, consulted me January, 1920, because of itching of the right eye. This was promptly relieved by an application of cocaine to the nasal ganglion. Cocainization of the internal nasal nerve failed. No return of symptoms.

Hyperplastic Sphenoidal Headache

Case 24.—Mrs. F. M., 34 years old, became my patient January 16, 1918. She had a hyperplastic sphenoiditis and severe headache, right occipital, as a result of which there was a thin

Digitized by Illinois College of Optometry

secretion of seropus from the right sphenoid. February 11, 1918, I did a post-ethmoidal-sphenoidal operation, right side. February 1, 1919, an old goiter became active with hyperthyroidism. October 4, 1919, the thyroid had improved by treatment of the lingual tonsil and ceased to be a clinical factor. February 10, 1920, whole pituitary gland was administered, 5 grain, three times a day. This relieved considerable nervousness but in no way affected the headache.

Lower Half Headache of Nasal Ganglion Origin

Case 25.—Mrs. P. G. P., 45 years of age, consulted me May 23, 1925. The case is of no particular interest except that a well-defined lower half headache of nasal ganglion origin was relieved by the extraction of a bad molar tooth from the upper jaw. I do not know how long the pain was relieved. In other cases I have seen, it has been transitory.

Nodular Headache

Case 26.—Miss L., 40 years of age, consulted me November 25, 1919, because of headache of nasal ganglion origin. She also had knots over the occiput and at the insertion of the sterno-cleidomastoid that were about the size of peas. She stated that the nodules grew larger as the pain increased. Since her first visit I have seen her a number of times with knots on various parts of her body and sometimes on various parts over the skull. Sometimes I succeeded in diminishing the size of the nodules by cocainizing the nasal ganglion.

Hyperplastic Sphenoiditis and Pregnancy

Case 27.—Mrs. S., aged 28 years, consulted me Jan. 3, 1915, because of lower half headache. Examination revealed a low grade hyperplastic post-ethmoidal sphenoiditis right and left. Inquiry revealed further that she was three months pregnant. The statement was made that the headache had begun only with the pregnancy. As an unpregnant woman she did not suffer headache. Subsequent pregnancies, two in number, revealed that with each pregnancy the process became active, sufficient to cause pain and subsided again later when the uterus was

Digitized by Illinois College of Optometry

empty. The case is of interest in showing the increased activity of the parts during pregnancy. It appears to be a low grade case. She suffers little or none except when aroused under those conditions.

Nasal Ganglion Phenomena

Case 28.—Mrs. H. B., aged 45 years, became my patient November 24, 1920. She had recurrent middle ear abscess and posterior hypertrophy of the lower turbinate. January 12, and March 15, 1921, I did a posterior cautery destruction of each turbinate. The result was perfect. She has never been an ear patient since. February 1, 1922, she had an acute coryza with a post-ethmoidal suppuration, right and left, which annoyed her considerably, without ever being very bad. February 26, 1922, she had a severe lower half headache with severe stomachache which was stopped by cocaine applied to the ganglia. There is nothing unusual to report in the consideration of this case otherwise. She is a normal woman as far as can be determined.

Sphenoidal Headache with Probably a Migraine Added

Case 29.—Miss A. M., 38 years old, consulted me March 20, 1911, because of intermittent headache from which she had suffered for years. At this time it had been coming much oftener and had been rapidly growing more severe, then requiring 2½ grains of morphine sulphate subcutaneously administered by her physician to control the pain. She never took morphine herself. The pain was worse in the left temple; but in the height of the attack it seemed to extend over the entire head. And very rarely it came on the right side alone or would be much worse on that side. A post-ethmoidal-sphenoidal inflammation was found on the left side, which was operated upon two months later. The reaction was intense. She improved little or none during the next four months under a treatment of simple cleansing of the cavities. At this time (October, 1911), intrasphenoidal applications of 10 per cent methyl salicylate were begun with the idea of soaking the medicament into the environing fifth nerve. Since then the general improvement in her suffering has been very considerable. Much of the time she is free of pain and a large part of the remaining time she suffers only slightly. The

Digitized by Illinois College of Optometry

recurrence of the intensely severe attacks is less frequent and intense. She recognizes two kinds of pain—one that I can stop by filling the sphenoidal sinus with cocaine methyl salicylate or menthol solutions and another distributed over the same area which I have tried in vain to stop by these measures. When this attack begins it progresses despite all efforts to stop it; but it has become less severe and less frequent under this treatment, and the last attack, April 1, 1912, was on the right side only.

Vulgar Migraine

Case 30.—Mrs. M. D. A., 48 years old, consulted me June 11, 1910, because of right-sided recurrent sphenopalatine ganglion neuralgia, or, at least, what seemed to be such. It had lasted twenty-four years. It was stopped by cocainization of the sphenopalatine ganglion and controlled for one year by carbolization of the ganglion, at the end of which time she suffered some kind of an explosion which took in her entire head, upper and lower parts, on both sides, which confined her to her bed for four weeks despite acetphenetidin, aspirin, codeine and morphine. I did not see her during this illness. After this attack, however, she came to see me, but showed no local changes. She continued to suffer very greatly, and frequently from what seemed, from its distribution, a trigeminal neuralgia with pain in her occiput and neck almost altogether on the right side. After a careful explanation of her case to her, describing the local conditions and telling of a possible benefit from intrasphenoidal medication, Dr. Bliss and I advised her to submit to the opening of her sphenoid, despite the fact that no sphenoidal inflammation was exhibited. She accepted the proposal. Twice prior to the Hajek radical post-ethmoidal-sphenoidal operation I injected a drop of 5 per cent solution carbolic acid in 95 per cent ethyl alcohol into the sphenopalatine ganglion, each being allowed to rest five days with the idea of benumbing it and thereby reducing the reactionary shock. The pain of the operation under cocaine and the succeeding depression and pain were, in this case, astoundingly little. Subsequent filling of the sphenoid sinus with 2 per cent aqueous solu-

Digitized by Illinois College of Optometry

tion of sodium salicylate was accompanied by a decided improvement, both in severity and frequency of the pain on the right side.

Supraorbital and Nasal Ganglion Neuralgia

Case 31.—Mrs. L., 42 years old, came to me August 3, 1908, complaining of pain behind the right eye and in the upper jaw (all sinuses normal). She described the pain as constant. She stated that she had for thirty years been subject to violent headaches, ending in vomiting. This case was diagnosed as migraine by Dr. F. R. Fry, who sent her to me. A little later I saw her during one of her "bad spells." The pain was very severe. It took in the entire half of the right side of the head and ran down into the neck, shoulder blade, axilla, arm, forearm, and hand. A drop of saturated solution of cocaine was then soaked into the site of the sphenopalatine foramen with marked relief except of the pain in the upper half of the head (ophthalmic nerve). A second application was then made with complete relief of all the pain except that of the upper half of the head, which remained unchanged. The relief afforded in this attack lasted about an hour, at the end of which time the pain had returned just as it had been. I saw her during two more "bad spells," the histories of which were identical with the one given. Each time cocainizing over the ganglion stopped all the pain except that of the upper half of the head, and the relief lasted about an hour.

Applications of ½ per cent formaldehyde were continued over a period of four months; the pain behind the eye and in the jaw having stopped in four weeks, for the most part. It occasionally returned in a lesser degree. The intervals between the "bad spells" became longer and their severity lessened. This case shows an involvement of the ophthalmic nerve as well as the nasal ganglion.

Sympathetic Pain

Case 32.—Mrs. A. E., consulted me October 10, 1916, because of headache, which in degree I think surpassed probably anything that is the fate of the ordinary rhinologist to meet. It was severe in the extreme. She gave the history of having the pain for many years. She had consulted many physicians because of

Digitized by Illinois College of Optometry

it. Finally, Dr. Harvey Cushing removed the semilunar ganglion for the relief of this pain. The operation was followed by total loss of sensation for the distribution of the trigeminus; but the pain persisted with great severity. Examination of the nose showed a violently inflamed sphenoid, which Dr. Thigpin of Alabama recognized. He sent her to me, with the idea that the injection of the nasal ganglion might be helpful. Experiment with the ganglion showed absolutely no influence upon the pain. It was therefore decided to open the sphenoid, which was attempted with the angle knife; but the bone was so hard that it could not be cut through. I then drilled, by means of a straight hand drill, into the sphenoidal sinus, and found upon entrance a small quantity of bloody serous fluid, probably more serum than blood. The headache stopped almost at once and remained so three days, at the end of which time it began to reappear and develop into its original severity.

The opening made by the drill into the sphenoid was not more than 3/16 of an inch in diameter, and it very soon closed up and reestablished the headache. I tried to persuade the patient to remain in St. Louis and give me more opportunity to treat her, but she was unable to do this. She returned to Alabama. Dr. Thigpin reported that the pain was quite as severe as ever.

This case interests me—seems to me to be illustrative of the fact that the sympathetic, when irritated, may produce great pain. Furthermore, that it may produce pain over a wide distribution; for this was not merely a lower half headache, although it was very violent in the lower half, at the same time it involved the entire skull.

In this case the semilunar ganglionectomy by Dr. Cushing was faultless, according to the observation of Dr. Bliss, upon the peripheral phenomena. In the beginning of my observation of the clinical questions of the nasal ganglion Dr. Cushing showed me six cases more or less similar to this one.

Sphenoiditis with Pain in the Shoulder Blades

Case 33.—Mr. B. A., age 35 years, consulted me March 7, 1914, complaining of very severe pain between his shoulder blades. He was sent to me by Doctor M. A. Bliss, who said that

Digitized by Illinois College of Optometry

he thought that he suffered from a sphenoidal disturbance. Examination of the nose at that time was negative. Continued effort for a diagnosis was unsuccessful for some little time but later a definite sphenoiditis, low grade suppurative, was apparent and the sphenoid opened. The "ball of fire," as the patient described the pain, was fortunately relieved rather quickly; in ten days it subsided, and has not returned. The case is interesting to me showing the intensity of a single symptom in connection with these lesions. The majority of the lesions are accompanied by a number of manifestations. This patient complained only of violent burning pain between his shoulder blades.

Herpes of Tongue—Glossodynia

Case 34.—Mrs. W. S., age 38 years, became my patient February 20, 1907. At that time she had a subacute lingual tonsillitis. October 20, 1909, she again became my patient because of headache and a post-ethmoidal-sphenoidal inflammation which was controllable from the nasal ganglion. Previous to November 18, 1909, her palate had been symmetrical, but on that date the arch on the right side was higher. She reported that the day before she had an unusually severe lower half headache which ran down into her hand. She was relieved of this attack and on December 2, 1909, pain was slight and the palate arch was almost symmetrical. January 26, 1910, she reported that she had had more or less lower half headache of lesser severity. The palate was symmetrical. December 12, 1910, she had a left sided quinsy. January 13, 1913, she again had a severe lower half headache, edema, and congestion over the left sphenopalatine foramen. Pain was stopped by anesthetizing the nasal ganglion. I continued to see her at irregular intervals because of violent lower half headache until six years ago. At that time the headache was accompanied by post-ethmoidal-sphenoidal suppuration. I urged her rather forcefully to submit to injection of her ganglia and operation upon her post-ethmoidal-sphenoidal district. She absolutely refused to do this and ceased to be my patient. She continued to have lower half headache and remained under the treatment of one of my confreres.

December 15, 1926, she returned to me because of herpes of the tongue accompanied by considerable pain in the tongue

Digitized by Illinois College of Optometry

(glossodynia) which she had had for about a year. Very careful examination over many days failed to reveal any post-ethmoidal-sphenoidal suppuration. The region of the sphenopalatine foramina appeared redder than the surrounding area. Cocainization of the nasal ganglia stopped the glossodynia. Knowing her attitude toward surgical issues, because of my previous experience with her, I did not propose any surgical measures. I insisted, however, that she should come for daily treatment of the inflamed membrane covering the sphenopalatine foramina. This she readily consented to because of some hope held out for her relief. She had been despondent over the herpes and glossodynia. Daily applications of 2 per cent silver solution to the inflamed membrane were continued up to the first of February, 1927, when they were changed to applications of 2 per cent mercuchrome. After February 18, 1927, the applications were made every other day or twice a week. The herpes began to improve from the first application, December 15, 1926. February 18, 1927, she was well. Mercurochrome was applied three or four times more, however, at intervals of three or four days. Her tongue has remained well up to the present writing, June 15, 1927.

This case is of interest because of the herpes which appeared with the glossodynia. Herpes of the tongue in my experience is very rare, this being the only case that I have had. Prior to becoming my patient December 16, 1926, she had not been under the treatment of anyone for anything for three years. She, however, consulted a dermatologist because of the herpes of her tongue, which, as I said before, was of one year's standing. It is also of interest to think of the part that the geniculate ganglion played in this case. It was almost surely the causative factor. It is also interesting to note how the treatment applied to the periphery of the geniculate ganglion was helpful. It is difficult for me to understand this pain of glossodynia. It may easily be understandable when one thinks that possibly the nerve trunk may be anesthetized. This is not true, however, in the herpes. Pain or glossodynia controllable through the nasal ganglion is another instance in which cocainization of one branch of a sensory nerve at rest stops pain in another nerve branch.

Digitized by Illinois College of Optometry

Glossodynia with Parageusia

Case 35.—Miss E. C., 70 years of age, became my patient September 22, 1906. At that time she had a discharge of pus from the middle meatus posteriorly. September 24, 1906, the left antrum upon puncture yielded pus which ceased upon washing. December 12, 1923, she again became my patient, being referred to me by Dr. V. P. Blair. She had a well-marked glossodynia with parageusia. At this time the case was purely ganglionic. Cocainization of the ganglia relieved the symptoms, and applications of mercurochrome repeated three times a week relieved the glossodynia and parageusia in eight weeks. The next year she had a coryza which reestablished these symptoms for about three weeks. Applications of mercurochrome again were successful. Since then she has been well.

Parageusia

Case 36.—Mrs. J. J., age 22 years, consulted me May, 1924, complaining that she had such a bad taste in her mouth that she could not eat. She had lost 10 pounds (4 kg.) in weight. A most careful examination excluded pus coming down from her nose. She had a well-marked hyperplastic post-ethmoidal sphenoiditis without secretion. Cocainization of the nasal ganglion, repeated six times, stopped the bad taste. Not infrequently patients complain of a bad tasting secretion or pus descending from the nose into the pharynx. In this case, satisfactory and prolonged observation eliminated this possibility.

Nasal Ganglion Neuralgia—Motor Phenomenon

Case 37.—J. A., 20 years old, strong, healthy, consulted me April, 1911. He had a well-marked nasal ganglion neuralgia, left, with constant pain, sometimes less and sometimes more. He was an enthusiastic golf player. It was declared to be a "golf arm" by his physicians (internists and surgeons). Three injections of phenol-alcohol were required before relief was complete and permanent. He has had recurrences from coryzas which have not, however, needed treatment. He has been free of pain for sixteen years.

Digitized by Illinois College of Optometry

Professional Cramp

Case 38.—Mrs. S. S., 40 years of age, had suffered violent lower half headaches (nasal ganglion headaches) all of her life, as far as her memory went. For the past ten years she has had added to the picture such pain on writing, as to make this difficult and pass as a writer's cramp of such severity that the only writing she has been able to do, and that with difficulty, has been to sign checks for the household expenses.

Examination revealed that the sphenopalatine foramen district was inflamed for some considerable distance around; that is, she had a hyperplastic post-ethmoidal sphenoiditis; but the pain was controlled by the application of cocaine to the ganglion.

For this reason I elected to inject the ganglion rather than do the post-ethmoidal-sphenoidal operation.

Each ganglion had now been injected three times, with considerable relief from the pain; and from the first injection of the right side, the writer's cramp has been absent. She is able to write as much as any other woman.

In one severe coryza, the cramp returned for the length of one week, when it passed off spontaneously.

A coryza causes headache often severe while it lasts and in the height of the pain, that entire side of the body becomes tender to touch.

This case, like some others reported here raises the question of pain sense transmission and how far it may be transmitted over the sympathetic nervous system.

April 26, 1919. Patient has had nodules with the acme of pain for a number of years. Attack now of unusual severity. Pain extends down entire spine and coccyx and into left leg. A large occipital nodule disappeared an hour after ganglion cocainization which also stopped the pain. The nodule otherwise disappeared in ten days.

January 29, 1920, patient had an acute coryza, particularly sharp earache, apparently severe pain in the neck and right sphenoid, accompanied by swelling one inch long, one-half inch wide, on the posterior margin of the sternocleidomastoid, two and one-half inches below the mastoid. Pain in the ear was so severe that she thought an abscess was developing, from her previous experience with abscesses. Vidian cocainization com-

Digitized by Illinois College of Optometry

pletely relieved all pain in the ear, neck, etc. An hour after the injection the swelling on the posterior margin of the sterno-cleidomastoid disappeared.

February 20, 1920, she had a severe coryza with severe pain on the right and then on the left side. On the left side the pain extended to the arm, side of her body, and leg. As stated above, cocaine usually relieved her, and in this attack it was also successfully used, being applied, however, posterior to the tip of the middle turbinate. This injection included the Vidian nerve more definitely than that from under the middle turbinate. This attack was accompanied for seven days by a sense of foreign body in the front of the nose, with pain in the nasal bones. Nasal ganglion or Vidian cocainization failed to relieve this. Complete relief was obtained from cocainization of the anterior ethmoidal nerve.

March 6, 1920, a small nodule appeared one inch below the insertion of the left trapezius. It was very sensitive to touch, and slight pressure on it caused pain which radiated to the left shoulder and shoulder blade. Another nodule, smaller and less sensitive, was situated one inch lateral to the above. Ganglion cocainization relieved the sensitiveness of these nodules. The small nodule disappeared one hour after cocainization.

April 7, 1920, she had been in an unusually severe exacerbation for the past few days. She stated that the day before she had particularly severe pain in the entire back of her neck and her neck "got full of lumps." Today she is better, but still has some of the lumps.

October 19, 1921, for the past ten weeks she has had some pain in the neck and shoulders. Today she is suffering more than usual. A nodule at the insertion of the trapezius, which was left from a previous attack noted above, became larger and very painful. Several smaller nodules appeared lower on the neck. These were observed by the masseuse. Six days ago she had the apex of the second right lower molar amputated and curetted because of an x-ray shadow. This was done under novocaine, and was accompanied by great pain which still continues. She came today because of severe pain in the neck and shoulder of the right side. Cocainization of the nasal ganglion

Digitized by Illinois College of Optometry

stopped the pain in the neck, shoulder and legs, as well as in the lower molar. Pain in the jaw stopped completely.

Since the last date she has been as a rule better. I still see her occasionally but there are no further notes of interest to be added. Cocainization of her ganglia has almost always stopped the pain for a number of days, sometimes weeks.

Professional Cramp

Case 39.—Mrs. S. A., 30 years old, consulted me January, 1913, at the request of Dr. M. A. Bliss. She had had a cyclical nasal ganglion neuralgia, left, severe for eight years. She was a professional violinist for the concert stage. The pain interfered with her practice until she was compelled to consult physicians. It was declared to be a "professional cramp" by the noted neurologists of Russia, Germany, France, and England. She was advised to stop playing the violin, which was "as dear as life itself" to her. This, together with the depressant nature of the Vidian pain, made a state of mind for her exceeding hard to bear. The anterior, maxillary part of the pain was controlled by the first injection of phenol-alcohol. The posterior (Vidian) pain required a second injection. For a year and a half she has been free of pain except at the time of a coryza, which was of short duration. She is able to practice and play in concerts and do an unusual amount of teaching (10 hours a day).

I have seen a bilateral nasal ganglion neuralgia pronounced a "piano cramp" for the same reasons that led to the error in this case.

Nasal Ganglion—Spasm of Esophagus

Case 40.—Mrs. V., aged 50 years, consulted me May 15, 1923, saying that "for the last ten days she could not swallow and that she was famished for food and drink and had lost ten pounds in weight." Examination of the nose and throat showed them to be normal. I then gave her some water to drink and found her statement to be true. X-ray examination showed a closure (spasm) of the esophagus at the third, fourth and fifth dorsal vertebrae with the bismuth bolus resting on top of it.

Effort to relieve the spasm by cocainization of the nasal ganglion by application of one drop of a 20 per cent solution

Digitized by Illinois College of Optometry

succeeded partially. The effect lasted one hour. This was repeated each day for increasingly stronger solutions, with more and longer effect. On the fourth day the ganglion was heavily cocainized by saturated (about 90 per cent) solution of cocaine with complete relief. The spasm has not returned.

In the course of a subsequent general examination by Dr. Vernon Mastin a 4+ Wassermann reaction was found, and antisyphilitic treatment was then begun. She is now in much better health and has gained fifteen pounds in weight. Syphilis may have been in some way the cause of the spasm. The antisyphilitic treatment may be the explanation of why it has not returned.

A general application of 20 per cent cocaine was made to the throat as a control of gagging in the first examination of the nose and throat. It did not help the spasm of the esophagus.

Nasal Ganglion—Motor Phenomenon

Case 41.—J. W. F., 40 years old, came to me December 15, 1915, complaining of a windpipe cough, with a lingual tonsillitis. He also gave the history of very severe stiffness of both shoulders, which he had had for 15 years. He was a strong athlete who delighted in water polo, and always felt that the stiffness of his shoulder was in some way connected with the exercise of that game. Cocainization of the ganglion stopped the stiffness of his shoulder; and so it was decided to inject the ganglia; both of which have now been injected three times. He is comfortable at all times, except during a coryza—then some discomfort in his shoulders redevelops.

The coryza for this patient is uniformly a suppurative post-ethmoidal sphenoiditis of high grade. It does not cause headache and recovers as an ordinary coryza, and when recovered, leaves no mark in its wake. For that reason, I have so far not decided upon any surgery more than the injection of the nasal ganglia.

Nasal Ganglion—Headache and Motor Phenomenon

Case 42.—Dr. H. F. L., 54 years of age, a surgeon of Statesville, N. C., was referred to me by Dr. W. R. Brandon, December 31, 1923. He gave a history of frequent colds for over fifteen

Digitized by Illinois College of Optometry

years (sympathetic type of ganglion neurosis). He had a left-sided lower half headache which extended down his arm into the middle and index fingers. He also had lumbago, as well as pain between his shoulders. This time he had an infraorbital neuralgia of eight weeks' standing which had been injected (peripheral) with relief. He stated, furthermore, that colds produced anterior headache and tingling of the left thumb, index and ring fingers. Accompanying these symptoms he had a gradual loss of power in his left arm, with cramping along the line of the median nerve. He continued to lose strength in his left arm until he was no longer able to operate. (He had been a busy physician and did a large amount of general surgery.) He finally consulted me because of this. In the course of his ailments he had an anterior lower half headache limited to the occiput on the right side. A most painstaking and lengthy examination revealed that cocainization of the ganglia stopped the sensory symptoms. Objectively he showed a high grade hyperplastic post-ethmoidal-sphenoidal lesion without pus. January 4, 1923, both ganglia were injected under gas at the Barnes Hospital. The subsequent four days were uneventful and he returned to his home. In correspondence later he stated that his headaches stopped in about three weeks after the injection, his lumbago was better, and his arm was regaining its strength. The pain between his shoulders stopped. At the end of three months he stated that he was well and had returned to his practice. In correspondence up to date he states that he is still well and working hard.

This case is of interest in itself. It belongs in the category of the motor phenomena already mentioned. It is one of the most satisfactory cases of all the ganglion injections of which I know.

Asthma—Glossodynia

Case 43.—Miss M. M., 37 years old, February 26, 1908, consulted me for general headache with severe morning sneezing. There was swelling of the cavernous tissues in the nose with profuse general watery secretion, but no pus or visible evidence of sphenoidal inflammation. In the effort to control this syndrome the anterior nasal nerves were injected with alcohol (Stein)

Digitized by Illinois College of Optometry

and trichloracetic acid applied to the tubercle of the septum (Francis) and middle turbinate, finally the galvanocautery to lower turbinates and tubercle, November 6, 1908; December 26, 1908. The nose was opened for air, but the sneezing continued. All efforts failed. She had to abandon a busy and very useful life for an indefinite period of rest. Dr. D. B. Delavan, who saw her in consultation, advised rest in the mountains. After six months in the mountains of the South she returned to St. Louis, well, and remained so for one year. At this time, March 17, 1910, she returned for treatment because of a "bad cold and headache," as she expressed it. She showed a bilateral post-ethmoidal-sphenoidal suppuration, for which I eventually operated, both sides (April 21, October 27, 1910). On January 10, 1911, she returned to me for an acute coryza with general headache and almost insufferable sneezing (sneezing to exhaustion) without evidences of post-ethmoidal-sphenoidal suppuration, for which she was again compelled to retire to the mountains. June 12, 1911, she again reported to me well. October 12, 1911, she consulted me because of intractable sneezing and general headache with an intense burning, stinging sensation in the nose ensuing upon a coryza. This time I began the intrasphenoidal applications of 1 per cent cocaine in oil, with 1 per cent phenol in oil, which controlled the sneezing and headache fairly well. A little later I began applications of 2 to 5 per cent aqueous solution of sodium salicylate, which proved much more satisfactory—the sneezing and headache stopped in about six days. February 17, 1912, a coryza again caused general headache and sneezing. This time, knowing that salicylate of methyl was a more potent remedy than the soda salt, and that it was usually tolerated, I filled the sphenoid with a 5 per cent solution of synthetic methyl-salicylate in oil. To my surprise and disappointment it aggravated the entire syndrome in great severity, and in addition produced asthma lasting five days. A little later, after applications of the sodium salt, she became comfortable; and this in a much shorter time than in the preceding attacks. Locally this case behaved like a hyperplastic ethmoiditis. In the inflammatory stage the membrane became edematous with polyp formations, which subsided when the attack was over.

Later she continued to be disturbed greatly by a coryza, a

Digitized by Illinois College of Optometry

slight coryza producing violent burning as mustard, inside of the nose, with severe pain, which awakened her out of her sleep at night. When the symptoms were severe, asthma developed, with the headache which accompanied this syndrome with greater or less severity. The symptoms, however, abated through instillation of one-third per cent carbolic acid within the sphenoidal sinus better than to anything that had been tried. Two per cent menthol instilled into the sinus produced violent headache and severe asthma. Most of the time she was comfortable. She is a very busy, hard-working woman. In her, a coryza is always accompanied by polyps within the sphenoid, which subside as soon as the severity of the coryza has passed. Dr. Wright's examination of sphenoidal tissue showed marked ostitis and periostitis.

November 18, 1912, the right sphenoid was reopened. General course of the case was not markedly altered. February 18, 1913, she reported that with each coryza she had a constant taste of brass in her mouth. February 10, 1919, she reported sneezing and asthma in the morning with tachycardia. January 29, 1920, unusually severe coryza with headache, sneezing, burning nose, and asthma. She also reported that in each attack like this a single herpes appeared at exactly the same point in the roof of the mouth and that it never varied. December 5, 1922, glossodynia for which I injected the nasal ganglia according to Dr. Dean's suggestion. The result was a failure. This particular case shows very clearly that when the glossodynia is a symptom of sphenoiditis injection of the ganglion may fail.

Asthma

Case 44.—Miss L., aged 60 years, was sent to me by Doctor Walter Baumgarten on May 28, 1914, because of an intractable asthma of fifteen years' standing. Examination of the nose showed a post-ethmoidal sphenoiditis, accompanied by much swelling, polyps, and very little secretion.

Effort was made to control the situation from the nasal ganglion. This failed. October 2, 1915, the sphenoid was opened on the left side, followed by relief of the asthma and general betterment of her physical condition, which, up to that time, was exceedingly bad.

Digitized by Illinois College of Optometry

The woman is still far from robust; but she is in comfort and fairly good health. The case is interesting as an asthma of long standing, of sphenoidal origin. It is also interesting from a therapeutic standpoint. I have, however, some other cases more or less of this origin and duration, which at present stand as therapeutic failures. They have chest involvement in addition to the sphenoiditis.

Asthma

Case 45.—Mrs. A. H., 35 years old, consulted me on April 24, 1916, saying that she had lower half headache, and that she had "hay fever in season; but it lasted all the year round." It was worse from August 15, until frost. Examination showed a well-marked post-ethmoidal sphenoiditis, localized at the site of the ganglion. Cocainization of the ganglion stopped the sneezing and nasal discharge; and on one occasion a low grade dyspnea, with dry râles, was also controlled by cocainization of the nasal ganglion. She was subject to frequent (every week) asthmatic attacks. They were each time controlled from the ganglion, more or less. This led me to inject the ganglia.

At the end of the year she was without headache. She says that she has been well, except on one occasion, when she contracted a bad cold in her nose, and she had asthma for one night, without any nausea.

She passed through the hay fever season without asthma or headache, except for slight symptoms extending over ten days. January 15, 1918, she consulted me because of a severe coryza, which caused a little headache and asthma.

This case is interesting because of the long-standing headache associated with asthma. It shows also that the symptoms may arise from various irritants; to wit, autumnal hay fever and whatever may cause a coryza in the region of the nasal ganglion. Seemingly, the lesion of the nasal ganglion originated from a low grade pathological process that was controllable by one injection.

Asthma

Case 46.—Miss N. M., 42 years of age, referred to me by Dr. Albert Taussig, October 7, 1920. For a number of years she had had violent asthma. She controlled the asthma, however, by

Digitized by Illinois College of Optometry

hypodermic use of 10 minims of adrenalin every hour. I found that cocainization of the nasal ganglion district would control the asthma for two or three hours. She informed me that if she were let alone the attack would come on and I might see the severity of it. The degree of severity of the dyspnea surpassed anything that the physician ordinarily sees. It was intense and extreme. I anesthetized her nasal ganglion district, with relief. On November 6, and 8, 1920, I injected the ganglia, right and left, with relief for three months. At that time a coryza reestablished the old severe asthma and caused a sphenoidal suppuration. February 28, 1921, I injected the ganglia, right and left. Relief was slight. She returned November 21, 1921, still presenting an inflammation. I operated upon the sphenoid, right and left, and found both sides full of polypoid tissue. January 30, 1922, I found the sphenoidal openings closed up and I reopened them. May 12, 1922, I resected the septum which mechanically interfered with breathing. September 29, 1923, she reported that she had had no further attacks of asthma.

Pupil and Asthma

Case 47.—Mr. W. C., 24 years old, very strong, large, normal man. My patient all his life, whenever a rhinologist was needed, and intimately known to me in every way, consulted me October 30, 1914, for a slight "cold in his head," which, as he said, he would ordinarily have not noticed, but for some special (social) reason he was anxious "for tomorrow" to be relieved. I gave him some small doses of calomel and told him to omit any local treatment because the local disturbance was so slight. Two days later he returned stating that his "cold" had taken a most unusual turn—that he had been awakened in the middle of the night with much sneezing and watery, running nose accompanied by smothering and wheezing. Examination which at first was negative now showed well-marked inflammation of the membrane over the sphenopalatine foramina. He had no other symptom of any kind. The dyspnea had diminished much. Cocaine applied to the foramina relieved it altogether. Phenol applied to the district prolonged the relief. The following night he had a slight return of it. The inflammation disappeared from recognition in a few days more, with recovery. Six weeks later

Digitized by Illinois College of Optometry

he returned, saying that he again had been awakened in the night with smothering, wheezing and running, watery nose. This time he had slight pain in his ears also. This time the attack was mild with slight changes locally, the same as above stated. Another slight recurrence happened four weeks later. Eight weeks after last note he developed an acute sphenoidal empyema with dyspnea, râles, sneezing, running, watery nose and moderate headache in ears, occiput and neck. This again yielded easily to treatment but did not get entirely well, when after six weeks' duration he developed vertigo and mental confusion to a most annoying degree, accompanied by the peculiar depressant power of the posterior headache (Vidian neuralgia) to a marked degree. (His disposition is normally most cheerful and confident.) (That which I mention as vertigo in these cases is almost never a sense of rotation. It is a sense of the earth shifting from side to side or forward and back or sinking out from under them.) May 15, 1915, he was well again.

In one of his years at college in Connecticut he had had some kind of a coryza, accompanied by more sneezing than he thought usual with his coryzas, but this was the only part of the above experience that was not new to him.

February, 1914, he consulted me again because of an inflamed sphenoidal district. He stated that during the interval he had been well. This time the inflamed sphenoidal district was accompanied with polypoid swelling and great sneezing. He also had asthma. Coryza passed off in two weeks and the polypoid swelling, as well as the asthma, subsided. September 22, 1915, bad sneezing and profuse secretion; marked enlargement of the right pupil; asthma. The post-ethmoidal-sphenoidal district of the right side was edematous. Cocainization of the nasal ganglion reduced the pupils to their normal size and stopped the asthma. I have not seen the patient since the last note, but I understand that he still has trouble with his sphenoid.

Nasal Ganglion Neuralgia—Sympathetic

Case 48.—Mrs. E. B. M., became my patient January 20, 1915. She had a profuse watery discharge from her nose and a hacking cough in the morning. She also had a marked rosacea. Her nose was enlarged about 20 per cent. I found that I could

Digitized by Illinois College of Optometry

control the secretion and the discharge by cocainizing the nasal ganglion. This was repeated many times and on April 12, and 24, 1916, the right and left ganglia were injected respectively. The result was unusually satisfactory. The secretion stopped and the rosacea disappeared. March 12, 1920, she had a severe coryza in the windpipe and nose with sneezing, also a lower half headache which was controlled by cocainization of the ganglion. Nose became red again. The rosacea disappeared as the coryza disappeared. February 10, 1921, she returned with a severe coryza, red but not swollen external nose, pain in the shoulder and arms, also pain in the external nose. February 15, 1921, she reported a recent severe coryza with nausea but no rosacea, sneezing, watery discharge, lower half headache of ten days' duration. Relieved by cocainization of the ganglia.

I have had a great many other cases, where the serous discharge was quite profuse, but in which no rosacea developed.

I have also seen many times, with an acute condition involving the sphenopalatine district, complete and perfect external red and swollen noses, where the serous discharge had not had time to effect any skin irritation. In this patient there was, as far as I could make out, no skin irritation. It was a state of red swelling without inflammatory skin involvement.

Change to Sympathetic Type With Anaphrodisiac Effects

Case 49.—S. Y., 50 years old, normal man, had throughout his life what I should term "ordinary" coryzas beginning with sneezing lasting three or four hours and watery discharge of usually one day, after which, nasal obstruction for two or three days, followed by thick mucopurulent secretion. Very seldom, a few times in his life, he had slight headache lasting a day or two. In 1912 he developed a type of coryza manifested by watery secretion and sneezing only. The obstruction and suppuration were omitted. During that year he had four such attacks, all much milder than his previous attacks. In 1913 he had added to this a sharp complete nasal ganglion neuralgia which harassed him more or less for two months and a paroxysmal morning sneezing lasted two months longer. Since 1913 he has had six such attacks, each with more or less eye discomfort added to the profuse watery secretion and marked sneezing

Digitized by Illinois College of Optometry

with pain in and around the right eye; earache and stuffiness, pain in mastoid, occiput, neck, shoulder blade, shoulder, arm and forearm. In this time he has not had the mucopurulent discharge of former times. The sphenopalatine foramen membrane was markedly inflamed, and once he had a well-marked post-ethmoidal-sphenoidal inflammation.

This case shows how the sympathetic elements once added to the clinical factors have recurred with each coryza over a period of six years. He also reported marked anaphrodisiac effects at the time of the attacks.

Vernal Hay Fever

Case 50.—Mrs. J. S., 46 years old, my patient since 1898, for many years has had vernal hay fever of marked severity accompanied by red and swollen nose and tearing eyes. Cocainization of the nasal ganglion a few times in the course of the spring months is sufficient to carry her through the attack with only a very slight morning sneezing on irregular days. Her external nose, however, becomes red and swollen at any time of the year from the slightest irritation of the internal nose and remains red without recognizable cause much of the time. Silver nitrate applied to the sphenopalatine membrane two or three times a week out of hay fever season brings the appearance to normal. It then remains so for long periods, to be excited again from within the nose. In the hay fever season she has dyspnea with dry râles equally distributed, right and left. Cocainization of the nasal ganglion of one side will *stop* the *râles* on that side. All treatment known to me prior to the spring of 1914 was in vain. At that time I began the cocainization of the nasal ganglion and the treatment of the rosacea followed that.

Vasomotor Rhinitis and Nasal Ganglion

Case 51.—A. L., age 35 years, consulted me on April 19, 1915, complaining of intractable sneezing, marked watery secretion and total nasal obstruction. She said that she had hay fever all the year round. Examination showed a high grade hyperplastic post-ethmoiditis. The injection of the nasal ganglion, twice on each side has succeeded in checking the secretion and shrinking

Digitized by Illinois College of Optometry

the swelling which gave rise to the nasal obstruction. At the time of the injection the swelling appeared to be a polypoid-edematous swelling of the entire nasal cavity. This case is to me of interest, particularly showing how sometimes the control of the nerve supply will shrink up the edematous swelling that we occasionally see. I have other cases in which I tried to give the same treatment and succeeded in some and failed in others, the failure usually being to shrink up the edematous swollen membrane.

Nasal Ganglion—Conjunctivitis

Case 52.—H. H. F., 32 years old, strong, normal man, consulted me March, 1912. He had an intractable low grade conjunctivitis, which was left in the wake of a "bad cold in his head, four years ago." Every coryza made is worse. Cauterization of the sphenopalatine foramen membrane with trichloracetic acid four times, at two-weeks intervals, gave prolonged relief. Coryzas rekindle the trouble, but he becomes comfortable again in a short time.

Vasomotor Rhinitis

Case 53.—Miss E. C., 28 years old, consulted me June, 1914, because of "hay fever" (paroxysmal sneezing with secretion), which had lasted uninterruptedly six years, accompanied by constant discomfort referred to her eyes with slight constant lacrimation and slight Vidian neuralgia (see above) which was intermittent and sometimes severe. She had a low grade (non-suppurative) hyperplastic sphenoiditis, but the entire symptom-complex was controllable from the nasal ganglion which I injected with phenol-alcohol with relief of all symptoms for one year.

Nasal Ganglion—Hay Fever

Case 54.—Mrs. T. C., 33 years of age, became my patient December 27, 1916. She had had sneezing attacks for three weeks with low grade nasal obstruction and no headache. Examination showed posterior sphenoidal suppuration with serous and seropurulent secretion, left side. She had an autumnal hay fever. January 22, 1917, left ganglion injected. January 29,

Digitized by Illinois College of Optometry

and April 28, 1917, right ganglion injected. December 6, 1917, reported as well with no nasal obstruction. April 20, 1919, complained of an occasional headache. January 27, 1922, reported bad headache off and on, but no nasal obstruction. December 6, 1922, both sphenoids, right and left, were opened under twilight sleep at Barnes Hospital. The patient was never relieved to the extent that it was hoped. Left sphenoid closed up and was reopened June 28, 1923. She has been examined extensively and no general condition has been found to explain the headache. Pituitary extract, thyroid extract, and tuberculin have also been employed in vain. At times she has violent headache which can be controlled only with morphine. While the case stands as a failure in every way at present it cannot be explained.

Nasal Ganglion—Sympathetic and Sensory

Case 55.—Mrs. C. W., 50 years of age, became my patient March 16, 1914. She complained of coryzas which caused great lacrimation, and a pepper pain in her nose, with shortness of breath and great sneezing. This was always controlled by a small application of cocaine to the nasal ganglia. December 28, 1914, I injected the right ganglion; great relief followed. On March 16, 1918, and again on October 14, 1918, I injected the left ganglion. Both injections were followed by relief of symptoms.

Lower Half Headache—Vertigo

Case 56.—Mrs. H. C. M., 35 years old, Joplin, Mo., consulted me December 15, 1917, complaining of severe lower half headaches, right and left, accompanied by dizziness—"the objects went around her"—of such severity that she was able to walk only with difficulty. She had suffered 8 years from these conditions. Examination revealed a well-marked post-ethmoidal sphenoiditis, with considerable acute element mixed with it. In the effort to localize the point from which the pain proceeded, cocainization of the ganglion was followed by cessation of the headache, with almost instantaneous relief of the dizziness. After six hours the headache returned to some extent; but the dizziness was almost absent.

Digitized by Illinois College of Optometry

Owing to this patient's living at a distance, further observation has so far been impossible.

This patient had been carefully investigated in every detail of a general examination.

This case is of interest showing dizziness, of rotatory type stopped by cocainization of the nasal ganglion.

Nasal Ganglion—Coryza with Vertigo and Scotoma

Case 57.—M. C., 50 years of age, consulted me January, 1910. He complained that with every coryza he had a headache. He had no sphenoidal suppuration. His nose was normal. February, 1920, he again consulted me because of a coryza with transitory scotoma and vertigo, but without headache. The coryza was unusually severe and passed off in two weeks, as did the scotoma and vertigo. He was otherwise normal.

Nasal Ganglion—Nausea and Vomiting

Case 58.—Miss C. F., 27 years of age, consulted me December 9, 1915, because of a chronic lingual tonsillitis. This patient was in the habit of consulting me for simple coryzas. November, 1924, she had a coryza with considerable nausea and purposeless vomiting of great severity. The coryza ran the customary course of ten days or two weeks. I have had three other patients that complained of a great nausea and purposeless vomiting that accompanied every coryza. In these patients this condition existed from their earliest remembrance. In them it could be stopped by cocainization of the nasal ganglion or intrasphenoidal cocainization.

Nasal Ganglion—Glaucoma, Vertigo and Nausea

Case 59.—Mrs. K. D., 51 years of age, was referred to me by Dr. M. H. Post, November 22, 1919. She had a simple glaucoma of long standing. Cocainization of the nasal ganglion reduced the tension 22 millimeters. The reduction of the tension was transitory, as has been explained in the body of the text. She returned June 28, 1920, with corneal ulcers, iritis with hypopyon, and severe pain which could be controlled by cocainization of the nasal ganglion. December 6, 1920, she consulted me because of

Digitized by Illinois College of Optometry

vertigo and nausea which were stopped by cocainization of the ganglion. They did not return.

Nasal Ganglion—Otalgia, Nausea and Diarrhea

Case 60.—R. S., 40 years of age, consulted me January 14, 1922. She has suffered from nausea for two years, usually in the morning and constant for ten days. During this time she had recurrent severe pain in her neck and shoulder which ran down her back and into the right loin. It was relieved by cocainization of the ganglion. Nausea was stopped instantly by the injection of the ganglion. Injection was followed at once by anterior pain, three hours later by posterior pain. I have had much experience with this patient since the above date and nothing has controlled the nausea or posterior pain. Once she had an acute sphenoidal sinus infection, but that has been well for three years. During this period she suffered great pain in the loin, running downward into the groin and then down the leg. She had three such attacks during this time accompanied by diarrhea which internal medication failed to control. It was stopped by cocainization of the ganglion.

Recently she has suffered with intense otalgia which has not been relieved by the removal of two carious molars.

HYPERPLASTIC POST-ETHMOIDAL SPHENOIDITIS—OCULAR LESIONS OF POST-ETHMOIDAL- SPHENOIDAL AND NASAL GANGLION ORIGINS

Ophthalmic Migraine, Iritis, Pupil, Choroiditis, Optic Neuritis, Ocular Paralysis, Glaucoma, Amblyopias, Scotomas, Blepharospasm, Etc.

Ophthalmic Migraine—Suppurative Sphenoiditis

Case 61.—Miss J. J., 22 years of age, consulted me May 1, 1921, because of an attack of ophthalmic migraine which she experienced for the first time with a suppurating right sphenoid. It began as a severe coryza. On July 6, 1921, I have the note that attacks which had been every three or four days before had diminished to scotoma without headache. At present this woman is free from ophthalmic migraine and all its details.

Digitized by Illinois College of Optometry

Ophthalmic Migraine

Case 62.—S. A., 23 years old, normal but not up to full strength, consulted me October 25, 1912. He showed at that time a hyperplastic post-ethmoiditis most marked over left sphenopalatine foramen. He had had for 10 years a severe cyclical nasal ganglion neuralgia, left, recurring once in three to six weeks. The attack was always accompanied by *scotoma scintillans amblyopia,* lower half headache, vomiting, aphasia and hemiparesis of short duration. I injected the left ganglion three times with phenol-alcohol. For eight years he has been free of the attacks except that a severe coryza reestablishes the syndrome temporarily.

A coryza causes a mild blepharospasm. Sometimes the attack is accompanied by salivation and vertigo (slight).

Ophthalmoplegic Migraine—Vertigo

Case 63.—G. L. A., 67 years of age, had suffered from dizziness which he described as "a shifting of the earth from side to side," for 18 months. He also suffered at intervals with what he described as a crossing of his eyes, accompanied by a total obscuring of his vision. Each of these attacks lasted for only a few minutes. Seldom did he have a slight lower half headache.

His case had been investigated extensively in all departments, and no cause could be assigned for his trouble. Examination of his nose revealed a bright red color throughout, but particularly through the sphenoethmoidal district. Treatment was unsatisfactory, and finally, on April 5, 1917, the sphenoid was opened.

After the operation he was free of dizziness and eye disturbances for six months. A coryza reestablished the symptoms to some extent. His condition in general is improved.

This case is of interest because of the color alone being the only indication of sphenoidal trouble.

The dizziness is markedly improved; and the attacks of strabismus—"blindness"—have ceased, with one exception, and that at the time of a coryza. This history sounds much like ophthalmoplegic migraine. I have occasionally seen dizziness in these cases described as a falling sensation.

Digitized by Illinois College of Optometry

Ophthalmic Migraine

Case 64.—Mrs. M. H., 27 years old, had had for ten years a recurrent life ophthalmic migraine at irregular (months) intervals. Examination showed a left low grade post-ethmoiditis which suppurated with coryza. Observation revealed that the attack was uniformly established by a coryza. At other times she was well.

Ophthalmic Migraine—Scotoma

Case 65.—Miss E. S. consulted me Oct. 15, 1916, because of severe headache which was more or less constant. She complained also of an admixture of some other kind of headache that came on at intervals of two to three weeks, characterized by scotoma scintillans and vomiting.

Examination showed a profuse right-sided sphenoidal suppuration which was operated, with relief of the suppuration; also the relief of the headache which had been more or less constant.

However, the other headache she described has continued unchanged. Her description was that she felt something which started in the instep of her right foot, and then extended to the right half of her body, including her head, with violent headache and blindness.

This case seems to me to be one of rare pure migraine—rare in my experience, where most are independent of the nasal condition.

Ophthalmic Migraine—Scotoma—Hemianopsia

Case 66.—Mrs. L. E., 26 years old, referred by M. H. Post, September 24, 1913, with the report that her eyes were normal. She had a complete right-sided ophthalmic megrim, 7 years' duration, scotoma scintillans, violent headache (lower half), nausea and vomiting, hemianopsia amblyopia. The attack came every four days, approximately. My diagnosis: Marked hyperplastic sphenoiditis, R. She grew slowly worse; the attacks became more frequent and more severe. Post-ethmoidal-sphenoidal operation, right side, January 2, 1914. Dr. Wright's report of the changes in the sphenoidal wall: Here is a very marked in-

Digitized by Illinois College of Optometry

volvement of the bony structure. The periosteum is greatly inflamed and there is a quite marked hyperplasia of the bone. The soft parts over it are in a state of chronic inflammation. The middle turbinate shows only a moderate change in the soft parts and the bone is not much involved. The surface epithelium is also not much involved.

She became better as soon as the wounds were healed and the reaction totally subsided; and has since then been for the most part well. A coryza reestablishes the syndrome, but it usually does not need local treatment.

In another complete ophthalmic megrim (Mrs. D., 30 years old) the mucous membrane in the sphenoidal sinus at the time of operation showed, with Holmes' pharyngoscope, a most marked thickening and induration with dryness and pallor. Dr. Wright's report of the changes in the sphenoidal wall microscopically are: The inflammatory changes here are quite marked. There is a considerable degree of inflammation of the periosteum and some evidence of hyperplasia of the bones while the soft parts over it are markedly involved in the chronic inflammatory process.

This was a bilateral case, one side only being operated upon. There has been only moderate betterment clinically.

These cases to me show the difference in prognosis between a post-ethmoidal and a sphenoidal lesion. Mrs. L. E. had a migraine exploded from the nasal ganglion. In Mrs. D. it began probably in the nerve trunks.

Ophthalmic Migraine—Scotoma—Hemianopsia

Case 67.—Mrs. W. A. M. became my patient January 6, 1922. She complained of headache with attacks of blindness two or three times a day, lasting 45 to 50 minutes, for the past few years. Inquiry revealed that she had a complete ophthalmic migraine with an alternating scotoma and hemianopsia. She had a post-ethmoidal-sphenoidal suppuration. March 23, 1922, post-ethmoidal-sphenoidal operation, right and left, under twilight sleep at Barnes Hospital. The result in every way was satisfactory. Headache stopped, and on June 7, 1923, she had gained nineteen pounds. A report made January 1, 1925, was to the effect that she was well in every way.

Digitized by Illinois College of Optometry

Nasal Ganglion—Iritis

Case 68.—Miss J. B., 24 years old, consulted me June 10, 1914. She had been my patient five years before for some trifling acute trouble of short duration. Present history: For three years has been subject to attacks of iritis, with photophobia, redness and pain not only in eyes but extending to occiput, which would get nearly well and then continue in low grade for months to be rekindled from causes unknown. The condition is much improved, but far from well. The sphenopalatine foramen membrane of the left side is inflamed and thickened. The iritis is always on left side. Cocaine applied to foramen stopped the discomfort in eye and occiput in five minutes. It did not return. Silver nitrate and acetic acid applications were made to complete the treatment. The redness, pain and photophobia of the iritis did not return after the cocaine application. Two weeks later the eye was declared by her ophthalmologist to be well.

Iritis

Case 69.—L. R., aged 30 years, sent to me by Doctor A. E. Ewing, Jan. 10, 1918, because of an intractable iritis. Doctor Ewing had given treatment which left much to be desired in the progress of the case for the control of pain. He, therefore, submitted the patient to me for a nasal examination.

A clearly marked post-ethmoiditis was found upon that side (right). The lesion was soft, velvety, swelling of the posterior tip of the middle turbinate, without secretion.

Complete cocainization of the ganglion relieved all the pain in his eye, and was followed by an immediate turn for improvement, which continued from then on. The nasal ganglion was cocainized slightly after that for ten days, when the condition in his eye had improved so much that it seemed unnecessary to pursue the anesthesia. The nose was treated for another ten days with carbolized oil. His eye recovered, and he was dismissed. The lesion within his nose, in the mean time, appeared to completely subside.

Many times I have seen such cases as this, always of great interest, and impossible of explanation at present.

Digitized by Illinois College of Optometry

Uveitis with Post-ethmoidal Sphenoiditis

Case 70.—B. J. K., referred to me April 27, 1917, by Dr. J. W. Charles, for a very severe uveitis of six weeks' standing, accompanied by pain in the left shoulder, which had endured for seven years. Examination showed a gray greenish spot in the sphenoethmoidal recess, which I took to be the outlet of the sphenoid with a small degree of secretion smeared within it.

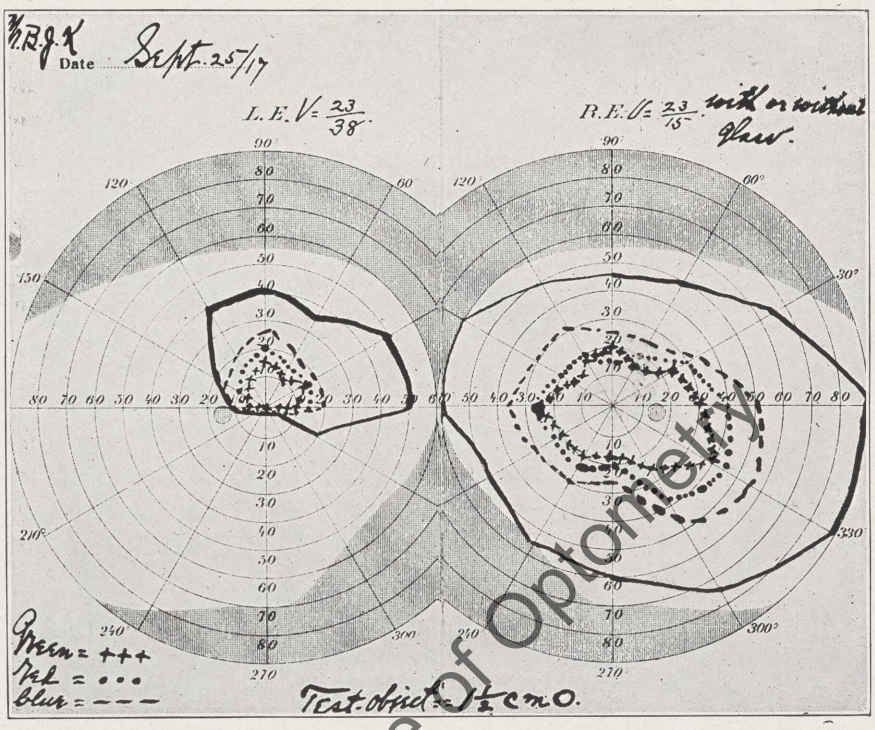

Fig. 164.

Applications of carbolized oil driven forcibly into the olfactory fissure, were followed by almost immediate improvement. The condition continued to improve under this treatment, and finally recovered totally. Dr. Charles was very much interested, and kept elaborate notes; and has given me a full report, which I herewith attach.

B. J. K., porter, 41 years old, came April 27, 1917, having been taking (for 5 weeks) KI and sodium phosphate because of failing vision in his right eye in which there was also

Digitized by Illinois College of Optometry

great pain (too marked for the degree of redness). The ethmoidal region of that side was very tender. Bowels move regularly. "Digestion perfect."

The left eye has been defective and has diverged for eight years. The patient was "cured of iritis six months before and had a blood test which was negative."

R.E.V. = 23/240. Very marked hyalitis (cyclitis), so that all details of the fundus were obscured.

L.E. with +1. cyl. ax. horl. V. = 23/38.—Large spot of choroidal atrophy extending to the optic-disc-margin.

The fields showed a decided narrowing for colors with R.E. an enlargement of the normal blind spot.

Patient was given atropine and cocaine in oil in the right eye.

April 30, R.E. without correction V. = 23/120, with +1. Sph. V. =23/60.

May 5, Dr. Buhman reported a negative Wassermann. A E. Belton reports good teeth (x-ray).

May 7, R.E. 23/96, with +1. Sph. +0.5 cyl. ax. horl. V. = 23/75+.

The optic disc was now seen to be more blurred (in comparison with blood vessels) than was to be accounted for by the muddy vitreous alone—papilloedema.

May 15, R.E. with glass V. = 23/38. The enlargement of the normal blind spot had disappeared, the fields beginning to improve.

June 3, R.E. with glass V. = 23/19. Vitreous and disc much clearer.

Sept. 25, R.E. with glass V. = 23/15. Disc and vitreous normal. No more pains. (Figs. 114 and 115.)

Jan. 21, 1918, no change. Patient well.

Iritis with Punctate Keratitis

Case 71.—Mrs. A. B. N., 24 years old, was sent to me April 19, 1917, by Dr. A. E. Ewing because of a punctate keratitis with "iritis" that had been going on in the left eye four years and in the right eye two and one-half years. Ophthalmological treatment did not control the trouble. A low grade sphenoiditis with very scant serous discharge was recognized with great difficulty. Treatment of the district helped for a while. A

Digitized by Illinois College of Optometry

coryza rekindled the eye trouble and it was then uncontrollable. The post-ethmoidal-sphenoidal operation was done, left, April 2, 1918, right, April 29, 1918. Three days after each operation each eye was free of active pathological process.

Acute Iritis—Hyperplastic Sphenoethmoiditis

Case 72.—W. G. S., 25 years of age, was referred to me by Dr. A. E. Ewing, January 10, 1913. He had had many attacks of acute iritis with great pain at intervals of four to six months. He had a hyperplastic post-ethmoiditis with a well marked velvet-like swelling of the posterior tip of the middle turbinate, right side. He refused operation until October 14, 1919, when I removed his tonsils because of chronic tonsillitis. This did not help his eyes. November 18, 1920, I injected the nasal ganglion. This controlled much of the pain and benefited his eyes. He continued to have iritis, less severe, however, and on December 13, 1921, I opened the right posterior ethmoidal sinus. Since that time he has had two attacks of moderately severe iritis which grew well in one-fourth the customary time. Treatment was, of course, applied to the posterior ethmoidal sphenoidal region during these attacks.

Intrasphenoidal Observations of Interest

Case 73.—A. B., strong, healthy man, 30 years old, referred by Dr. A. E. Ewing, January 15, 1915, for a severe serous iritis right side, with blood in the vitreous. Vision 3/120 right eye, left normal. My diagnosis: Sphenoid suppuration, right side. It appeared subacute with no definite hyperplastic features. No headache. He did not accept the proposed surgical procedure. February 7, 1915, he developed an acute coryza. February 10, 1915, he returned. V. counts fingers at 1 foot, recognizes the movement of hand at 3 feet. The anterior chamber is now full of blood. February 11, 1915, post-ethmoidal-sphenoidal operation. The cavity of the sphenoid was found to be large and lent itself to very satisfactory surgical manipulation. The anterior wall was readily cut out with sufficient general shock to lower the blood pressure so that there was almost no bleeding and withal no syncope. He was then, as it were, a perfect manikin.

Digitized by Illinois College of Optometry

The Holmes pharyngoscope was at once introduced into the cavity of the sphenoid which showed on that part forming the inner aspect of the optic canal, a patch a little less than 1 cm. in diameter, the center of which was bluish gray and thickened and marked by blood vessels, centered there from all directions. It was one of those vascular communications described by Shambaugh and others between the membrane of the canal. From its center the thickening began to recede and the color to approach normal. The remaining membrane showed somewhat of a bluish addition to its color. The cavity held a scant secretion apparently opalescent. In 8 days the patch and blood vessels had vanished, and the eye had begun to improve from what was a progressively desperate state according to Dr. Ewing—5 mos. V. 3/75.

Dr. Wright's report of the changes in the sphenoidal wall: Hyperplasia M. M. erectile tissue. Enormously dilated. Sinus gorged with blood. No bone involvement, slight periostitis. Sphenoidal wall: This is an exceptional chronic edematous inflammation of the mucous membrane, exceptional in this: (1) the great development and dilation of the erectile venous sinuses in this situation. (2) The thickening of the media of the coats of the radicle arterioles. (3) The very moderate amount of bone affection, considering the excessive (for this situation) amount of periosteal thickening, but the bone itself is not materially involved.

Apparently we have here an inflammatory process which has extended along the nerve sheath, if we are to preserve the character of the inflammation the same in the sinus as in the middle turbinate, before marked change is produced in the underlying bone locally in the nose. Mucous membrane shows extensive degeneration with evidence of primary vascular change.

Lower Half Headache—Pupil

Case 74.—Mrs. C. F., 35 years old, consulted me January 1, 1918, at the suggestion of Dr. Fayette Ewing. She had suffered violently from headache a large part of her life. Dr. Ewing had found some disease of the ethmoid on the left side, and had curetted the capsule of the ethmoid for that reason. She continued to have great headache; and as Dr. Ewing was about to

Digitized by Illinois College of Optometry

depart for service in the National Army, he put her in my charge. In the effort to localize some starting point for the pain, I cocainized the ganglion of the right side at a time when the headache was on the right side. The headache was stopped; but as an effect of cocainization the right eyelid drooped very perceptibly, to obscure probably half of the blepharal fissure, and the pupil contracted to be one-half of the size of the fellow of the opposite side. The case presents this interesting phenomenon: that through the nasal ganglion in this patient must pass a large part of the sympathetic supply which goes for the elevation of the eyelid and to the pupil.

I injected the ganglion three times, which helped her very much. In the course of the observation, April 5, 1919, cocaine to the left nasal ganglion stopped the pain of anterior distribution but not the posterior pain. Cocaine then applied to the right ganglion stopped the left posterior pain, but caused the right eyelid to droop and contracted the right pupil to half the size of the left.

Nasal Ganglion—Pupil

Case 75.—Mrs. B. C., aged 33 years, in 1913 consulted me because of obscure headache. She had clearly a vacuum frontal headache, for which the anterior three-quarters of the middle turbinate were removed with entirely satisfactory results. She still has at times headache which apparently proceeds from the nasal ganglion on the right side. It is controlled by cocainization of the ganglion, and shows at that site inflammation over the sphenopalatine foramen. Cocainization of the ganglion in this patient is often followed by dilatation of the pupil on that side apparently indicating the reverse action of cocaine, that is, irritation to the sympathetic in contradistinction to the case just reported, where it was evident that complete paralysis took place (Case 74).

Pupil

Case 76.—J. H. A., 37 years old, strong, healthy man, had never had a headache in his life that he remembered; consulted me May 27, 1910, because of a severe left-sided headache which had lasted three weeks. He showed a left sphenoidal post-eth-

Digitized by Illinois College of Optometry

moidal suppuration. His pain was parietal and occipital, for the most part, and irregular in severity, sometimes stopping. When severe it was combined with pain in brow and upper jaw. He was melancholic. Treatment was not satisfactory. (He was compelled to be out of the city five days of every week.) On October 12, 1910, he took the proposed operation. The reaction was severe. He was free of symptoms in three months. March 4, 1911, he consulted me because of a coryza with pus which recovered spontaneously. January 6, 1912, he returned because of a coryza with headache which did not recover spontaneously. At that time he did not show pus in the sphenoid. He had suffered greatly from intermittent general left-sided headache. Believing that the anesthetic qualities of carbolic acid could be soaked into the nerve trunks in juxtaposition to the sphenoid, I filled the cavity with 1 per cent solution in oil, which stopped the pain within six hours. The cavity was filled once a week for three weeks, when he seemed well, and remained so until the next coryza, six weeks later, which was controlled by 1 per cent carbolic acid in oil. The left pupil is larger than the right during these attacks, and use of his eye is somewhat difficult at those times. He says his pupils were always equal before his headache began and are so now in the intervals between coryzas when he is free of headache. This case has so far not behaved as a hyperplastic ethmoiditis. In the inflammatory attack there is only redness with little swelling, and sometimes pus.

Dilated Pupil

Case 77.—Miss J. W., age 44 years, was referred to me Nov. 19, 1917, by Dr. A. E. Ewing, whose patient she had been for various eye troubles off and on for twenty years. Dr. Ewing's statement was that for three months she had noticed an enlargement of the right pupil. She also gave a history of a marked lower half headache, right, at frequent intervals for fifteen years. The headache, which has been a great trial to her for the past six years has been accompanied by a sense of "falling backward." Dr. Ewing treated her enlarged pupil by the instillation of pilocarpine. The pupil would contract; but did not remain contracted, and because of the unsatisfactory condition he referred her to me.

Digitized by Illinois College of Optometry

Examination of the nose showed a very clearly marked hyperplastic post-ethmoidal sphenoiditis without secretion, on the right side. The left side appeared very much less so, which is contrary to the rule for these cases; the lesion usually being bilateral. Treatment of the sphenoid accomplished nothing. Jan. 24, 1918, I did the post-ethmoidal-sphenoidal operation upon the right side. May 10, 1918, she reported saying that she was free of headache. Examination showed that her pupil which had been 6 mm. in diameter had contracted down to 4 to 4½ mm. without pilocarpine. Syphilis was absolutely excluded in this patient as well as any intracranial lesion.

The case is to me unique and interesting because of dilatation of the pupil with no other eye disturbance. It is interesting to compare it with Case 95, in which the paralysis of accommodation was complete but no dilatation of the pupil with it. Unmixed dilatation of the pupil is rare in my experience, this being the only case where the disturbance seemed to arise from the sphenoid.

Sphenoiditis with Choroiditis—Secondary Closure of Sphenoid With Optic Neuritis

Case 78.—Miss M. L., consulted me Sept. 21, 1914, for choroiditis, Dr. M. H. Post's report of which I herewith attach. Examination showed a post-ethmoidal sphenoiditis of low grade, suppurative (seropurulent). No mark of hyperplasia. Tentative treatment failed to relieve her condition. Bilateral post-ethmoidal-sphenoidal operation was done. Right sphenoid, Sept. 25, 1914, left, Oct. 12, 1914, with recovery of vision.

The patient was brought to me again on December 15, 1917, by Dr. A. E. Ewing, for an optic neuritis of the right eye. There was a swelling of 4 diopters. Examinations showed the sphenoid cavity of the right side totally closed by a membranous formation, which was at once opened; with the result that the improvement of vision was immediate.

Ophthalmological notes by Dr. A. E. Ewing.

Pain in right eye during the last ten days.

O.D. V. = 20/20. O.S. V. = 20/20.

Pain relieved by general treatment.

Digitized by Illinois College of Optometry

1914, Sept. O.D. sore for about four weeks. Vision "blurred."

O.D. V. = 3/75. O.S. V. = 20/20.

O.D. Numerous areas of pigment deposit and white swelling with atrophy of choroid in upper nasal portion of the fundus. These are also edematous swellings of the retina.

O.S. Condition similar but less marked is mainly in lower nasal portion of the fundus.

Treatment, KI, increasing doses.

O.D. Three large nearly constant scotomata in field.

O.S. Field normal.

Sept. 21. Complains of black spot at center of vision O.S.

O.D. V. = 20/150. O.S. V. = 20/20.

Sept. 27. Operated upon by Dr. Sluder.

Oct. 30. O.D. V. = 20/150. O.S. V. = 20/30.

Ophthalmoscope shows very little change.

Dec. 7. O.D. V. = 20/96. O.S. V. = 20/20.

Each fundus more quiet.

1915, Jan. 18. O.D. V. = 20/38. O.S. V. = 20/20.

O.D. Condition of fundus improved, but there are a number of fine hemorrhages.

O.S. Fundus quiet.

March 29. O.D. V. = 20/27. O.S. V. = 20/20.

O.D. Fundus very quiet.

O.S. Fundus very quiet.

1917, Nov. 27. Return of "blurred vision" O.D. for about a week. O.D. V. = 20/192. O.S. V. = 20/15. O.D. Marked neuroretinitis, disc margins not definable. Swelling of disc measured by 4d.

Referred to Dr. Sluder.

Dec. 6. O.D. V. = 20/75. Disc less swollen.

1918, Jan. 18. O.D. V. = 20/38. Disc nearly normal.

(Not seen since this data.)

Many times have I seen sphenoidal cases redevelop the eye trouble under acute coryza or closure of the cell; but they have always been the same lesion, that is, sphenoiditis that caused a choroiditis on one occasion under the influence of a coryza or closure has redeveloped a choroiditis again. This is the only case in which a choroiditis of both eyes was the primary

Digitized by Illinois College of Optometry

lesion, which was followed by an optic neuritis from closure of the sinus two years later.

Choroiditis—Intrasphenoidal Observation

Case 79.—Miss A. K., 40 years old, normal, referred December 13, 1913, by Dr. M. H. Post, Jr., for choroiditis, L. V. 20/94 L. My diagnosis: Post-ethmo-sphenoiditis with edema and pus, left. December 9, 1913, post-ethmoidal-sphenoidal operation. At the time of opening the cells were found by the pharyngoscope to contain polyps. Vision has risen to 20/24. A scotoma remains. She sees a black spot in the upper outer field of that (left) eye. Since the healing was complete and vision largely restored I have seen her in 4 coryzas. She lost vision in 3 of the attacks and showed by the pharyngoscope a patch of acute inflammation twice in the sphenoid at the site of the optic canal and once in the post-ethmoid with polyps at this site. In one coryza the patch was in the lower and outer area of the sphenoid and accompanied by severe lower-half anterior headache but no loss of vision. Dr. Wright has not examined the bone from this patient.

I had a similar case referred by Dr. W. A. Shoemaker with choroiditis, recurrent and severe headache relieved by operation with improvement of vision. The bone in this case has not yet been examined by Dr. Wright.

In two other cases diagnosed as nonsuppurative hyperplastic sphenoiditis with headache (lower half), there came at the time of greatest intensity of the pain in one case a loss of consciousness lasting usually from 5 to 10 min., and in the other the sight of innumerable men approaching from the right and countless rats approaching on the floor from the left. In both instances the pain and other features of the case were stopped by the operation to return at the time of a severe coryza and again disappear.

Choroiditis—Post-ethmoidal-sphenoidal Suppuration

Case 80.—Miss E. K., 30 years of age, referred to me by Dr. W. A. Shoemaker, December 20, 1920, because of choroiditis of the right side. She had a post-ethmoidal-sphenoidal suppuration of the right side which was operated upon one week later.

Digitized by Illinois College of Optometry

The result has been a total recovery for her eye. In the course of the history she related that for ten years every few days she would have a severe headache in her temples. She has escaped headache since the operation, except at intervals of weeks, when it is usually accompanied by an acute coryza. Throughout her life prior to the operation every coryza would be accompanied by nausea and purposeless vomiting which would last ten days at a time. This has been relieved to a very great extent. Since the operation she has had two coryzas in which she had nausea and vomiting. There has been no recurrence of the choroiditis.

Optic Nerve Involvement with Sphenoiditis

Case 81.—Mrs. S. N., consulted me April 18, 1907, complaining of lower half headache of the left side, and nasal obstruction. Nothing was done for her more than tentative treatment which was not satisfactory. She consulted me from time to time as the years passed, always declining operative procedure. During

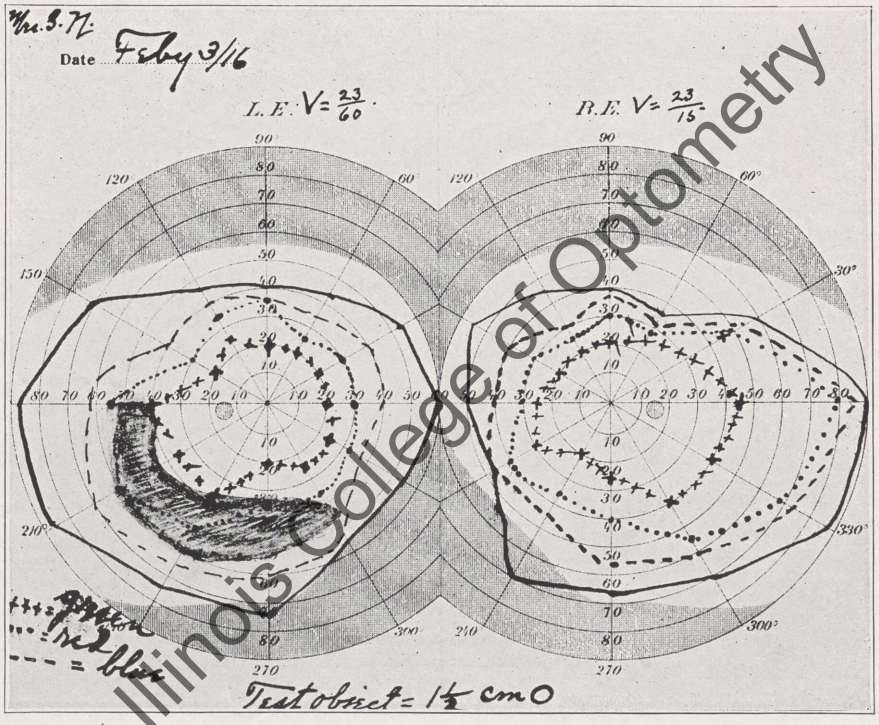

Fig. 165.

Digitized by Illinois College of Optometry

these years she also suffered slow but constant failing of vision in the left eye, until it finally became 23/96. The right eye was normal. She finally realized something must be done in effort to save the vision of her left eye; and consented to the post-ethmoidal-sphenoidal operation.

Very much to my surprise the result in this case was a recovery of vision as well as the relief of headache. Her vision in the left eye became normal at the end of three months.

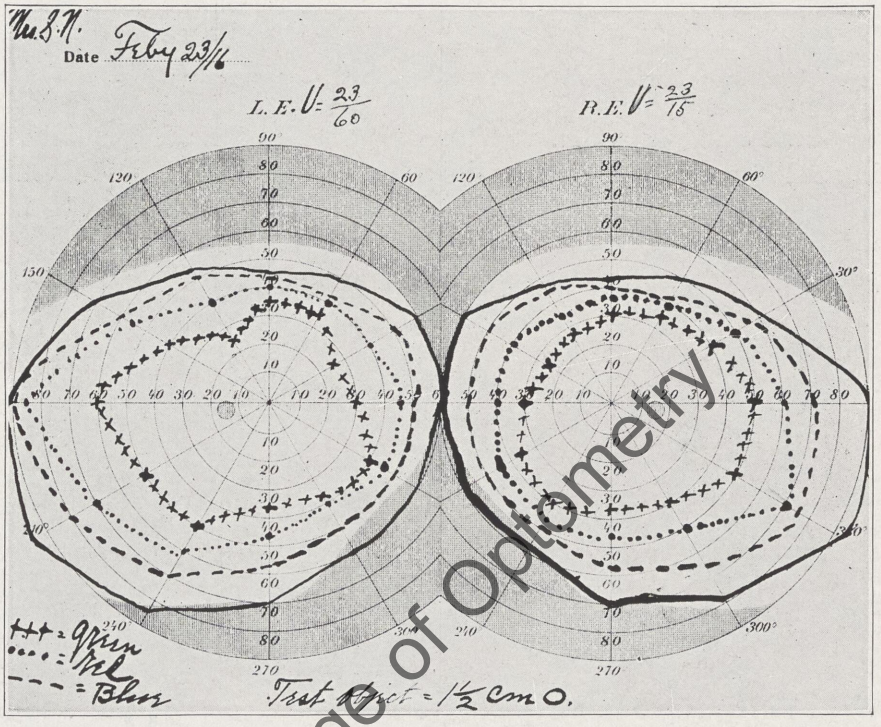

Fig. 166.

It is difficult to understand what may be the process in the optic canal that can, as a result of the sphenoiditis, slowly diminish vision to such an extent over a period of nine years and then recover at the end of three months, after the sphenoid is opened, permitting applications of carbolized oil within it. I have frequently seen in this class of cases patients in whom it appeared as though there was a regeneration of the optic nerve at times.

Digitized by Illinois College of Optometry

The question arises whether in this case there could not have been a regeneration of fiber.

Dr. Charles, who sent the patient to me, has submitted a full report which I herewith attach. This has been one of the most fortunate results of a long experience with such cases.

Mrs. S. N. consulted me Oct. 15, 1907, because her eyes ached and burned constantly, and felt strained in near work.

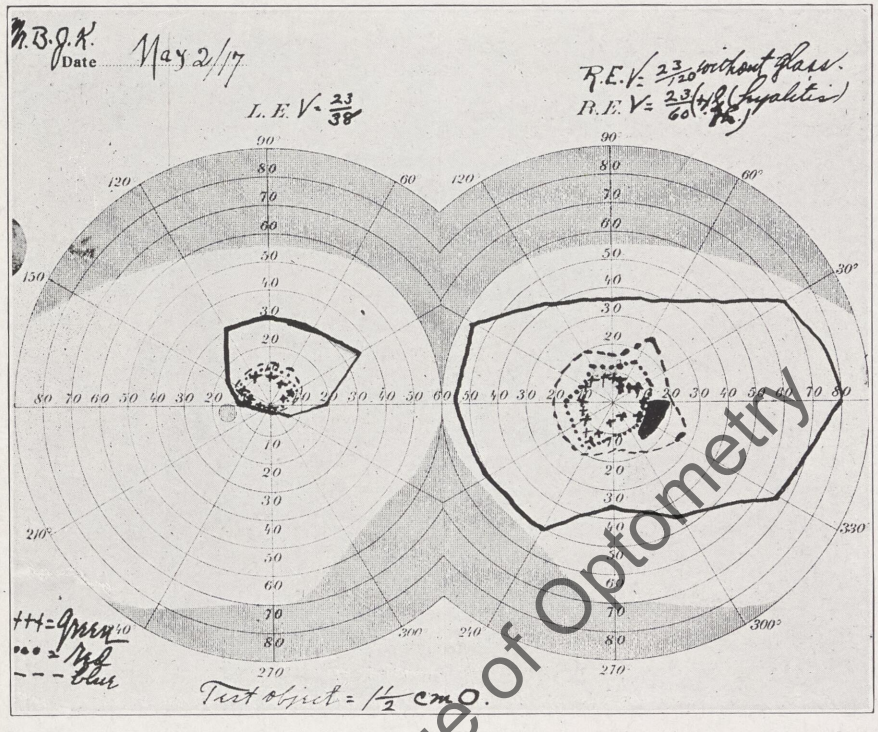

Fig. 167.

She also saw better upon closing the left eye. Dr. Sluder had treated her "four or five" times and had advised an operation. Fundi and pupils were normal. She was given R.E. +2 Sph. +0.5 cyl. ax. horl. V = 19/12. L.E. +2 Sph. +0.5 cyl. ax. vertl. V = 19/48. These glasses proved satisfactory and I saw the patient no more until Feb. 1, 1916, when the left eye had "been failing since summer." (Figs. 165 and 166.) Feb. 3, R.E. V = 23/15. L.E. V = 23/60 Vid. field and scotoma. Feb. 9, 1916,

Digitized by Illinois College of Optometry

with glasses R.E. V = 23/15. L.E. V = 23/96. "Seems to see moving smoke."

April 4, R.E. V = 23/15. L.E. V = 23/60 to 23/38.

The scotoma had disappeared under Dr. Sluder's treatment by Feb. 23, and the fields of vision were much improved in regularity as well as size.

The vision of the left eye has remained at 23/38 and when the patient was last seen in Oct., 1917, she was entirely comfortable.

The nerves and retinae remained normal in appearance throughout, the loss of vision, the scotoma and fields being alone indicative of the involvement of the nerve.

Lifetime Headache with Loss of Vision at 54 Years of Age

Case 82.—W. K., 56 years old, referred by J. W. Charles, March 9, 1914. My diagnosis: Hyperplastic sphenoiditis with scant secretion on right side. States that he has had severe headaches "all of his life" on the right side. In one attack in which I saw him it was of great severity in the temple, about eye, and in the occiput and neck. This attack was accompanied by the loss of 2 letters on the vision test card, yawning, drowsiness and withal a marked restlessness which compelled him to get out of bed in the middle of the night, also by vertigo, nausea, vomiting, pallor and sweat. The next day, the attack being over, the pain sense was still better, right side, but not the sense of taste. He had regained the two letters he had lost. A hyperalgesia right with more acute sense of taste right, after July 7, 1914. Dr. Charles' report: In 1903 he showed a hyperopia, 2d, right eye and 2.5 left eye. Vision 15/7½ right and left. By ophthalmoscope both eyes normal. In 1912 right eye V. 13/40. In 1913 V. 13/50. July 1, 1914, V. 23/192 and some clouding of vitreous. Unusually severe headaches; disc blurred.

July 7, 1914. Post-ethmoidal-sphenoidal operation, after which the headaches *stopped altogether* and his *color* became *normal* (his appearance prior to this was evidently that of a low grade sepsis). Vision August 11, 23/38, the last time he appeared for examination. By telephone he says he is all right and gained 18 pounds, June 1, 1915.

Digitized by Illinois College of Optometry

Beginning Optic Atrophy

Case 83.—O. R., 15 years old, strong, healthy boy, referred by Dr. A. E. Ewing, May, 1911, for beginning optic nerve atrophy, which had lasted one year. My diagnosis: Hyperplastic sphenoiditis, right and left, not far advanced, nonsuppurative. Dr. Ewing's report, vision R. E. 20/192, L. E. 20/150 with small central scotoma right. Right eye showed narrow pigmented crescent to temporal side of disc and more to temporal side; no headache. He was given a 2½ per cent alkaline saline solution to pour into nose 3 times a day with a phenol spray. In 5 months he showed V. 20/60 right and left, two eyes 20/38. I have had a similar case with Dr. Ewing in a woman 72 years of age.

High Grade Hyperplastic Sphenoiditis—Blindness

Case 84.—E. H. G., 30 years old, consulted me September 21, 1916, referred by Dr. J. F. Shoemaker. He had an optic neuritis. His vision had been failing three weeks, the left more than the right. At that time the vision on the right side was 13/100; the left 3/200. Examination showed a very high grade hyperplastic dry post-ethmoidal sphenoiditis. He never had had headache. Tentative treatment failed; and on September 22, 1916, the left sphenoid was opened. It was found to be a subdivided cavity, one cell above the other. The bone was very thick and very hard.

The operation made no improvement in the eye condition. A short time later the cavities closed up. They were reopened, with no benefit for his eye. The right sphenoid was opened October 12, 1916.

The material from this case submitted to Dr. Wright for examination especially engaged his attention. He has submitted a full report in Chapter II.

This is a case which, it seems to me, demonstrates that when the hyperplastic bone process is of high grade, such as this, we fail to get the result for the eye.

I have record of many others, where the whole hyperplastic process in the soft parts and in the bones both were of much lower grade, with perfect results. His was the hardest, thickest bone that I have encountered at the primary operation.

Digitized by Illinois College of Optometry

I have operated upon patients who have been operated upon before, either by myself or by other surgeons, in whom the bone formation was hard and the case was handled with difficulty.

In one such case I found the bone so thick and hard that it could not be penetrated by the little angle knife which I usually use.

That was a headache case without eye involvement. The fact of this case being a total failure for the relief of the eye trouble in any degree, seems to me to follow merely the pathological findings delineated by Dr. Wright.

Every possible line of investigation, clinical and laboratory, for this patient was negative, including a spinal fluid Wassermann reaction.

I have another case, male, 52 years, referred by Dr. V. P. Blair, corresponding with this in all particulars in which there was no eye involvement but great lower half headache. Opening the sphenoid did not help the patient.

Optic Neuritis

Case 85.—V. S., age 22, was sent to me by Doctor Adolph Alt in 1914. He had a low grade optic neuritis of recent origin. Examination of the nose showed a hyperplastic sphenoiditis, low grade with an acute process engrafted on it. Forcible injections of carbolized oil to the olfactory fissure began to help at once. In three weeks the optic neuritis had subsided and his eye was normal again and since that time there has not been another attack. The case is interesting to me, showing how sometimes an excellent result is obtained for small effort.

Optic Neuritis

Case 86.—E. D. Strong, healthy man, 24 years old, referred by Dr. John Green, Jr., and Dr. Louis Hempelmann. My diagnosis: Hyperplastic sphenoiditis with subacute suppuration. Dr. Green's report: "Seen first Feb. 20, 1914. Right vision 6/5; left vision 6/5. For five years complained of lower half headaches and *temporary blind spells.*

"Ophthalmoscope showed: right, mushroom-like swelling of disc with swelling starting abruptly at margin and mounting up. Margins very much veiled, veins a little dilated and tortuous.

Digitized by Illinois College of Optometry

Apex of disc measured by C D. Refraction about 2 D., so that disc swelling amounted to 4 D. Left same appearances. Disc. measured by 6 D. Retinal level by 2 D. Swelling = 4 D.

"Subsequent observation showed slightly greater swelling in right than left disc; no evidence of choroidal change or of peripheral retinitis. Fields show slight peripheral contraction of right with inversion of red and green fields. On left form field full, blue field contracted, green field larger than red but interlaces in three meridians. Conspicuous clinical feature of the case is the momentary obscuration of vision followed by rapid restoration. Patient closely followed, vision never got lower than right 6/8+. Left 6/5.

"March 6th: The day following opening of right post-ethmoidal-sphenoidal cells, vision was raised from 6/6 to 6/4 with the right eye.

"March 12th: Day following operation on left post-ethmoidal-sphenoidal cells, vision was raised from 6/4 missing 2 letters to 6/4 missing 1 letter.

"April 10th: Distinct recession of papillary swelling; right apex measured by 4½ D., and left apex by 5½ D. From this time neuritis slowly subsided.

"November 6, 1914: Both discs were at level of retina and fairly well tinted.

"Last observation July 12th, 1915: right and left vision 6/4; fields full. Both discs a little pale but showing no other evidence of antecedent inflammation."

Clinical course: Post-ethmoidal-sphenoidal operation, right side, March 5, 1914. Left side, March 11, 1914. Eyes began to improve almost at once (see above, Dr. Green's report). Six days later lower-half headache (maxillary and Vidian neuralgia) began to lessen and later ceased. July 27, 1914, a coryza caused headache and some increased disc swelling and a paresis of the facial nerve of right side. This diagnosis was confirmed by Drs. Hempelmann and M. A. Bliss. This condition lasted 7 days. August 13, 1914, began another exacerbation of the local inflammation and was followed by vomiting for 36 hours with some headache. August 27, 1914, appeared a paresis of the left facial nerve with a right-sided exophthalmos (Drs. Green, Hempelmann and Bliss). Intrasphenoidal observation with Holmes'

Digitized by Illinois College of Optometry

pharyngoscope during these periods confirmed the diagnosis of acute exacerbation. By the same means it was known to have been absent before and proved to be absent later (after 14 days) when recovery of eye, facial paresis, and exophthalmos was established.

Last observation by me April 10, 1915, confirmed Dr. Green's of November 6, 1914, of recovery. The clinical changes in the sphenoidal district had subsided to such a degree as to leave it normal clinically. In the first eighteen months he has had for the first time two epileptic seizures.

Dr. Wright has reported this case in full in Chapter I.

This case is in marked contrast to Case 13, page 329, the pathological changes in which are also given in detail by Dr. Wright in Chapter I. The hyperplastic process in Case 13 was the most marked of all the cases. Surgically the bone was heavier and harder than any of these cases with one or two exceptions which were equally hard. The result in Case 13 was a failure as far as the eye was concerned. The process in this case showed a rarefying state of the same lesion. The result was all that could have been desired. What the significance of the recently developed epilepsy may be cannot at present be stated.

Optic Neuritis

Case 87.—L. W., 25 years old, consulted me Jan. 16, 1913, because of great headache, lower half, which she had endured for six years. She had been in the charge of various physicians, some of them rhinologists. Someone had opened the capsule of the ethmoid on the left side. Examination revealed a high grade hyperplastic post-ethmoiditis; and it was my judgment to open the post-ethmoidal-sphenoidal district. The left pupil was frequently larger than the right. The right and left post-ethmoidal-sphenoidal operations were done in October and December of 1913.

She was somewhat slow in getting any results from the surgery. The bone was intensely hard and with great difficulty cut through by means of the little angle knife described in the foregoing text. I succeeded very satisfactorily, however, in opening the sphenoidal cell proper.

Digitized by Illinois College of Optometry

Because of the delay in receiving benefit from the surgery, I decided to investigate the subdivision of the sinus and placed a probe in its uppermost limits for an x-ray picture. It showed a small cell above the one opened. I then attempted to open this cell. I succeeded in entering, through very hard bone, a small cell in the upper outer part of the sphenoidal face, the opening remaining.

Since that time she has been frequently free from pain for long stretches, six to ten weeks.

The case for the past year has been greatly complicated by a bad dysmenorrhea. When this patient menstruates, almost every time it is a major illness, and she does not recover in the three weeks' interval from what she loses during the one week in which she menstruates.

In this way she has slowly lost ground, and much of the time suffers intense headache, particularly during the menstrual period.

In an effort to exclude all possible influences that might bear upon this unfortunate case, she was put into the Barnes Hospital, and a complete gynecological and neurological investigation carried out by Doctors Schwab, Sachs, and Taussig, and complete x-ray investigation for everything possible; and all the laboratory tests that are at the present time deemed to be serviceable in the elucidation of such a case, were employed.

In the course of this investigation, Dr. Meyer Wiener discovered that she had a slight neuritis of the right optic nerve. He found the lower inner margin of the right disc slightly blurred; the veins normal in color, size and contour; arteries slightly more tortuous than usual; refraction in +1 diopter; fields of vision show no abnormality; the blind spots, however, not outlined.

Patient since the last note has been constantly in ill health. The severe dysmenorrhea has continued. Gynecologists have attempted to relieve the dysmenorrhea by dilatation of the cervix, and finally by radium set into the uterus. The reaction to this was very severe and it did not improve matters. I have one note that I feel should be reported. December 7, 1919, she developed a slight acute sore throat. The next day vertigo shifted from side to side and was so severe that any position except

Digitized by Illinois College of Optometry

that of flat on her back was impossible and was immediately followed by repeated purposeless vomiting. Intrasphenoidal cocainization stopped all of this in fifteen minutes, and six hours later there had been no return. I have not seen this patient for two years, so I cannot bring the report up to date. Her life is, however, a wreck. She has a combination of something that seems to be a nasal and menstrual disturbance.

This case to me is intensely interesting, not only showing the influence of menstrual disturbances, which have intensified the headache very much, but, in the course of the routine investigation was discovered an optic neuritis of such low grade that it had not announced itself ophthalmologically. It raises the question in one's mind as to how often these patients suffer more or less eye disturbance. I mean by that optic nerve or choroidal disturbances that are not recognized clinically. They do not attract the patient's attention, and they are therefore not submitted to the ophthalmologist. The attacks of transitory blindness which I have recorded have so often seemed, for the most part, to have been a manifestation—probably a toxemia of the nerve by juxtaposition of the sinuses, which has not registered a visible lesion.

Acute Blindness

Case 88.—Mrs. J. D., 38 years of age, referred by Dr. W. E. Shahan, June 21, 1914. Diagnosis: Hyperplastic sphenoiditis with acute suppuration. Dr. Shahan's report: June 12, 1914, was seized with violent headache left side, which lasted five days when it began to subside and the vision of left eye began to fail. Now counts fingers at one foot. Lower and central field absent. Disc appears slightly swollen and slightly hyperemic at upper margin. Right eye normal.

June 24, 1914. Post-ethmoidal-sphenoidal operation. Dr. Wright's report: Sphenoidal wall—marked hyperplasia of the bone and the periosteum is markedly infiltrated with products of inflammation in some parts. Some areas of the mucous membrane show marked adenomatous hypertrophy with subepithelial edema. The changes in the soft parts are of a chronic nature, probably a very old process in the mucous membrane.

Digitized by Illinois College of Optometry

Middle turbinate—the surface epithelium is papillary and thickened. There is a very great amount of edematous infiltration of the subepithelial connective tissue. The lymph channels are enormously dilated in it. The blood vessels are not markedly involved. The mucous membrane shows evidence of marked chronic inflammation, long continued and still quite active and there is a great amount of inflammatory change in the bone.

Clinical result: In 9 days after operation, vision 3/30; no headache. In 20 days, V. 20/38. In 35 days, 20/19 and normal field; no headache.

March 22, 1915, V. 20/19 both eyes.

Acute Post-ethmoidal Blindness (Sluder[71])

Case 89.—W. H., 20 years old, strong, healthy man, referred by Dr. W. H. Luedde, July 22, 1907. My diagnosis: Acute suppurative post-ethmoiditis with edema. He had presented himself to Dr. Luedde that day, saying that "three days ago the present trouble began with a sharp pain in right eye; 12 hours later a slight swelling appeared around this eye which lasted 12 hours. The pain continued until today." This morning at 7:30 both eyes became blind. The left eye remained blind about 25 minutes. The right eye can see direction of motions of hand 3 feet, vision of left eye 15-19 by artificial light. Examination showed the right upper meatus of the nose swollen shut and pale (edematous). No pus could be discovered. Effort was made to shrink away the swelling, which was only in small part successful. He was placed in St. Luke's Hospital and the effort repeated at midnight, unsuccessfully. It was repeated at 6 A.M., July 23, 1907, and followed by the discharge of about a teaspoonful of pus into the throat. Three hours later (9 A.M.) he reported to Dr. Luedde, who found the vision, right eye 15/19, left eye 15/12. The discharge of pus continued intermittently, stopping in ten days. It always appeared between the middle and upper turbinates. Never did any appear in the recessus sphenoethmoidalis. Four days from the beginning of the treatment the right upper meatus swelled shut again for a few hours (about six hours) the pain recurred to a slight degree and his vision in the right eye fell temporarily from 15-12

Digitized by Illinois College of Optometry

to 15-24 for this length of time. From the tenth day he remained normal in every way and continues so at present.

Failing Vision—Tabes

Case 90.—Mrs. C., aged 40 years, sent to me by Doctor A. E. Ewing, June 3, 1913, because of failing vision. She had a bilateral sphenoiditis.

Investigation at that time showed a well-defined tabes, but it was determined to open the sphenoid cells, despite this fact. No benefit was derived from this operative procedure.

I had another case exactly similar in every respect, also referred by Dr. Ewing. A man 70 years of age, who was not operated upon, because of his advanced years, to whom treatment was given;—forcible filling of the olfactory fissure with carbolized oil. In three months his vision improved markedly despite the fact that he had a well-defined tabes. These cases show the difficulty in separating the causes of eye lesions in the presence of sphenoiditis.

Operative Injury of Optic Nerve

Case 91.—Miss B. C., a trained nurse, consulted me April 29, 1918, referred by Doctor Ewing, she being a patient of Doctor Sauer, who kindly permitted my examination. She gave a history that she had some headache and eye disturbance a year prior, when one of her acquaintances proposed to operate upon her nose. She was put under ether and the operation performed. When she came out from the ether she was totally blind in the right eye. Great hemorrhage filled the right eye socket. Doctor Ewing reported that the retinal arteries appeared as white silk threads, an appearance which he was somewhat at a loss to explain. To me the case seemed to have been one of those great misfortunes in which the optic nerve was cut direct. The posterior third of the middle turbinate remained *in situ,* apparently no sphenoidal post-ethmoidal surgery was done. The surgeon seemed to have lost his way, probably under ether, combined with blood. I say that it was probably a direct cut of the optic nerve because five times in my own experience it has happened that the capsule of the ethmoid or the body of the sphenoid has sustained some small injury which has resulted in orbital hem-

Digitized by Illinois College of Optometry

orrhage; four of these cases showed a small ecchymosis, one of them, however, was accompanied by great exophthalmos. The condition subsided in three days with no impairment of vision and no fault in any way to be found with the result. Sixty-one times I have had orbital phlegmons to treat, about 50 per cent of which have been back of the transverse meridian with great swelling and high grade exophthalmos. In none of these cases was there any loss of vision. The results gave a perfect eye.

Optic Neuritis—Operative Disaster

Case 92.—A healthy boy, W. K., 20 years of age, began to lose vision two weeks prior to consultation with me. His ophthalmologist recognized an optic neuritis of 3 diopters swelling. Nasal examination showed a subacute sphenoiditis with very scant secretion. The proposal was made to open the sphenoid at once; but he declined stating that he did not care to remain in the city. His physician took him away; and the next day operated, removing the middle turbinate and proceeding backwards in the effort to exenterate the post-ethmoidal-sphenoidal cells. He succeeded in opening the post-ethmoidal district quite well, but he some way failed to open the sphenoid and two weeks later brought the boy back. His vision upon the first visit was 20/30. Upon his return he had only the perception of light. Upon the second visit the sphenoid was opened comprehensively. Vision slowly returned. In three months it became normal. The case is of interest to me showing how the surgery of this district in order to be successful must be right.

Neuroretinitis

Case 93.—R. B., strong, healthy man, 21 years old, referred by Dr. H. S. Hughes. My diagnosis: Hyperplastic sphenoiditis, nonsuppurative. Dr. Hughes' report: July 20, 1914, patient said his vision was normal, that he never had any eye trouble until one month previously, when he noticed the small prints seemed blurred and that he could not do his work with facility. No other especial low grade headache. General history, practically negative. Denies luetic history or any other trouble of a general nature. Smokes little, about one package of tobacco a week. Does not drink to excess. External eye, normal. Vision

Digitized by Illinois College of Optometry

R. E., 6/12; L. E., 2/50 not improved with glasses. Ophthalmoscope, L. E., nerve head seems hazy in outline throughout; disc margin being completely lost from 5 to 8 o'clock. Temple quadrant is distinctly pale. At the lower nasal quadrant are several very minute hemorrhages. The macula region looks hazy and slightly edematous. The retinal vessels at lower disc margin similar to that found in left, except very much less pronounced. Optic nerve pale. August 4, 1914, Dr. Gradwohl reports negative Wassermann but a positive Hecht-Weinberg. Fields for form show concentric contraction varying from 20 to 40 degrees. Diagnosis: Neuro-retinitis; patient placed upon energetic alterative treatment, supported with strychnia. Vision R. E., 6/40; L. E., Fings. 1M. July 29, 1914, Dr. Sluder opened left sphenoidal sinus. August 4, 1914, vision R. E., 6/50; vision L. E., Fings. 1M. Accurate fields difficult to take. October, 1914, R. E. Fings. 2M. This is the last visual record I was able to take of the patient. Subsequent letters from his family's physician at Springfield, Mo., would indicate that his vision for several months following the above date remained about the same.

August 7, Dr. A. E. Ewing saw the patient in consultation. Dr. Ewing's opinion substantiated my own as regards diagnosis and treatment. He did not think there was any indication for specific treatment but suggested that the nasal treatment be continued.

Post-ethmoidal-sphenoidal operation, July 29, 1914.

Dr. Wright's report of changes in the sphenoidal wall and middle turbinate reveals a moderate degree of hyperplasia of fibrous connective tissue beneath the epithelium and moderate hyperplasia of the bone.

I know of no particular reason for the total failure to improve this patient.

Paralysis of the Trochlearis with Dilated Pupil

Case 94.—Miss M. R., 21 years old, consulted me March 24, 1912, because of mild posterior headache with dilatation of the pupil on the right side, accompanied by discomfort in use of her eyes, of one week's standing. Ophthalmological examination was negative. An upright rod appeared to her bifurcate below,

Digitized by Illinois College of Optometry

which, I understand, indicates a paresis of the superior oblique. The anterior wall of the right half of the sphenoid was reddened and bathed in serum. An effort was made to fill the sinus with 1½ per cent aqueous solution sodium salicylate. This was repeated three times in nine days, when she was free of all signs and symptoms, and remained so for ten days, when she had a "sick headache" (in which I did not see her) and again had a dilated pupil which became normal when the headache stopped. No discernible cause could be assigned for the sick headache.

Paralysis of Accommodation

Case 95.—H. S., 35 years old, large, very strong, healthy man, referred by Dr. F. L. Henderson, November 25, 1914, for complete paralysis of accommodation left eye of six months' standing. He had a sphenoiditis of low grade with moderate hyperplasia and very scant mucopurulent or mucous secretion. Post-ethmoidal-sphenoidal operation November 30, 1914. Accommodation began to return one month later and in three months had returned complete.

Third and Sixth Paralysis—Ophthalmic Migraine

Case 96.—A. A., 22 years old, normal, referred by Dr. A. E. Ewing, October 6, 1914. My diagnosis: Sphenoidal suppuration, right. Dr. Ewing's report: The young woman, 22 years of age, a week previous to the examination noticed that everything appeared double, with considerable headache. At the time of the first examination, October 2, the vision in the right eye varied from 20/38 to 20/24; in the left it was 20/20. In the right eye the vision could be improved to 20/20 by a weak concave lens. The muscular disturbance consisted of a slight nystagmus when looking strongly upward or downward. On the 6th there was positive restriction in the motion of the right eye outward and a diplopia which was corrected by a prism of 25° base outward over the right eye; left, 20/24; fields normal; each fundus normal. The nasal examination, made the same day, revealed suppuration from the right sphenoidal sinus. Two days later this sinus was opened. On the 26th the recovery had so far progressed that the diplopia was corrected by a prism of 7° base outward O. D.; the vision had risen to 20/20, and was

Digitized by Illinois College of Optometry

the same with +0.37 sph. Three weeks later binocular vision had become reestablished and the eyes were used freely and comfortably, the vision in each eye being 20/20+ without glasses.

This case is of especial interest because of the diplopia that was at first indefinite, the lowering of the vision in the right eye, the accommodative spasm and the nystagmus in extreme upward and downward exertion, all of which combined was evidence of a slight general oculomotor and optic nerve toxemic involvement. Later the abducens became most affected, probably by reason of gravity of the toxic substance and because of proximity to the infected region, the abducens being the lowest of the oculomotor nerves in their passage through the sphenoidal fissure, and nearest to the post-ethmoidal and sphenoidal sinuses, as well as nearest to the sphenoidal sinus in its course over the clivus and around the posterior clinoid process of the sphenoid after its exit from the dura mater.

In addition to the actual lesson taught in this instance, there is another presumable one, which is, that many of the hysterical amblyopias and many of the temporary indefinite muscular anomalies and obscure disturbances of the accommodation ordinarily accredited to hysteria, may really be toxemias due to nasal infection. This case corresponds to the ophthalmoplegic migraines.

October 8, 1914, post-ethmoidal-sphenoidal operation. Dr. Wright's report of changes in post-ethmoidal-sphenoidal wall: The mucous membrane of the sphenoidal wall in this case is the site of some fibrous hyperplasia and of some edema. There are small patches of connective tissue in which this hyperplasia is quite marked around moderate-sized arterioles. There does not seem much bone change.

Turbinate: This consists of edematous connective tissue beneath the epithelium which is not altered much. The veins and venules are dilated and full of blood and serum, but their walls are not markedly thickened. The acini of the glands are somewhat dilated. There is not much production of new connective tissue nor bone lesion. The case is evidently one of subacute inflammation.

The wound was uneventful in healing.

Digitized by Illinois College of Optometry

In this patient the process had lasted probably only a short time. The status of October 6th was precipitated by an acute or subacute inflammation upon the older process.

Sphenoidal Headache with Drooping Eyelids

Case 97.—G. H., a normal man, 50 years old, referred to me by Dr. W. E. Fischell, 1901. He had a chronic eustachian tube obstruction for which I did a posterior cautery operation in 1902 with complete relief. In 1910 he suffered from a severe right post-ethmoidal-sphenoidal suppuration with lower half severe headache. It proved to be obstinate and Feb. 26, 1910, the post-ethmoidal-sphenoidal operation (right) was done. It relieved the headache. From time to time he has had coryzas which cause slight transitory headache, that cease with recovery from the coryza. May 7, 1918, he again developed a severe coryza accompanied by an unusual phenomenon; to wit, a violent stabbing pain which pierced his right eye during sleep. It awakened him on two mornings at 3 A. M. and continued through the days in slight degree despite acetphenetidin gr. v and codeine gr. ¼ every 3 hours. Examination showed acute inflammation of the right post-ethmoidal-sphenoidal district. Cocainization of the nasal ganglion stopped the eye pain.

He rarely has had headache since. On November 20, 1922, he consulted me because of sphenoidal headache of great severity, right side, with a drooping eyelid which closed two-thirds of the opening.

Glaucoma and the Nasal Ganglion

Case 98.—Mr. R., age 50 years, consulted me the June of 1913, referred by Doctor Ewing, complaining of great pain in the eye which had been lost by glaucoma. The conjunctiva was greatly swollen, red and the eye socket appeared to be fuller than the opposite fellow. Complete anesthesia of the nasal ganglion relieved the pain. This was carried out daily for three weeks, at the end of which time the swelling of the conjunctiva and its redness and all of the pain in his eye had subsided. His eye looked at that time like the eye of the opposite side—normal. This case is to me exceedingly interesting showing the power exerted over the eye from the nasal ganglion. Whether

Digitized by Illinois College of Optometry

this be a trophic influence or whether it be the result of the control of pain is to me very difficult to decide. I am undecided as to which it is. It would appear, every now and then, that the influence is a trophic one. The cocainization of the ganglion in this case was accomplished first with a drop of 90 per cent solution which was afterwards reduced to a daily application of 20 per cent. It is impossible for me to conceive of this case as being influenced through the lymphatics, that is, the infection; or assuming that the infection is controlled by way of this channel. Many times have I obtained a most beneficial result for the eye condition where the ophthalmologist was having a hard time to control a bad iritis. Complete anesthesia of the nasal ganglion has stopped the pain and the iritis has repeatedly improved from that time on. The lesion within the nose in these cases has been almost uniformly a thick velvet-like swelling of the posterior tip of the middle turbinate and just above it, that is, a hyperplastic post-ethmoidal inflammation. The application of this small amount of cocaine to this district does not seem possible to me to have any controlling power over the infection.

Transitory Amblyopia

Case 99.—Mrs. C. S., aged 25 years, consulted me February 20, 1903, for an acute pan-sinus suppuration with general headache. Prior to this attack she had very rarely in her life been sick in any way. She did not remember ever having had a bad headache, and she had always been strong. She has done hard work (shoe machine) since her nineteenth year. Since this attack she has had, up to the present time (nine years), a recurrent headache that seldom skips more than ten days. Much of the time it is frontal, sometimes maxillary, and often intense combined with occipital pain. It is worse at night and during menstruation. Meanwhile I have opened the frontal sinuses and antra and ethmoids and sphenoids, and done everything known to possibly help (contacts, etc.). I have from time to time put her in charge of specialists in all the departments of medicine, who have found her normal, save hyperopic astigmatism, for which she wears glasses. November, 1911, I proved that her trigeminus was easily accessible (intrasphenoidal) on both sides.

Digitized by Illinois College of Optometry

Since then I have filled the sphenoid once in ten days with 1 per cent phenol in oil. She says that this is the first medication to relieve her pain.

All characteristics of a nose case disappeared from this patient by the end of the first three months.

In 1918 she developed a transitory amblyopia at the height of the headache which developed from a coryza.

December 15, 1921, she suffered from severe acute coryza, slight cough, no visible sore throat, moderate asthma and rhinorrhea, with lacrimation and congested red eyes which appeared a little more prominent than usual. Intrasphenoidal cocainization restored normal appearance and feeling and stopped the asthma.

Transitory Amblyopia

Case 100.—Mrs. A. A. B., 30 years old, consulted me October 1, 1917. She had had for six months, great swelling, sneezing, watery discharge, with tearing eyes and intense headache, chiefly posterior, accompanied by a transitory heavy gray mist, appearing before her eyes, and lasting for periods of twenty minutes to an hour almost every day. Ophthalmoscopic examination by Dr. F. L. Henderson was negative. Examination showed a gray spot in the sphenoethmoidal recess, right and left, at the site of the sphenoidal opening, with a distinctly enlarged and inflamed posterior tip of the middle turbinate on the left side (hyperplastic post-ethmoiditis), with acute process added on. The gray spots were the outlets of the sphenoidal sinus, and probably a trace of secretion which was not perfectly clear.

The effort of tentative treatment failed so the post-ethmoidal-sphenoidal operation was performed on the left side. The nose was very tall and very narrow, and presented a technical difficulty probably as great as such noses ever present.

The result was that the headache stopped at once and the "blind spells" also stopped and have not returned to date.

Clinically, the case appeared to be a low grade hyperplastic post-ethmoidal sphenoiditis, with a low grade subacute inflammation added to it.

The case is interesting, combining headache with a transitory appearance of mist or steam which she described as blind-

Digitized by Illinois College of Optometry

ness. No ophthalmoscopic explanation for this could be found. I have seen this phenomenon often develop after the condition was of several years' standing. The secretion and probably the tearing and sneezing were manifestations on the part of the sympathetic fibers of the Vidian nerve.

Photophobia

Case 101.—R. A. G., aged 40 years, school teacher, normal man, was sent to me by Doctor A. E. Ewing, because of photophobia that was not explained by any ophthalmological condition.

Examination revealed a well-marked hyperplastic post-ethmoidal sphenoiditis.

Effort to control the photophobia from the nasal ganglion was not successful. The treatment by forcible injection of carbolized oil into the sphenoidal district was rapidly followed by cessation of the photophobia. The patient has remained a year now in comfort. It is of interest as one of the more unusual ocular manifestations, apparently produced by an inflammatory lesion in the post-ethmoidal-sphenoidal district.

Nasal Ganglion—Photophobia

Case 102.—Mr. A. B. C., age 30 years, became my patient September 28, 1914. He had a nasal obstruction which was relieved by some applications of silver to his nose. December 16, 1914, he returned complaining of nasal obstruction for which a left side galvanocautery operation was done. May 1, 1915, the right side was done. In 1918 he began to have a lower half headache which yielded easily to applications of two per cent silver to the sphenopalatine foramen. The headache was rarely severe enough to warrant cocainization of the ganglion. Since that time he has appeared at rather long intervals for a few applications of silver or mercurochrome. On September 27, 1919, he had the unusual symptom which prompts this report, pain in his eyes which he referred in some way to his pupils. In all probability it was a photophobia. It was relieved by cocaine to the ganglion. At that time he had no other symptom although he had had all of the various pains of the lower half headache from time to time.

Digitized by Illinois College of Optometry

Lower Half Headache—Suppurative Sphenoiditis

Case 103.—Miss M. B., age 16, came to me January 29, 1918, with the complaint that she had had headache, left side, more or less all her life. The headache had always been bad but lately it had been getting worse. She had a left-sided sphenoidal suppuration with considerable inflammation. I opened her left sphenoid March 26, 1918, and the body of the sphenoid was occupied by two cells, one of which was a post-ethmoidal cell. The particular feature of this case is that during the acme of her attacks all things looked red. November 11, 1918, since operation, headache is much better and colors are normal. At least there is no red.

Nasal Ganglion—Photophobia

Case 104.—H. G. L., 13 years old, small boy, under strength. Consulted me November, 1914. He had a profuse rhinorrhea with great morning sneezing, accompanied by great morning photophobia and moderate *exophthalmos*. He had a high grade hyperplastic sphenoiditis. Sometimes he had slight asthma. Treatment of his nose has thus far relieved the photophobia and nearly all the sneezing. His eyes are in what seems to be normal position in his sockets.

Scotoma Scintillans

Case 105.—F. L. H., aged 50 years, consulted me in 1905 because of severe headache that kept him awake, usually sitting up, through six nights out of the week.

Examination showed an intensely inflamed post-ethmoidal-sphenoidal district, without hyperplasia or pus.

Treatment of his nose helped little or none. He was placed in the charge of all varieties of specialists of the first rank in all parts of the country. All manner of diet was instituted, and every investigation that modern laboratories are capable of making was exhausted. He finally became so bad that he consented to the post-ethmoidal-sphenoidal operation, which was done in 1909 on the right side.

It afforded sufficient relief to permit of his attending to his arduous duties, the headache rarely being so bad that he was helpless from it. Much of the time he was free of pain alto-

Digitized by Illinois College of Optometry

gether. A coryza uniformly caused very considerable pain for him.

This patient, aside from the headache, at the greatest intensity becomes blind, develops a scotoma scintillans, which incapacitates him totally.

This is in great contrast to Case 62, in which the type is that of pure ophthalmic migraine, which *begins* by scotoma scintillans.

Lower Half Headache and Blepharospasm

Case 106.—Mrs. A. B. D., a healthy young woman, 25 years of age, complaining of the lower half headache described above, and at the same time complaining of an intractable blepharospasm, with great lacrimation.

Examination revealed an inflamed district about the sphenopalatine foramen. Injection of the district stopped the pain, relieved the blepharospasm and the lacrimation.

The patient has been free of pain, lacrimation and blepharospasm for thirteen years.

Hyperplastic Sphenoiditis—Blepharospasm

Case 107.—L. A. B., 52 years old, consulted me December 7, 1915, at the suggestion of Dr. John Green, Jr., for severe blepharospasm and lacrimation which had existed 8 months. He also showed a few slight opacities in the vitreous. Ophthalmological treatment by Dr. Green failed to control the spasm. Nasal examination showed a hyperplastic post-ethmoidal-sphenoiditis, without secretion. Experiments proved that cocainization of the ganglion stopped the blepharospasm. This was repeated many times. Finally, it was decided to inject the ganglia. February 22, 1916, the right ganglion was injected with cessation of the blepharospasm in both eyes to a large extent. March 6, 1916, the left ganglion was injected with total comfort and relief.

This patient did not have headache at any time of his life that he remembered. He showed a definite hyperplastic ethmoidal sphenoiditis localized about the sphenopalatine foramen. It would have been impossible to have connected his case, that is, of cause to effect, had it not been that I had three times

Digitized by Illinois College of Optometry

seen marked blepharospasm accompanied by lacrimation and *lower half headache.* The headache was the index to the cases. The ganglion was injected because the headache was controlled from the ganglion. In these cases the blepharospasm and lacrimation were incidentally relieved with the headache. I therefore put this case to the test of nasal ganglion cocainization and, to my surprise and delight, found that it controlled the spasm.

Although there were no other manifestations of a nasal ganglion neurosis, the anatomical lesion at the proper site accompanied by the control of cocainization gave me the idea that the injection of the ganglion would give the desired result.

He has now survived three severe coryzas without return of the spasm. The hyperplastic post-ethmoidal sphenoiditis as the result of the injections has involuted to such a degree as to be scarcely recognizable at present. His vision, which was not quite normal before, has returned to normal.

Post-ethmoidal-sphenoidal Suppuration—Blepharospasm

Case 108.—F. B., 38 years old, consulted me Nov. 1, 1917, sent by Doctor F. L. Henderson, who had exhausted all means known to him for the relief of a right-sided blepharospasm of great severity. Examination revealed a post-ethmoidal-sphenoidal suppuration, with polyps on the right side. Experiment showed that cocainization of the right nasal ganglion opened his right eye and relieved the blepharospasm for a period of three hours.

It was therefore decided to inject the nasal ganglion of the right side. This was done three times, and was followed by relief of the spasm for three to six hours.

The right post-ethmoidal-sphenoidal operation was performed Dec. 21, 1917, and also relieved the spasm for a few hours. Treatment of the sphenoid cavity was followed by the cessation of the suppuration, and disappearance of the polyps; but the blepharospasm remained. Intrasphenoidal cocainization relieved the spasm for three to six hours.

The results were unsatisfactory, at least for relief of the blepharospasm, so I decided to open the sphenoidal cavity of the left side. I decided this because I remembered that nobody could tell about the subdivision of the sphenoidal body

Digitized by Illinois College of Optometry

prior to opening it, and not always then, without x-ray plates with probes *in situ*. I believed that the irritation might come from the left sphenoidal sinus.

Prior to this, the experiment with the left nasal ganglion was performed, and was found to give longer relief from the spasm than had the right nasal ganglion or the right sphenoidal sinus experiment.

I then elected to inject the left nasal ganglion. This has been done twice, with transitory relief.

April 20, 1918, I opened the left post-ethmoidal-sphenoidal cells. The blepharospasm is unchanged.

This case is exceedingly interesting, bringing up the question of the path of the impulse which may set off the blepharospasm.

I had assumed that it was sent through the great superficial petrosal from somewhere—the seventh nerve, possibly, or the geniculate ganglion; but that it would be of the same side. The fact that the injection of the left ganglion opened the right eye is, to my mind, not to be explained at present.

This case is of great interest in connection with cases, Nos. 106 and 107, in which pronounced blepharospasm was relieved, one associated with the lower half headache, the latter having the spasm alone, without headache, and in both eyes. As I look back over this record I note with more attention than was given in the beginning, the fact that the injection of the first ganglion opened both eyes, to a very great extent. The treatment was not completed, however, until the second ganglion was injected.

Nasal Ganglion—Blepharospasm

Case 109.—Mr. G. M. L., lawyer, 35 years old, strong and in every way normal man. I should classify this patient as unusually "normal"; beside physical well-being he has no idiosyncrasies known. He is not sensitized along any line now known. He does not have hay fever or horse asthma. He consulted me December 15, 1914, for what he said was the "worst cold" he had ever had, of three days' standing. He did not have headache, but his mental processes were so slow, together with such a tendency to confusion that he was unable to do his work in the courts with justice to himself or client. He complained also of

Digitized by Illinois College of Optometry

weariness but did not feel sick enough to take to his bed. Examination showed a pronounced post-ethmoidal-sphenoidal suppuration right and left. Anterior two-thirds of nose normal. He responded rapidly to acetphenetidin internally and local cleansing and draining. In five days he said he felt well enough to go into court again, and he did so, everything being satisfactory. I did not see him again for two weeks, when he again presented himself for examination, saying he felt well. The evidence of the local trouble had nearly disappeared. I asked him to return again for examination in three weeks and to continue the use of his cleansing nasal solution. In two weeks, however, he presented himself, saying that two days before, while seated at his fireside, reading, at 9 P.M., he was suddenly seized with frequent sneezing, nasal obstruction, profuse hot, watery secretion and tearing so profuse, as he expressed it, that in about two hours all of the handkerchiefs of the family had been used, as well as all the face towels, and he was driven to use the bath towels, and then used nearly all the supply of them. And, that when he was not wiping his nose he was busy wiping his eyes. With these symptoms was a photophobia which rapidly increased until he was compelled to go to bed and put out his light, but even then enough light from the gas-lighted street entered his room to "hurt his eyes," and finally he was compelled to wrap them in a wet towel to exclude every trace of light. He remained in bed in this condition two nights and a day. At this time he again presented himself with a rhinorrhea which, although profuse, was, as he said, very much better. His eyes were red and itching and streaming tears, his pupils were widely dilated, with still some photophobia, his lids were staring wide open and his eyes seemed to protrude slightly, his external nose was quite red and markedly swollen and slightly chapped from wiping. He said his chest felt "full." His windpipe and into the bifurcating bronchi was bright blood red. No râles in chest; temperature normal. He said he thought that if the local nose and eye trouble could be stopped he would feel well. I cocainized the nose anteriorly, without effect, and then cocainized the ganglia by painting the sphenopalatine foramina ½ drop saturated water solution 90% +. This was repeated three times at five-minute

Digitized by Illinois College of Optometry

intervals with marked benefit each time. The nasal obstruction, rhinorrhea, lacrimation, mydriasis, rosacea, and appearance of exophthalmos vanished. He looked normal, and said he felt so. There was a slight return of the symptoms in 24 hours, which again yielded to cocaine, and again in another 24 hours. He then remained free of symptoms until February 10, 1915, when he returned because of another "cold" (coryza), presenting again the above described picture, much milder, however, in every way; but this time accompanied by pain in his ear, mastoid, occiput, neck, shoulder blade, and shoulder, not very severe. This time he had slight dyspnea and a few dry râles in the first 24 hours. This time he did not show post-ethmoidal-sphenoidal suppuration but only congestion of the olfactory fissure.

December 31, 1918, violent acute coryza with all the symptoms already recorded, plus a well-marked blepharospasm which subsided as the coryza subsided. December 1, 1923, acute frontal empyema, right and left, with no sympathetic syndrome.

This case is at once recognized as the one from which the above description was taken. Many times in the course of 20 years have I heard this state described by patients almost always emphasized by the statement, "No physician ever thinks I'm truthful when I tell this. They (the coryzas) are *awful!*" Many times have I tried to have the patient return to me in the midst of the attack. They are not *very* frequent, however, and the patient usually describes them as occurring at long intervals and often prostrating him, or milder attacks being of short (24 hours) duration he may not recall his promise soon enough. However, since this case impressed itself on me I have learned to recognize the milder types which prove to be rather frequent. They may have little or no rosacea, or little or no photophobia. The rhinorrhea is more profuse and sometimes the only symptom.

Simple Sphenoiditis—Suppurative

Case 110.—Miss DeH., 20 years old, referred by father, Dr. DeH. For three years a profuse suppuration of sphenoidal sinuses. Never any headache or other symptoms. Hajek post-ethmoidal-sphenoidal operation. Dr. Wright reported, "Mem-

Digitized by Illinois College of Optometry

brane not markedly altered. No involvement of periosteum or bone.''

Deafness—Post-ethmoidal-sphenoidal Suppuration

Case 111.—Miss G. W., 33 years of age, became my patient January 18, 1904. She had a suppurating right antrum for which I later did a radical operation. She had lost the hearing of her right ear in the old suppuration, and her left ear began to lose its hearing and it was constantly troublesome. Posterior destruction of the left lower turbinate. She had a hyperplastic post-ethmoidal-sphenoidal lesion of the left side which caused no trouble. April 13, 1912, she showed a post-ethmoidal-sphenoidal suppuration which was the result of a coryza. This subsided without trouble in about two weeks. She continued to have increasing trouble in her left ear, slowly losing her hearing. July 7, 1913, I operated upon the post-ethmoidal-sphenoidal district, knowing that sometimes the sphenoid extended downward into the pterygoid process and any trouble in the sphenoid kept up eustachian tube irritation. This was followed by a cessation of her left ear trouble. I did not see her again for a long time. Finally, in March, 1917, I asked her to report. She then said that her left ear was well.

Orbital Hemorrhage

Case 112.—H. L., aged 19 years, consulted me Dec. 18, 1914, sent by Doctor M. H. Post, and complaining that he very frequently had a hemorrhage into the eye socket.

Examination revealed a bilateral sphenoiditis, which otherwise was without symptoms.

Observation of the patient revealed that a coryza was usually accompanied by a small hemorrhage into the orbit, first one side, then the other. I know no explanation to offer. I merely record the facts.

Orbital Phlegmon

Case 113.—T. C., age 22 years, consulted me Dec. 10, 1899. He gave the history of great pain reaching between his eyes. He was examined 2 weeks before by a rhinologist and the nose declared to be negative. The pain continued, later it ceased sud-

Digitized by Illinois College of Optometry

denly and was at once followed by swelling in the eye socket. The swelling continued to increase, his temperature rose to 104° and when I saw him he was a very desperately ill man. Effort was made to drain the eye socket from without but it was not satisfactory. Four days later his condition becoming rapidly worse (he was apparently moribund), it was decided that the orbit should be drained into the nose. I removed the middle turbinate with the small angle knife, not stopping to take it out, I threw it down into the lower half of the nose and proceeded rapidly through the posterior portion of the ethmoidal capsule, making an opening the size of a man's little finger into the orbit. In twenty-four hours his temperature began to decline and in forty-eight hours the swelling of his orbit also seemed less. The patient made a total recovery. At the time of the orbital opening the external erectus was apparently involved in the inflammatory trouble in such a way that it did not function. Whether that was an involvement of the muscle or a disturbance of the muscle function or whether it was a gripping of the abducens I do not know. It took six months to come back into function perfectly. Vision with this patient was never at any time disturbed.

AFTERTHOUGHTS

The frequency of headache (all kinds) without recognizable systemic or organic neurological basis is well known. The mystery of the etiology of many eye lesions is also well known. From a very extensive experience with such cases I am led to the belief that their explanation is to be found in the hyperplastic lesion of the post-ethmoidal-sphenoidal district, to a degree of frequency that, could it be put into percentage, would *astonish* us all, however familiar we may be with such cases. At the same time it must be clearly understood that I do not at all believe that lesion to be the explanation of *all* such cases. Furthermore when one becomes familiar with that lesion he soon begins to wonder if there is an adult in the temperate zone free of it. This is the question Dr. Wright raised in the introduction. I make the positive statement that it is clinically astonishingly frequent and may often be found without symptoms,

Digitized by Illinois College of Optometry

but that there are also others in whom the lesion clinically does not exist, and that these patients *may be found in all years of life and both sexes.* It therefore requires definite discrimination in selecting these cases for surgical interference.

After finishing the arguments contained in these pages the question again arises, "Is there no bacteriological factor in the hyperplastic lesion?" Personally I think there is, but I have been unable to prove it. It may possibly be proven when the bacteriology of the coryza is settled.

In recording cases I regret that Dr. Wright's report does not accompany each one. However, from the examination of the large number of cases presented to him, remembering the clinical appearances also, I feel sure of the conclusions recorded.

The bibliographical references to the combined lesion of eye and nose disorders are very incomplete. Almost countless articles have appeared in our journals relative to eye disorders secondary to nasal disorders, within the past forty years. These would make an interesting text in themselves. They do not, however, bear upon the problems of the vacuum frontal headache, the nasal ganglion symptom-complex, or hyperplastic sphenoiditis. For these reasons I have omitted this very interesting sidelight on our subject, knowing that I may possibly encounter some criticism as deficient in scholarship. Should occasion ever present, I shall be glad to consider these references.

Digitized by Illinois College of Optometry

REFERENCES

Abernethy, E. A.: Headaches of Nasal Origin, Jour. Oklahoma Med. Assn., November, 1922, xv, 319-321.

Adamkowitz: Die Lehre vom Hirncompression, Wiener Sitzungsberichte, 1883.

Adson, A. W.: Ramisection for Spastic Paralysis, Surg. Clin. North Am., 1925, i, 779-789.

— *and Brown, G. E.:* Treatment of Raynaud's Disease by Lumbar Ramisection and Ganglionectomy and Perivascular Sympathetic Neurectomy of Common Iliacs, Jour. Am. Med. Assn., June 20, 1925, lxxxiv, 1908-1910.

Alden, A. M.: (1) Nasal (Sphenopalatine) Ganglion Pain Syndrome Associated with Disease of Maxillary Sinus, Laryngoscope, June, 1924, xxxiv, 438-439.

— (2) Psychosis Associated with Diseases of the Nasal Accessory Sinuses; Operation, Recovery, Laryngoscope, February, 1924, xxxiv, 126-131.

Aswadurow, Christopher: Ueber die Sympathitiensymptome bei der Migräne insbesondere ueber die Anisokorie, Berlin, 1911, Emil Ebering.

Auerbach, Siegmund: Der Kopfschmerz, Berlin, 1912, Verlag von Julius Springer.

Baer, L.: Headaches of Nasal Origin, Med. Jour. and Record, April 16, 1924, cxix, 400-402.

Barker, Lewellys F.: Anatomical Terminology with Special Reference to the B. N. A., Philadelphia, 1907.

Berger, Emil: "Berger and Tyrmann:" Die Krankheiten d. Keilbeinhoehle und ihrer Bezieh. z. Erkrankungen d. Sehorganes, Wiesbaden, 1886, Verlag von J. F. Bergmann; These de Paris, 1890.

Birsch-Hirschfeldt, A.: Die Krankheiten der Orbita, Graefe-Saemisch Handbuch, 1907, ed. 2, Part II, Chapter XIII.

Bliss, M. A.: The Importance of the Paranasal Sinuses in the Explanation of Pain in the Face, Head, Neck, and Shoulders, Tr. Am. Neurol. Assn., 1914; Am. Jour. Med. Sc., 1914.

Boebinger, M. B.: Nasal or Sphenopalatine Neurosis, Texas State Jour. Med., May, 1923, xix, 35-38.

Boyer, A.: Traite complet d'Anatomie, 1803, i, 126; idem, iv, 177.

Brandon, W. R.: Contractured Ulnar Paralysis Relieved by Treatment of the Nasal Ganglion, Arch. Otolaryngol., 1926, iv, No. 6, pp. 493-494.

Braswell, J. C.: Sphenopalatine Ganglion Headaches, Jour. Oklahoma Med. Assn., November, 1922, xv, 321-324.

Brawley, Frank E.: The Relation of Diseases of the Nasal Accessory Sinuses to Diseases of the Eyes, Jour. Am. Med. Assn., March 23, 1907, xlviii, No. 12.

Brown, P. K., and Coffey, W. B.: Surgical Treatment of Angina Pectoris, Arch. Int. Med., October, 1924, xxxiv, 417-445.

Bryan, W. M. C.: Control of Pain of Herpes Zoster of Nervus Ophthalmicus Through Nasal (Sphenopalatine, Meckel's) Ganglion and Through Sphenoid Sinus, Laryngoscope, September, 1923, xxxiii, 703-705.

Buch, Max: Die Sensibilitaetsverhaeltnisse des Sympathicus und Vagus mit besonderer Beruecksichtigung ihrer Schmerzempfindlichkeit im Bereich der Bauchhoehle, Arch. f. Physiol., 1901, pp. 197-221; St. Petersburg Med. Wchnschr., 1901, N. F., XVII, 131 and 141.

Digitized by Illinois College of Optometry

Buchanan, J. A.: Results of Surgery for Migraine, Surg., Gynec. and Obst., May, 1924, xxxviii, 638-639.

Burger, H.: A Review of the Literature on the Nasal Ganglion Syndrome, Nederl. Tijdschr. u. geneesk., July, 1926, pp. 404-412.

Butlin, Henry T.: Diseases of the Tongue, London, 1900, Cassel and Co., pp. 81-82.

Byrd, Hiram: (1) Pathological Currents and Cancer, Jour. Cancer, July-December, 1926.

— (2) Pathological Impulses or Currents, Med. Jour. and Record, February 4, 1925, cxxi, 141-144.

— (3) The Relation of the Nasal Ganglion to Glaucoma, Arch. Ophth., 1927, lxii, 162-168.

Caldwell, G. W.: Diseases of the Accessory Sinuses of the Nose and an Improved Method of Treatment for Suppuration of the Maxillary Antrum, New York Med. Jour., November 4, 1893.

Campbell, Harry: Headache and Other Morbid Cephalic Sensations, 1894.

Canfield, R. Bishop: Submucous Resection of the Lateral Wall of the Nose. Discussion. Jour. Am. Med. Assn., October 3, 1908.

Carlson, A. J.: Relation of the Endocrine Glands to the Disorders of the Ear, Nose and Throat, Arch. Otolaryngol., January, 1925, i, 1-13.

Cary, E. H.: Discussion of J. D. Heitger's Eye Lesions of Nasal Origin, Southern Med. Jour., March, 1923, xvi, 218-226.

Chamberlin, W. B.: Report of a Case of Nasal Polypi Involving the Orbit, Frontal Sinus and Anterior Fossa of the Skull, Tr. Am. Laryngol., Rhinol. and Otol. Soc., 1913.

Cholewa: Warum rezidiniren Nasenpolypen, Montaschr. f. Ohrenheilkunde, 1900.

Citelli and Bosile: Experimental Confirmation of the Physio-pathological Relations Between Nasopharynx and Hypophysis, Riv. ital. di. Neuropat., Cataria, 1915, viii, 385-419.

Clerf, L. H.: Control, Through the Nasal Ganglion, of Earache of Laryngeal Origin, Jour. Am. Med. Assn., February 23, 1924, lxxxii, 630.

Coman, F. D.: Observations on the Relation of the Sympathetic Nervous System to Skeletal Muscle Tonus, Bull. Johns Hopkins Hosp., March, 1926, xxxviii, No. 3, pp. 163-188.

Cook, J. D.: Symptomatology of a Case of Sphenopalatine Ganglion Neurosis, Jour. Missouri Med. Assn., September, 1924, xxi, 319.

Cordes, Hermann: Ueber d. Hyperplasie d. polyposes Degeneration d. mit. Muschel. d. Nasenpolypen u. i. Beziehungen z. knoechernen, Thieli d. Siebbeins, Arch. Laryngol. u. Rhinol., xi, 280.

Coulet, G.: Some Considerations on Postsinusitis, Rev. d. Laryngol., etc., April 30, 1924.

Cushing, Harvey: The Major Trigeminal Neuralgias and Their Surgical Treatment Based on Experiences with 332 Gasserian Operations, Am. Jour. Med. Sc., August, 1920, p. 157.

Davis, Chas. Lathey: Control of Pain of Herpes Zoster of the Ophthalmic Nerve and the Brachial Plexus Through the Nasal (Sphenopalatine) Ganglion, Arch. Otolaryngol., June, 1925, i, 642-643.

Davis, Loyal E.: Lesions of the Paratrigeminal Area, Jour. Am. Med. Assn., February, 1923, lxxx, 380-382.

Davis, Warren B.: Development and Anatomy of the Nasal Accessory Sinuses in Man, 1914.

Digitized by Illinois College of Optometry

Dean, L. W.: The Control of Glossodynia, Southern Med. Jour., October, 1922, xv, 856.

Delavan, D. Bryson: Otalgia from Reflex Dental Irritation, Am. Jour. Otology, iv, 177.

Denker, Alfred: Zur Radikal operation d. Chronischen Kieferhoelenempeyems, Arch. Laryngol., 1905, xvii, 221.

Dogiel, A. S.: Zwei Arteten Sympathisen Nerven Cellen Anat. Anz., 1896, xi, 679.

Dorrance, Geo. M.: Alcoholic Injections into the Gasserian Ganglion, Jour. Am. Med. Assn., March 22, 1924, lxxxiii, 1678-1680.

Dowling, J. I.: Relations of the Maxillary Sinus to Ocular Disease, Laryngoscope, March, 1924, xxxiv, 167-173.

Doyle, Jno. B.: Glossopharyngeal Neuralgia, Arch. Neurol. Psychiat., January, 1923, ix, 34-46; also in Med. Clinics North Am., July, 1923, vii, 285-292.

Deutsch, Bela: Orvosi hetil., 1925, No. 3, p. 969.

Effler, L. R.: Vacuum Frontal Headache, Laryngoscope, May, 1925, xxxv, 375-382.

Einthoven: Hymanns de Laryngol. u. Rhinol., iii.

Engman, M. F.: Glossodynia, Burning Tongue, Arch. f. Dermatol. and Syphilol., February, 1920, i.

Etheridge, H. R.: Nasal (Sphenopalatine, Meckel's) Ganglion Neurosis and Hyperplastic Sphenoiditis, Virginia Med. Monthly, October, 1921, xlviii, 377.

Ewing, A. E. (*See* also Sluder and Ewing).

— (1) A Point in the Diagnosis of the Frontal Headache, St. Louis Courier of Med., 1899, p. 370.

— (2) Pain of Acute Glaucoma Relieved by Cocaine Applied to Meckel's Ganglion, Am. Jour. Ophth., December, 1908.

Fisher, F., Jr.: Sphenopalatine Ganglion Neurosis, Atlantic Med. Jour., November, 1924, xxviii, 59-62.

Flatau, Ed.: Die Migraene, 1912.

Freer, Otto T.: The Frontal Sinus; Opening It Through the Nose for Chronic Suppuration, Tr. Am. Laryngol. Assn., 1915.

Gantt, W. H.: Recent Work of Pawlow and His Pupils, Arch. Neurol. Psychiat., April, 1927, xvii, 514-528.

Gaudet, L. S.: Sphenopalatine Ganglion Neuralgia, New Orleans Med. and Surg. Jour., September, 1924, lxxvii, 114-120.

Goalwin, H. A.: The Optic Canal in Normal and Deformed Skulls, Ztschr. f. Augenheilkunde, November, 1924, liv.

Goldschmidt-Osmund, Bruno: Ueber die Beinflussung migränartigen Zustande vom Keilbein Aus, Arch. f. Laryngol. u. Rhinol., 1921, xxxiv.

Goodale, J. L.: Studies Regarding Anaphylactic Reactions Occurring in Horse Asthma and Allied Conditions, Tr. Am. Laryngol. Assn., 1914.

Gowers, Sir Wm. R.: The Borderland of Epilepsy, 1907.

Grahe and Metzger: Regionäre Gefäszreationen A. A. Kopfe auf Haut- und Schleimhautreize und ihre klinische Bedeutung, Ztschr. f. Laryngol., Rhinol. u. Otol., February, 1927, xv, 171-173.

Gruenwald, L.: Die Lehre von den Naseneiterungen, 1893.

Gundelach, C. A.: Post-nasal Observations by Means of the Nasopharyngoscope, Laryngoscope, 1915.

Gundrum, L. R.: (1) Asthma and Eczema Controlled Through the Nasal (Sphenopalatine) Ganglion, Ann. Clin. Med., January, 1926, iv, 572-573.

— (2) Nasal (Sphenopalatine, Meckel's) Ganglion Neuroses, California and Western Med., February, 1926, xxiv, 204-208.

Digitized by Illinois College of Optometry

— (3) Grundrum, L. K.: Pain from Tuberculous Laryngitis, Relieved by Cocainization of the Nasal (Sphenopalatine, Meckel's) Ganglion, Jour. Am. Med. Assn., September 27, 1924, lxxxiii, 998.

Hajek, M.: (1) Erkrank. d. Nebenhoelen d. Nase, Wien, 1914, Verlag Franz Deuticke.

— (2) Pathology and Treatment of the Inflammatory Diseases of Nasal Accessory Sinuses, English Translation, 1926, St. Louis, C. V. Mosby Company.

— (3) Ueber d. patholog. Veraenderungen d. Siebein Knochen im Gefolge d. entzuendlichen Schleimhauthypertrophie u. d. Nasenpolypen, Arch. f. Laryngol., 1896, iv.

— (4) Zur Diagnose u. intranasalen chirurgischen Behandlung d. Eiterungen d. Keilbeinhoele u. d. Hintern Siebbeinlabyrinthes, Arch. f. Laryngol., xvi.

Halle, Max: Externe oder interne operation d. Nebenhoeleneiterungen, Verhandl. d. Berlin, med. Gesselsch., 1906.

Haskin, W. H.: Ocular Manifestations in Nasal and Aural Diseases which Probably Indicate Involvement of the Sympathetic Nervous System, Ann. Otol., Rhinol. and Laryngol., 1913.

Heitger, Joseph D.: (1) A Consideration of the Sphenoid and Posterior Ethmoid Paranasal Cells as an Etiological Factor in So-called Brachial Neuritis, Southern Med. Jour., March, 1925, xviii, No. 3, pp. 218-221.

— (2) Clinical and Topographic Diagnosis of Suppurative and Nonsuppurative Paranasal Cell Disease, Ann. Otol., Rhinol. and Laryngol., September, 1924, xxxiii, No. 3, pp. 712-734.

Herrick, C. Judson: Introduction to Neurology, Philadelphia, 1916, W. B. Saunders and Company.

Heyman and Ritter: Zur Morphologie u. Terminologie d. mittleren Nasenganges, Ztschr. f. Laryngol. u. Rhinol., 1909, i, p. 1.

Holmes, Edgar M.: (1) Examination and Treatment of the Nasopharynx, Eustachian Tube by Aid of the Nasopharyngoscope, Ann. Otol., Rhinol. and Laryngol., March, 1911.

— (2) The Intranasal Treatment of Meckel's Ganglion, Tr. Am. Laryngol., Rhinol. and Otol. Soc., 1913; Ann. Otol., Rhinol. u. Laryngol., 1913.

Hood, M. H.: Nasal Ganglion Neuralgia, Virginia Med. Monthly, December, 1923, 1, 620-624.

Hoople, G. D.: A New Method of Anesthesia for Opening Peritonsillar Abscess, Laryngoscope, August, 1926, xxxvi, No. 8, pp. 577-579.

Hubert, Louis: (1) A Study of the Mechanism and Treatment of Rhinorrhea and Sneezing—A Local Manifestation of Some Metabolic Disorder, with an Analysis of Thirty-Four Cases, Ann. Otol., Rhinol. and Laryngol., September, 1924, xxxiii, 824-843.

— (2) Mechanism of Pain as Seen in Otological Cases, Laryngoscope, August, 1923, xxxiii, 596-608.

— (3) The Involuntary Nervous System of the Nose and the Mechanism of Some Obscure Nasal Symptoms, Laryngoscope, July, 1922, xxxii, 493-509.

Hunt, J. Ramsay: (1) A Further Contribution to the Herpetic Inflammations of the Geniculate Ganglion. A Syndrome Characterized by Herpes Zoster Oticus, Facialis or Occipitocullaris with Facial Palsy and Auditory Symptoms, Am. Jour. Med. Sc., August, 1908.

— (2) On Herpetic Inflammations of the Geniculate Ganglion. A New Syndrome and Its Complications, Jour. Nervous and Mental Diseases, February, 1907.

Digitized by Illinois College of Optometry

— (3) The Sensory Field of the Facial Nerve (A Further Contribution to the Syndrome of the Geniculate Ganglion), Brain, 1915, xxxviii, 420; also Arch. Inter. Med., 1910, p. 631.

Hurd, L. M.: Unequal Blade Speculum, Med. Record, November 25, 1905, pp. 46 and 47.

Hutter, Fritz: Ztschr. f. Hals Nasal und Ohren., August 15, 1922, ii.

Ide, Clarence: Psychosis Resulting from Toxins of Chronic Maxillary Sinusitis, Coupled with Left Hyperphonia of 8½ per cent, Laryngoscope, December, 1925, xxxv, 924-925.

Ingals, E. F.: New Operation and Instruments for Draining the Frontal Sinus, Laryngoscope, August, 1905.

Kakeshita, T.: Kehlkopf und Sympathicus, Pfhüger Arch. für d. ges. Physiol., 1926, ccxv, 22-31.

Kanavel, A. B., Pollock, L. J., and Davis, L.: Relation of the Sympathetic Nervous System to Muscle Tone, Arch. Neurol. Psychiat., February, 1925, xiii, 197-225.

Kuhnt, Herman: Eine klinische Studie ueber die entzündlichen Erkrankungen der Stirnhoehle und ihre Folgezustande, Wiesbaden, 1894, Verlag von J. F. Bergmann, p. 72.

Kuntz, Albert: Experimental Studies on the Histogenesis of the Sympathetic Nervous System, Jour. Comparative Neurol., February, 1922, xxxiv.

Kieth, Arthur: The Antiguity of Man, 1915.

Killian, G.: (1) Die Killian'sche Radikal Operation Chronischer Stirnhoelen-eiterungen, Arch. f. Laryngol., xiii.

— (2) Zur Anatomie d. Nase Menschlicher Embryonen, Arch. f. Laryngol., 1895, ii.

Kleijn, de. A., and Gerlach, N.: Pathologisch-anatomisches ueber den Zusammenhang zwischen Augen-und Nasenleiden, V. Graefe's Arch. f. Ophth., 1913, lxxxiv, No. 1, p. 164.

Krause, W.: Anatomie d. Menschen, p. 547.

Laborroque: Essai sur le Caphalalgia et la Megraine, These de l'ecocle de Medicin de Paris, 1837, Quoted by E. Liveing.

Lack, H. Lambert: Diseases of the Nose and Its Accessory Sinuses, London, 1905, Longmans, Green and Co.

Langley: Schaeffer's Textbook of Physiology.

Lannois and Berial: Histological Examinations of the Superior Laryngeal Nerve after Alcohol Injection, Rev. Lbd. de Laryngol., March 7, 1914 (review in Index and Digest of Otolaryngol., Published by the Largyngoscope, 1915, No. 811, p. 501).

LeBlanc, E., and Van Wyngaarden, G. de Lind: Untersuchungen ueber die Innervation der Lungergefässe und Bronchien, Pflügers Arch. f. d. ges. Physiol., 1924, cciv, Ref. Zentrlbl. f. d. Nasen., April 10, 1925, vii.

Leriche, R., and Fontaine, R.: Physiologic Rôle of Middle Cervical Ganglion, Presse Med., September 22, 1926, xxxiv, 1194-1195; abstract, Jour. Am. Med. Assn., November 13, 1926, lxxxvii, 1689.

Lilienthal, H.: Cervical Sympathectomy in Angina Pectoris, Arch. Surg., January, 1925, x, 531-543.

Lillie, H. I.: Otalgia and Mastoidalgia not Indications for Operation on the Mastoid Process, Jour. Am. Med. Assn., August 5, 1922, lxxix, 431.

Liveing, Ed.: On Megrim and Sick Headache, 1873.

Loeb, H. W.: (1) A Study of the Anatomic Relations of the Optic Nerve to the Accessory Cavities of the Nose, Ann. Otol., Rhinol. and Laryngol., June, 1909.

Digitized by Illinois College of Optometry

— (2) Fatalities Following Operations upon the Nose and Throat not Dependent upon Anesthesia, Ann. Otol., Rhinol. and Laryngol., June, 1922, xxxi, 273-296.

Lothrop, Howard A.: The Treatment of Frontal Sinus Suppuration, Laryngoscope, January, 1917.

Luc, Lermoyez: Une Nouvelle Methode Operative pour la cure radicale et rapide l'empyeme Chronique du sinus maxillaire, Arch. Internat. de laryngol. d. otol. et de rhinol., May-June, 1897.

Luedde, W. H.: (1) Ocular Tuberculosis in Relation to the Nose and Throat, Am. Jour. Ophth., October, 1914.

— (2) The Significance of the Tuberculin Reaction and Other Problems in Ocular Tuberculosis, Am. Jour. Ophth., March, 1923, vi, 161-174.

— (3) The Usefulness of the Schiotz Tonometer, Am. Jour. Ophth., October, 1912.

Luschka: Anatomy des Schlundkopf, 1873.

Lyman, H. W.: Simulated Mastoiditis Relieved by Sphenoidectomy, Laryngoscope, December, 1924, xxxiv, 948-955.

Lyons, H. R.: (1) Otitis Media Complicating Operations on the Gasserian Ganglion, Jour. Am. Med. Assn., January 20, 1923, lxxx, 176-178.

— (2) Treatment by Radium of Nasal Polyps, Am. Jour. Roentgenology, September, 1922, ix, 584-587.

Lynch, R. C.: Vacuum Diseases of the Maxillary Sinus, Ann. Otol., Rhinol. and Laryngol., 1914.

McBride, P.: (1) Diseases of the Throat, Nose and Ear, Philadelphia, 1891, P. Blakiston's Son and Co., p. 352.

— (2) Ueber die Diagnose und Behandlung der Krankheiten der Accessorischen Hoelen der Nase, Deutsch. med. Wchnschr., 1891, p. 221.

McMahon, B. J.: Pathology of Sphenoethmoidal Sinusitis, Arch. Otolaryngol., October, 1926, iv, 310-333.

Maclay, N.: Nasal Neuroses, Brit. Med. Jour., November 29, 1924, ii, 996-999.

Martin, H. H.: Some Recent Surgery of Cranial Nerves for the Relief of Headaches and Other Neuroses, Southern Med. Jour., March, 1914, xii, No. 3.

Martin, Sidney: Necrosing Ethmoiditis: A Disclaimer, Brit. Med. Jour., December 24, 1892, p. 1408.

May, Otto: Functional and Histologic Effects of Intraneural and Intraganglional Injections of Alcohol, Brit. Med. Jour., August 31, 1912, p. 465.

Miégeville, R.: Sphenopalatine Ganglion Syndrome, Médicine, January, 1925, vi, 303-304.

Mihalkov'cs, V.: Anatomie u. Entwicklungs geschichte d. Nase, Hymanns Handbuch. d. Laryngol. u. Rhinol., iii, 35.

Mikulicz: Langenbecks Arch., xxxiv.

Miller, Harold Clayton: Some Experiences with Cocainization of Nasal Ganglion, W. Virginia Med. Jour., September, 1924, xix, 479-489.

Miller, H. E.: Intraocular Tension in Glaucoma Lowered by Injection of Sphenopalatine Ganglion, Proc. Otol. Laryngol. Soc., St. Louis Med. Soc., March 2, 1913. Index of Otolaryngol., iii, No. 4.

Mitchell, S. W.: Neuralgic Headaches with Apparitions of Unusual Character, Tr. College of Physicians of Philadelphia, 1887, ix, series 3.

Moebius, P. P.: Die Migräme, 1894. Im nothnagels "Specialle Pathologie u. Therapie."

Mosher, Harris P.: (1) The Applied Anatomy and Intranasal Surgery of the Ethmoidal Labyrinth, Tr. Am. Laryngol. Assn., 1912.

Digitized by Illinois College of Optometry

— (2) The Premaxillary Wings and Deviation of the Septum, Laryngoscope, November, 1907.

Mosser, W. Blair, and Taylor, K. P. A.: The Effect of the Sympathetic Nervous System on the Peripheral Vascular System: An Experimental Study, Arch. Surg., March, 1926, xii, No. 3, pp. 760-769.

Müller, Ernst Friedrich: The Involuntary Nervous System: An Important Factor in the Body's Resistance, Arch. Int. Med., June, 1925, xxxv, 796-806.

Müller, L. R.: Ueber die Lebensnerven, Muenchen. med. Wchnschr., August 25, 1922, lxix, 1239-1241.

— *and Dahl, W.:* Die Beteiligung des Sympathischen Nervensystems an der Kopfinnervation, Deutsch. Arch. f. klin. Med., xcix, 48-107.

Neivert, Harry: Morphologic Variation as a Factor in the Symptomatology of Paranasal Sinus Disease, Arch. Otolaryngol., April, 1925, i, 367-383.

Onodi, A.: The Optic Nerves and the Accessory Sinuses of the Nose, Ann. Otol., Rhinol. and Laryngol., 1908; also "Der Sehnerv. und die Nebenhoelen der Nase, Wien, 1907, Verlag von Alfred Holder.

Onodi, Ladislaus: (1) The Rhinogenic and Otogenic Lesions of the Third, Fourth, Fifth, and Sixth Cranial Nerves, Jour. Laryngol., Rhinol. and Otol., 1914.

— (2) Ueber die Beziehungen der Keilbeinhoehle zu der Nervenstaemme des Oculomotorius, Trochlearis, Trigeminus and Abducens, Arch. f. Laryngol. u. Rhinol., July 12, 1912, No. 2.

Payne, R. J.: Treatment of Nasal (Sphenopalatine, Meckel's) Ganglion in Hay Fever, Jour. Mo. State Med. Assn., August, 1924, xxi, 257-259.

Piersol, Geo. A.: Human Anatomy, 1907.

Post, M. H.: Two Striking Cases of Optic Neuritis and Retino Choroiditis Secondary to Accessory Nasal Sinus Disease, Jour. Mo. Med. Assn., 1923, xx, 405-408.

Pratt, Jno. A.: The Present Status of the Intranasal Ethmoid Operation, Arch. Otolaryngol., January, 1925, i, 42-50.

Proetz, A. W.: (1) Formation and Function of Accessory Nasal Sinuses and Mastoid Cells, Ann. Otol., Rhinol. and Laryngol., December, 1922, xxxi, 1083-1092.

— (2) Further Data on the Displacement Method in Sinuses, Ann. Otol., Rhinol. and Laryngol., June, 1927, xxxvi, 297-324.

Quain: Elements of Anatomy, 1908.

Ramadier, J.: Latent Postsinusitis the Cause of Optic Neuritis, Trigeminal and Sphenopalatine Neuritis, Ann. d. mal. de l'oreilli, du Larynx, etc., February, 1922.

Ranson, S. W.: (1) The Cardiac Nerves in Angina Pectoris, Am. Heart Jour., April, 1926, i, 508-515.

— (2) The Anatomy of the Nervous System, W. B. Saunders Co., Philadelphia, 1923, p. 335.

— (3) The Anatomy of the Sympathetic Nervous System with Reference to Sympathectomy and Ramisectomy, Jour. Am. Med. Assn., June 19, 1926, lxxxvi, 1886.

Rehfeldt, C. S.: Control of Intractable Singultus (Hiccough) Through the Nasal (Sphenopalatine, Meckel's) Ganglion, Laryngoscope, May, 1925, xxxv, 354-357.

Reichert and du Bois, Reymond: Arch. f. Anatom. u. Physiol., 1860, p. 461; quoted by E. Liveing, on Megrim and Sick Headache, 1873.

Digitized by Illinois College of Optometry

Reid, M. R., and Eckstein, G.: Sensory Disturbances Following Sympathectomy for Angina Pectoris, Jour. Am. Med. Assn., July 12, 1924, lxxxiii, 114-117.

Reverchon, L., and Worms, G.: Atrophic Rhinitis of Ozena Type Following Wound of Pterygopalatine Region—Sphenopalatine Syndrome, Rev. d. laryngol., etc., January, 1924, xliv, 48-53.

Rossi, Ottorino: On the Afferent Paths of the Sympathetic Nervous System with Special Reference to Nerve Cells of Spinal Ganglia Sending Their Peripheral Processes into the Rami Communicantes, Jour. Comparative Neurol., October, 1922, xxxiv.

Rowntree, L. G., and Adson, A. W.: (1) Bilateral Lumbar Sympathetic Ganglionectomy and Ramisectomy for Polyarthritis of the Lower Extremities, Jour. Am. Med. Assn., March 5, 1927, lxxxviii, 694-696.

— *and* — (2) Bilateral Lumbar Sympathetic Neurectomy in the Treatment of Malignant Hypertension, Jour. Am. Med. Assn., September 26, 1925, lxxxv, 959-961.

Royle, N. D.: (1) A New Operative Procedure in the Treatment of Spastic Paralysis and Its Experimental Basis, Med. Jour. Australia, January 26, 1924, i, 77-86.

— (2) The Operations of Sympathetic Ramisection, Med. Jour. Australia, June 14, 1924, i, 587-590.

Ruskin, Simon L.: (1) Pain of Herpes Zoster Oticus Relieved by Sphenopalatine Ganglion Treatment, Laryngoscope, April, 1925, xxxv, No. 4, 301-302.

— (2) Study of Sphenopalatine Ganglion, Laryngoscope, February, 1925, xxxv, 87-108.

— (3) The Nasal (Sphenopalatine) Ganglion in Relation to Itching of the Auditory Canal and to Tinnitus Aurium, Arch. Otolaryngol., September, 1925, ii, No. 3, pp. 269-270.

Schaeffer, J. Parsons: (1) Some Points in the Regional Anatomy of the Optic Pathway with Special Reference to Tumors of the Hypophysis Cerebri and Resulting Ocular Changes, Anatomical Record, September, 1924, xxviii, No. 4.

— (2) The Genesis, Development and Adult Anatomy of the Nasofrontal Region in Man, Am. Jour. Anat., 1916, xx, 125-145.

— (3) The Nose, Paranasal Sinuses, Nasolacrimal Passageways, and Olfactory Organ in Man, Philadelphia, 1920, P. Blakiston's Son and Co., p. 148.

Schaeffer, M.: Chirugische Erfahrungen in d. Rhinologie u. Laryngologie, 1885.

Schlösser: Erfahrungen in d. Neuralgie Behandlung mit Alkoholeinspritzungen, Verhandl. d. Kongresses. f. Inn. Med., Wiesbaden, 1907, J. F. Bergmann.

Senseney, E. T.: Relation of Endocrine Changes to Nasal (Sphenopalatine) Ganglion Neurosis (Lower Half Headache), Ann. Otol., Rhinol. and Laryngol., March, 1925, xxxiv, 183-190.

Shambaugh, Geo. E.: Some of the More Recent Problems in Rhinology, Minnesota Med. Jour., July, 1924, vii, 496-500.

Shea, Jno. J.: Discussion of J. D. Heitger's A Consideration of the Sphenoid and Posterior Ethmoid Paranasal Cells as an Etiological Factor in So-called Brachial Neuritis, Southern Med. Jour., March, 1925.

Shelden, W. D.: Tumors Involving the Gasserian Ganglion, Jour. Am. Med. Assn., 1921, lxxvii, 700-705.

Sjöstrom, Lennart: On the Significance of the Sternocleidomastoidus and Trapezius Myalgia in Otorhinology, Acta Otolaryngol., 1924, vi, 631.

Skillern, R. H.: Accessory Sinuses of the Nose, Philadelphia, 1916, Lippincott and Co., ed. 3, p. 73.

Digitized by Illinois College of Optometry

Sluder, Greenfield: (1) (a) A Case of Nodular Headache. (b) Nausea as a Nasal Reflex, Ann. Otol., Rhinol. and Laryngol., December, 1921; Tr. Am. Laryngol. Assn., 1919.

— (2) A Galvanocautery Operation for the Lower Turbinate, Laryngoscope, March, 1916.

— (3) A Method for the Removal of the Whole or a Part of the Middle Turbinate, Jour. Am. Med. Assn., June 29, 1907, xlviii, 2183-2184.

— (4) Anatomy of the Sphenoidal Fissure, Tr. Am. Laryngol. Assn., 1923; Ann. Otol., Rhinol. and Laryngol., December, 1923.

— (5) A Phenol (Carbolic Acid) Injection Treatment for Sphenopalatine Ganglion Neuralgia, Jour. Am. Med. Assn., December 30, 1911, lvii, 2137.

— (6) Asthma as a Nasal Reflex, Jour. Am. Med. Assn., August 23, 1919, lxxiii, 589.

— (7) A Surgical Consideration of the Upper Paranasal Cells, Tr. Am. Laryngol. Assn., 1916; Ann. Otol., Rhinol. and Laryngol., June, 1917.

— (8) Blindness Due to Post Ethmoidal Empyema Acute. Report of a Case, Laryngoscope, November, 1907, xvi, No. 11, pp. 883-884.

— (9) Clinical Note on the Relief of Asthma in the Presence of Chronic Bronchitis with Emphysema Through the Nasal (Sphenopalatine) Ganglion, Ann. Clin. Med., May, 1925, iii, No. 11.

— (10) (With Green, John) Control of Pain in Functional Hyperesthesia of the Ciliary Muscle (Painful Accommodation) Through the Nasal (Sphenopalatine, Meckel's) Ganglion, Jour. Am. Med. Assn., November 24, 1923.

— (11) Die Physiologische Rolle der Anastomose zwischen n. Laryngeus superior und n. Laryngeus inferior, Sitzungsh. d. k. Akad. d. Wissensch. Math.-naturio, Wien, 1898, cvii, 7-13.

— (12) Die Wechselbeziehungen zwischen Aktion des Pharynx und des weichen Gaumens und ihre Bedeutung für die Diagnostik der Verhaltnisse im Nasenrachenraum, Arch. f. Laryngol. u. Rhinol., xxx, No. 1.

— (13) Etiology, Diagnosis, Prognosis and Treatment of Sphenopalatine Ganglion Neuralgia, Jour. Am. Med. Assn., September 27, 1913, lxi, 1201-1205.

— (14) External Cricoidynia: Its Control Through the Nasal (Sphenopalatine-Meckel's) Ganglion, Jour. Am. Med. Assn., March 10, 1923.

— (15) Five Unusual Cases of Nasal (Sphenopalatine) Ganglion Neurosis, Southern Med. Jour., November 12, 1917.

— (16) Four Unusual Nasal (Sphenopalatine) Ganglion Cases, Tr. Am. Laryngol. Assn., 1918.

— (17) Further Clinical Observations on the Sphenopalatine Ganglion (Motor, Sensory, and Gustatory), New York Med. Jour., April 23, 1910, xci, 850-851.

— (18) Further Observations on Some Anatomical and Clinical Relations of the Sphenoid Sinus to the Cavernous Sinus and the Third, Fourth, Fifth, Sixth, and Vidian Nerves, Tr. Am. Laryngol. Assn., 1913; Arch. f. Laryngol. u. Rhinol., xxviii, No. 1; Ann. Otol., Rhinol. and Laryngol., 1914.

— (19) Glossodynia with Lingual Tonsillitis as Its Etiology and Its Control Through the Nasal Ganglion. Report of a Case, Tr. Am. Laryngol. Assn., 1923; Jour. Am. Med. Assn., July 14, 1923, lxxxi, 115.

— (20) Hyperplastic Sphenoiditis; and Its Relations to the Second, Third, Fourth, Fifth, Sixth, and Vidian Nerves and the Nasal Ganglion, Tr. Washington University Med. Soc., March, 1915; Tr. Am. Laryngol. Assn., 1915.

Digitized by Illinois College of Optometry

— (21) Lower Half Headache (Neuralgic) of Nasal Origin: Glossodynia Otalgia, Nausea, Parageusia, Vertigo, Scotoma, Photophobia, Rhinorrhea and Asthma as Isolated Phenomena, Jour. Am. Med. Assn., December 2, 1922, lxxix, 1898 and 1899.

— (22) Nasal Headaches, Chicago Med. Soc., Laryngol. Sec., October 22, 1912.

— (23) Nasociliary Neuralgia, Ann. Otol., Rhinol. and Laryngol., March, 1922; Tr. Am. Laryngol. Assn., 1920.

— (24) Nerve Trunk Anesthesia and Carbolization in Nasal Surgery, Laryngoscope, November, 1913.

— (25) Ophthalmic Migraine: Controllable Through the Nasal (Sphenopalatine-Meckel's) Ganglion. Report of a Case with Unusual Features, Laryngoscope, July, 1924.

— (26) Spasm of the Esophagus Relieved through the Nasal (Sphenopalatine-Meckel's) Ganglion, Laryngoscope, June, 1924.

— (27) Some Anatomic and Clinical Relations of the Sphenoid Sinus to the Cavernous Sinus and the Third, Fourth, Fifth, Sixth, and Vidian Nerves, Arch. f. Laryngol. u. Rhinol., xxvii, No. 3; Ann. Otol., Rhinol. and Laryngol., September, 1913.

— (28) Some Clinical Observations on the Lingual Tonsil, Concerning Goiter, Glossodynia and Focal Infection, Am. Jour. Med. Sc., August, 1918, clvi, No. 2, p. 248.

— (29) Some Rhinological Experiences in Ophthalmology, Jour. Southern Med. Assn., March, 1922.

— (30) Some Rhinologic Observations with Speculation Concerning the Involuntary Nervous System, Jour. Am. Med. Assn., November 8, 1924, lxxxiii, 1487-1489.

— (31) The Anatomical and Clinical Relations of the Sphenopalatine (Meckel's) Ganglion to the Nose and Its Accessory Sinuses, New York Med. Jour., August 14, 1909, pp. 293-298; Tr. Am. Laryngol. Assn., 1909.

— (32) The Borderland of Rhinology, Neurology and Ophthalmology, Jour. Am. Med. Assn., August 27, 1921, lxxvii, 688-692.

— (33) The Control of Earache Through the Nasal (Sphenopalatine-Meckel's) Ganglion, Tr. Am. Laryngol. Assn., 1922; Jour. Am. Med. Assn., June 3, 1922.

— (34) The Control of Mandibular Pain Through the Nasal (Sphenopalatine-Meckel's) Ganglion, Tr. Am. Laryngol. Assn., 1922.

— (35) The Correlated Action of the Pharynx and Soft Palate: And Its Effects upon Postnasal Diagnosis, Tr. Am. Laryngol. Assn., 1914; Ann. Otol., Rhinol. and Laryngol., March, 1916.

— (36) The Diagnosis of Inflammatory Diseases of the Accessory Sinuses of the Nose, Jour. Missouri State Med. Assn., 1906, iii, No. 3, pp. 162-166.

— (37) The Involuntary Nervous System: A Clinical Abstract, Tr. Am. Laryngol. Assn., 1926.

— (38) The Relations of the Sphenoid Sinus to the Eustachian Tube and Their Possible Clinical Importance, Tr. Am. Laryngol. Assn., 1916; Ann. Otol. Rhinol. and Laryngol., June, 1917.

— (39) The Relations of the Sphenoid Sinus to the Semilunar (Gasserian) Ganglion and Their Possible Clinical Importance, Tr. Am. Laryngol. Assn., 1916.

— (40) The Rôle of the Sphenopalatine (or Meckel's) Ganglion in Nasal Headaches, New York Med. Jour., May 23, 1908, lxxxvii, 989-990.

Digitized by Illinois College of Optometry

— (41) The Simulation of Paranasal Cell Suppurations for Teaching Purposes, Tr. Am. Laryngol. Assn., 1914.
— (42) The Sympathetic Syndrome (Undescribed) of Sphenopalatine or Nasal Ganglion Neurosis, Together with a Consideration of Previously Described Symptoms and Treatment, the Lancet Clinic, Tr. Am. Laryngol. Assn., 1915.
— (43) The Syndrome of Sphenopalatine Neurosis, Am. Jour. Med. Sc., December, 1910, cxl, No. 465, pp. 868-878; Tr. Am. Laryngol. Assn., 1910.
— (44) Two Cases of Tic Douloureux of Sphenoidal Inflammatory Etiology, Laryngoscope, February, 1916.
— (45) Two Factors in Catarrhal Deafness. The Lower Turbinate (Technic) and Sphenoidal Sinus (Anatomy), Jour. Am. Med. Assn., November 27, 1926, lxxxvii, 1799-1802.
— (46) Ueber Anatomische und Klinische Beziehungen Sinus Cavernous und den Nervenstämmen des Oculomotorius, Trochlearis, Trigeminus, Abducens, und Nervus Vivianus, Arch. f. Laryngol. u. Rhinol., xxvii, No. 3.
— (47) Use of Radium for Nasal Polyps, Laryngoscope, February 19, 1924, xxxiv, No. 2, p. 124.
— (48) Vacuum Nasal Headaches with Ocular Symptoms Only, Ann. Otol., Rhinol. and Laryngol., March, 1912, xxi, No. 1, pp. 160-169; Tr. Am. Laryngol., Rhinol. and Otol. Soc., 1911.
— *and Ewing, A. E.:* (1) Abducens Palsy Following Nasal Trauma and Nasal Infection, Am. Jour. Ophth., December, 1914.
— *and* — (2) Frontal Headaches Apparently Ocular but Really of Nasal Origin; Their Recognition and Treatment (by Dr. A. E. Ewing). On the Nasal Conditions Found in These Cases; with Especial Reference to an Abnormal Relation of the Uncinate Process of the Ethmoid to the Bulla of the Ethmoid (by Dr. G. Sluder), Tr. Am. Ophth. Soc., 1900.
Smith, Harmon: Blindness Incidental to External Ethmoidal Operation, Laryngoscope, April, 1915.
Stein, Otto J.: (1) A Survey of the Hay Fever Question, Critical Review of Situation Relative to Etiology and Treatment, Ann. Otol., Rhinol. and Laryngol., December, 1923, xxxii, No. 4, pp. 1214-1228.
— (2) Hyperesthetic Rhinitis, Interstate Med. Jour., July, 1910.
— (3) Some Observations on Hyperesthetic Rhinitis, Laryngoscope, 1908.
— (4) The Treatment of Hyperesthetic Rhinitis, Chicago Med. Recorder, July, 1908.
Stewart, Purves: Diagnosis of Nervous Diseases, 1916.
Suckling, C. W.: Migraine Attacks Followed by Temporary Paralysis of the Third Nerve, Brain, 1888, x, 241.
Symonds: Gulstonian Lectures on Headaches, Med. Times and Gazette, 1858, xvi; quoted by E. Liveing.
Taylor, H. Marshall: Endoscopic Removal of Sand Spurs from Larynx and Tracheobronchial Tree, Jour. Am. Med. Assn., August 27, 1921, lxxvii, 685.
Toney, L. E.: Relief of Lower Toothache by Cocainization of Nasal (Sphenopalatine-Meckel's) Ganglion, Jour. Am. Med. Assn., November 10, 1923, lxxxi, 1609.
Turner, A. Logan: The Accessory Sinuses of the Nose, New York, 1902, Longmans, Green and Co.
Uffenordi, W.: (1) Complicerti Faelle von Nasen Nebenhoelenerkrankungen, Ztschr. f. Laryngol., 1911, iii.
— (2) Die Erkrankungen d. Siebbeins, 1907, p. 32.

Digitized by Illinois College of Optometry

Uren, C. T.: Sphenopalatine Ganglion Neurosis, Nebraska Med. Jour., December, 1922, vii, 421-424.

Watson-Williams, P.: Intranasal Operations for Frontal Sinus Suppuration, Jour. Laryngol., Rhinol. and Otol., May, 1914.

Westlake, S. B.: Relation of the Optic Nerve to the Last Posterior Ethmoid Cell, Ann. Otol., Rhinol. and Laryngol., September, 1923, xxxii, 729-748.

White, L. E.: (1) Aeration of the Posterior Accessory Sinuses in Acute Optic Neuritis, Laryngoscope, May, 1922, xxxii, 382-398.

— (2) Anatomic and X-ray Studies of the Optic Canal in Cases of Optic Nerve Involvement, Ann. Otol., Rhinol. and Laryngol., March, 1924, xxxiii, 121-149.

— (3) Blindness from Teeth, Tonsils and Accessory Sinuses, Laryngoscope, March, 1925, xxxv, 217-226.

— (4) End Results of Sphenoidal Sinus Operations for Optic Nerve Disturbances, Laryngoscope, February, 1924, xxxiv, 135-136.

— (5) Treatment of Optic Nerve Involvement as Determined by Optic Canal Radiographs, Laryngoscope, April, 1924, xxxiv, 255-270.

Williams, C. B.: Further Observations on Nasal Ganglion Neurosis, Laryngoscope, June, 1924, xxxiv, No. 6, pp. 440-442.

Wilson, A. K.: Nasal Headaches, Jour. Florida Med. Assn., August, 1923, x, 36-39.

Woakes, Ed.: Necrosing Ethmoiditis, Brit. Med. Jour., April 4, 1885; Lancet, July 18, 1885.

Yates, A. L.: Methods of Estimating the Activity of the Ciliary Epithelium within the Sinuses, Jour. Laryngol., and Otol., October, 1924, xxxix, 554-560.

Zuckerkandl, E.: (1) Etiology of Mucous Polypi of the Nose, Brit. Med. Jour., August 24, 1895.

— (2) Normale u. pathologische anatomie d. nasenhoelen, Zweite Auflage, 1893, Wm. Branmueller, Wien.

Digitized by Illinois College of Optometry

INDEX

A

Abducent nerve, relation of, to sphenoid, 148
Abscess of sphenoidal sinus, 167
  of tongue, 273
  orbital, 311
    case of, 316
    diagnosis of, 312
    differential diagnosis in, 314
    dislocation of globe in, 312
    extension of inflammatory process in, 313
    history of, 312
    symptoms of, 312
    treatment of, 315
Afferent and efferent impulses through involuntary nervous system, 295
Alcohol injection of anterior ethmoidal nerve, 72
  of nasal ganglion, 106
Amblyopia, transitory, 176
  case of, 390, 391
Anatomical relations of ethmoidal sinus, posterior, 140
  of nerve of pterygoid canal, 82
  of sphenoidal sinus, 140, 167, 171
  of Vidian nerve, 82
Anatomy of Meckel's ganglion, 74
  of middle meatus, 36
  of nasal ganglion, 74
  of sphenoidal fissure, 132
  of sphenopalatine ganglion, 74
Anesthesia in surgery of paranasal cells, 242
Angina pectoris, 280
  cervical sympathectomy in, 281
  control of, through nasal ganglion, 284
Antrum, maxillary, relation of sphenoidal sinus to, 81
  surgery of, 303
  operation, Sluder's, 303
Artery, internal carotid, 145
  ophthalmic, 145
Asthenopia, 28, 32, 153
Asthma, 275
  and glossodynia, case of, 348
  case of, 350
  of nasal origin, 99
    mechanism of, 101
Atrophy, idiopathic, 28

B

Bacteriologic investigation of hyperplastic post-ethmoidal sphenoiditis, 216
Blepharospasm and lower half headache, case of, 394
  case of, 394, 395, 396
Blindness, acute, case of, 382
  case of, 377
  post-ethmoidal, acute, case of, 383
Bone, metabolism of, in health and disease, 18
Bulla ethmoidalis, 46

C

Cardiac nerves, connection of, 280
Carotid artery, internal, 145
    columnar marking of, 147
  plexus, 77
Case histories, 318
  of acute blindness, 382
    iritis, 366
    post-ethmoidal blindness, 383
  of anterior ethmoidal neuralgia, 72
  of asthma, 350, 351
    and glossodynia, 348
  of blepharospasm, 394, 395, 396
    and lower half headache, 394
  of blindness, 377
  of choroiditis, 372
  of conjunctivitis, 356
  of coryza with vertigo and scotoma, 358
  of deafness, 399
  of dilated pupil, 333, 369
  of failing vision, 384
  of glaucoma, 389
    vertigo and nausea, 358
  of glossodynia, 341
    with paraguesia, 343
  of hay fever, 356
  of headache, hyperplastic sphenoidal, 335
    lifetime, with loss of vision, 376
    lower half, of nasal ganglion origin, 336
    sphenoidal, and migraine, 337
      with drooping eyelids, 389
    vacuum frontal, 318, 319, 320, 321, 322
  of hemianopsia, 361
  of herpes of tongue, 341
  of high grade hyperplastic sphenoiditis, 377
  of hypalgesia, trigeminal, 333

Digitized by Illinois College of Optometry

Case—Cont'd
of hyperplastic sphenoethmoiditis, 366
sphenoidal headache, 335
sphenoiditis, 394
and pregnancy, 336
of hypesthesia, 333
of iritis, 363
with punctate keratitis, 365
of lower half headache, 330, 367
and vertigo, 357
of nasal ganglion origin, 336
of meningitis, death from, 331
of migraine and sphenoidal headache, 337
of motor phenomenon, 343
of nasal ganglion headache and motor phenomenon, 347
injection, failure of, 331
motor phenomenon, 347
neuralgia, 343
sympathetic, 353
phenomenon, 335, 337
sympathetic and sensory, 357
of nausea and vomiting of nasal ganglion origin, 358
of neuralgia, anterior ethmoidal, 323, 324
maxillary and Vidian, 329
nasal ganglion, 325, 326, 328, 343
of neuroretinitis, 385
of nodular headache, 336
of operative injury to optic nerve, 384
of ophthalmic migraine, 359, 360, 361, 387
of ophthalmoplegic migraine, 360
of optic atrophy, 377
nerve involvement with sphenoiditis, 373
neuritis, 378, 385
of orbital abscess, 316
hemorrhage, 399
of otalgia, nausea and diarrhea, 359
of parageusia, 343
of paralysis of accommodation, 387
of third and sixth nerves, 387
of the trochlearis with dilated pupil, 386
of paresthesia, 333
of upper extremity, 330
of photophobia, 392, 393
of post-ethmoidal-sphenoidal suppuration, 372, 395, 399
of professional cramp, 344, 346
of scotoma, 361
scintillans, 393
of secondary closure of sphenoid with optic neuritis, 370
of simple sphenoiditis, 398
of spasm of esophagus, 346
of sphenoidal empyema, 329
headache and migraine, 337
Case—Cont'd
of sphenoiditis, 333
and tic douloureux, 334
hyperplastic, and pregnancy, 336
with pain in shoulder blades, 340
of suppurative sphenoiditis, 359, 393
of supraorbital and nasal ganglion neuralgia, 339
of sympathetic pain, 339
of tabes, 384
of tic douloureux, 334
of transitory amblyopia, 390, 391
of trigeminal hypalgesia, 333
of uveitis with post-ethmoidal sphenoiditis, 364
of vasomotor rhinitis, 355, 356
of vernal hay fever, 355
of vertigo, 360
of Vidian neuralgia, 330
of vulgar migraine, 338
Cavernous sinus, 143
cross section of, 143
internal carotid artery in, 151
relation of cranial nerves to, 141
thrombosis, 314
Cells, anterior ethmoidal, normal outlet of, 37
ethmoidal, 32
maxillary, in man, 25
paranasal, source of infection, 28
surgery of, 237
anesthesia in, 242
summary of, 263
post-ethmoidal, 146
sphenoidal, and foramen rotundum, bone separating, 144
in man, 25
Cervical ganglia, connection of, 280
effect of pressure on, 283
sympathectomy, fundus after, 282
in angina pectoris, 281
sympathetic connections with nasal ganglion, 100
effect of removal of, on throat, 274
experiments upon, 282
Children, diagnosis of hyperplastic sphenoiditis in, 214
headaches and eye disorders in, 178
sphenoidal sinusitis in, 181
Choroiditis, 28
case of, 372
with sphenoiditis, case of, 370
Clinical observations of sphenoidal sinus, 167
picture of anterior ethmoidal neuralgia, 70
relation of hyperplastic sphenoiditis, 156
Clivus of Blumenbach, 145
Cocaine, action of, 271
discovery of, 30
Cocainization of nasal ganglion, 244, 271
Conjunctivitis, case of, 356

Digitized by Illinois College of Optometry

Coryzas, behavior of, 215
effect of, in sphenoidal sinus, 164
influence of, 26
mucous membrane of sphenoidal sinus during, 165
relation of, to vacuum frontal headache, 58
with vertigo and scotoma, case of, 358
Cranial nerves, relation of, to cavernous sinus, 141
to sinuses, 26
to sphenoidal sinus, 27, 180
Cribriform tubinectomy, 247
Cricoidynia, 274

D

Deafness, case of, 399
relation of sphenoidal sinus to, 155
Diagnosis, clinical, of painful diseases of paranasal cells, 59
differential, of anterior ethmoidal neuralgia, 71
of nasal ganglion neuralgia, 110
of orbital abscess, 314
of sphenoidal and nasal ganglion pain, 165
of vacuum frontal headaches, 63
Holmes' pharyngoscope, used in, 192
nasopharyngoscope, use of, in, 214
of anterior ethmoidal neuralgia, 71
of hyperplastic sphenoiditis, 185
of orbital abscess, 312
of nasal ganglion neuralgia, 107
palate hook in, 214
post-nasal, effect of correlated action of pharynx and soft palate, 193
lights used in, 186
x-ray, of anomalies of sphenoid, 212
Diaphragm, spasm of, 279
Diarrhea, 279
Dilated pupil, case of, 333
Displacement irrigation, Proetz, 221
Dizziness of nasal disturbances, 27

E

Earache, control of, in tuberculous laryngitis, 274
through nasal ganglion, 273
explanation of relief through nasal ganglian, 277
Hunt's observations on, 277
Efferent and afferent impulses through involuntary nervous system, 295
Empyema, relation of, to vacuum frontal headache, 58
sphenoidal, case of, 329
Endocrine disturbances in lower half headache, 182
Epicritic sensibility, 287
Esophagus, spasm of, 275
case of, 346
Ethmoidal cells, 32
anterior, normal outlet on, 37
entering infundibulum, 37
labyrinth, anterior, closure of, 32
nerve, anterior, cocainization of, 244
neuralgia, anterior, 68
case of, 72, 323
clinical picture of, 70
diagnosis of, 71
differential diagnosis of, 71
treatment of, 71
pouch, 41
sinus, posterior, anatomical relations of, 140
extension of roof of, into orbit, 161
variations of, 86
Ethmoiditis, anterior hyperplastic, 174
hyperplastic, 60
necrosing, 59
Etiology of vacuum frontal headaches, 35
Eustachian tube orifice, 48
relation of, to sphenoidal sinus, 152
Ewing's sign, 33
Eye changes from sympathetic irritation, 282
disorders and headaches, explanation of, 176
in children, 178
explanation of, 176
disturbance in vacuum frontal headache, 32
inability to use, 32
lesions, control of pain in, 286
of nasal origin, 167
sensation of sand in, 34
symptoms in vacuum ethmoidal headache, 66
Eyelids, drooping, with sphenoidal headache, case of, 389

F

Face, disproportionate growth of, 26
spasm of, 279
Fatalities following operations on nose, 236
Fissure, sphenoidal, 27 (*see* sphenoidal fissure)
Fissures in pterygopalatine fossa, 78
Focal infection, relation of, to lower half headache, 114
Foramen ovale, 145
rotundum, 131, 144
sphenopalatine, 79
unusual position of, 92
spinosum, 145
Forceps, intranasal, Sluder's, 305
Knight-Leuder, 259
post-ethmoidal, 262

Digitized by Illinois College of Optometry

Formaldehyde, applications of, to sphenopalatine foramen, 130
Fossa of skull, anterior and middle, 142
pterygopalatine, 78
fissures of, 78
sphenomaxillary, description of, 84
sphenopalatine, 76
Frontal pouch, 40
of middle meatus, cavernous tissue of, 47
sinus, 32
and vacuum headache, 34
closure of, 31
in vacuum frontal headaches, 55
entrance of, 39
floor of, 31
infection, 33
methods of closure of, 62
removal of floor of, 239
Fundus after cervical sympathectomy, 282

G

Ganglion, ciliary, nerve branch to, 69
Gasserian, 145
anatomy of, 109
otitis media secondary to, 278
relation of sphenoidal sinus to, 147
tumors of, 109
geniculate, 76
Meckel's, anatomical relations of, 78
anatomy of, 74
branches of, 78
histology of, 74
motor root of, 75
roots of, 75
sensory root of, 75
sympathetic root of, 75
nasal, anatomical relations of, 78
anatomy of, 74
branches of, 78
cocainization of, 245, 271
control of angina pectoris through, 284
of earache through, 273
of hiccough through, 275
of mandibular pain through, 273
of toothache through, 273
degeneration of, 294
histology of, 74, 134
injection of, 115
comparison of methods, 127
correct placing of needle, 118
hemorrhage from, 122
infiltration of nerve sheaths in, 137
instrumentarium in, 122
lateral wall of nose in, 119
needles for, 125
relation of sphenoidal fissure to, 132
results of, 136
technique of, 123
Ganglion, nasal, injection of—Cont'd
through posterior palatine canal, 127
motor root of, 75
neuralgia of, case of, 325, 326. 328
relation of hyperplastic sphenoiditis to, 139
roots of, 75
sensory root of, 75
sympathetic root of, 75
otic, degeneration of, 294
semilunar, relation of, to sphenoid, 147
sphenopalatine, anatomical relations of, 78
anatomy of, 74
branches of, 78
histology of, 74
motor root of, 75
roots of, 75
sensory root of, 75
sympathetic root of, 75
Gasserian ganglion, 145
anatomy of, 109
otitis media secondary to removal of, 278
relation of sphenoidal sinus to, 147
tumors of, 109
Geniculate ganglion, 76
Glaucoma, 98
case of, 389
vertigo and nausea, case of, 358
Glossitis, 273
Glossodynia, 272
and asthma, case of, 348
case of, 341
with paragousia, case of, 343
Glossopharyngeal neuralgia, 110

H

Hay fever, case of, 356
cocainization of nasal ganglion in, 105
injection of nasal ganglion in, 106
vernal, case of, 355
Headaches and eye disorders, explanation of, 176
in children, 178
as a symptom in disease, 28
bilious, 28
blind, 28
classification of, 29
control of, 276
from all causes, 64
frontal sinus, cause of, 35
general discussion of, 28
hyperplastic sphenoidal, case of, 335
inability to use the eyes in, 32
intractable, 182
lifetime, with loss of vision, case of, 376
lower half, 93, 271
case of, 330, 367, 393

Digitized by Illinois College of Optometry

Headaches, lower half—Cont'd
endocrine disturbances in, 182
nasal ganglion origin, case of, 336
relation of focal infection to, 114
malarial, 275
nasal ganglion, and motor phenomenon, case of, 347
differentiation of, 27
nodular, 279, 289
case of, 336
ocular, 29
of nasal ganglion origin, 166
of sphenoidal origin, 166
prognosis of, 64
recurrent, 28
causes of, 28
treatment of, 28
relation of mental disorder to, 182
sick, 28
sphenoidal, and migraine, case of, 337
with drooping eyelids, case of, 389
synonyms for, 30
syphilitic, 275
treatment of, 65
vacuum frontal, 31
case of, 318
classification of, 55
clinical picture in, 33
closure frontal sinus in, 55
differential diagnosis of, 63
Ewing's sign in, 33
eye disturbance in, 32
gross etiology, 35
incidence of, 63
influence of polyps in, 62
pathology of, 55
prognosis of, 64
relation of coryza to, 58
septal deviation in, 51
treatment of, 65
with eye symptoms only, 66
x-ray of sinuses in, 36, 59
Hemianopsia, case of, 361
Hemicrania, 28
Hemorrhage from injection of nasal ganglian, 122
orbital, case of, 399
Herpes, maxillary, 274
of maxillary nerve, 104
of ophthalmic nerve, 104
of tongue, 272
case of, 341
ophthalmic, 274
oticus, 275
Hiatus semilunaris, 37
closure of, 47
measurements of, 46
occlusion of, 56
Hiccough, control of, through nasal ganglion, 275
reflexes in, 288
Histology of nasal ganglion, 112, 134
Holmes' nasopharyngoscope, 165
sphenoidal observations with, 169
pharyngoscope used in diagnosis, 192
Hurd's speculum, 54
Hypalgesia, trigmenial, case of, 333
Hyperplasia, fibrous, 22
of bone of sphenoethmoidal wall, 19
of middle turbinate, 22
Hyperplastic anterior ethmoiditis, 174
disease in the nose, extent of, 168
picture, typical, 204
post-ethmoidal sphenoiditis, cases of, 359
post-ethmoiditis (*see* Hyperplastic sphenoiditis)
process, distribution of, 190
index to, 181
involution of, 219
narrowing of bone canals in, 179
sphenoidal headache, case of, 335
sphenoiditis and pregnancy, case of, 336
change of climate in, 235
character of secretion in, 205
clinical relations of, to the environing nerves, 139
diagnosis of, 185
in children, 214
examination of bone in, 168
formation of polyps in, 175
high grade, case of, 377
lesions caused by, 168
optic nerve disorders in, 176
pathology of, 184
prognosis of, 216
relation of, to nasal ganglion, 139, 182
removal of tonsils in, 235
surgery of, 237
treatment of, 219
unilateral significance of, 209
use of vaccines in, 235
Wright's observations on, 168
Hypertension, sympathetic nervous system and, 301
Hypesthesia, case of, 333
Hypophysis, relation to nose, 28
Hysteria, 28

I

Infection, frontal sinus, 33
Inflammatory process, extension of, in orbital abscess, 313
Infundibulum, 37
Injection of nasal ganglion, 115
alcoholic, 115
comparison of methods, 127
correct placing of needle, 118
failure of, case of, 331
hemorrhage from, 122
infiltration of nerve sheaths in, 137

Digitized by Illinois College of Optometry

Injection of nasal ganglion—Cont'd
instrumentarium in, 122
lateral wall of nose in, 119
results of, 136
technique of, 123
through posterior palatine canal, 127
transitory results of, 112
Instrumentarium in nasal ganglion injection, 122
Intracranial lesions, 235
Intranasal forceps, Sluder's, 305
Intrasphenoidal observations, 366
Involuntary nervous system, 280
afferent and efferent impulses through, 295
explanation of, 297
observations on, 295
phenomena of, 297
Iodized oil, use of, 229
Iritis, acute, case of, 366
case of, 363
with punctate keratitis, case of, 365
Irrigation, Proetz displacement, 221

K

Keratitis, punctate, with iritis, case of, 365
Killian's long blade speculum, 53
Knife, sphenoidal, 263
turbinate, 263
Knight-Leuder forceps, 259

L

Laryngeal and cervical sympathetic nerves, 299
Laryngitis, tuberculous, control of earache in, 274
Larynx, spasm of, 279
Leitz lilliput arc lamp, 186
Lights used in post-nasal diagnosis, 186
Lipiodol, use of, 229
Lower half headache, 93, 271
and vertigo, case of, 357
case of, 330, 367, 393
endocrine disturbances in, 182
neuralgic syndrome of, 93
of nasal ganglion origin, case of, 336
relation of focal infection to, 114

M

Malarial headache, 275
Mandibular pain, control of, through nasal ganglion, 273
Mastoidalgia, 273
Maxillary and Vidian neuralgia, case of, 329
antrum, operation, Sluder's, 303
relation of sphenoidal sinus to, 81
surgery of, 303
Maxillary—Cont'd
cells in man, 25
herpes, 274
nerve, 77
entering foramen rotundum, 145
lesions of, 27
relation of, to sphenoidal sinus, 150
sinus, basal dissection of, 81
Meatus, middle, anatomical insufficiency of vault of, 58
anatomy of, 36
cavernous tissue of, 46
communication with frontal sinus, 39
edema of vault of, 57
ethmoidal pouch of vault of, 41
frontal pouch of vault of, 40
polypoid closure of, 62
vault of, 39
Wood's metal casts of, 60
Meckel's ganglion, alcoholic injection of, 115
anatomical relations of, 78, 83
anatomy of, 74
branches of, 78
clinical relations of, 90
experiments upon, 113
histology of, 74, 112, 134
injection of, 115
comparison of methods, 127
hemorrhage from, 122
infiltration of nerve sheaths in, 137
instrumentarium in, 122
lateral wall of nose in, 119
needles for, 125
results of, 136
technique of, 123
through posterior palatine canal, 127
motor root of, 75
neuralgia, diagnosis of, 107
differential diagnosis of, 110
prognosis of, 111
treatment of, 115
neurosis, syndrome of, 74
position of, 27
relation of, to hyperplastic sphenoiditis, 139
to lateral wall of nose, 89
to nasal cavity, 80
to sinuses, 80
to walls of paranasal cells, 88
to walls of sinuses, 88
roots of, 75
sensory root of, 75
sympathetic root of, 75
Meningitis, death from, case of, 331
Mental disorders, relation of, to headache, 182
Mercurochrome, applications of, to sphenopalatine ganglion, 130

Digitized by Illinois College of Optometry

Middle meatus, anatomical insufficiency of vault of, 58
anatomy of, 36
cavernous tissue of, 46
communication with frontal sinus, 39
edema of vault of, 57
ethmoidal pouch of vault of, 41
frontal pouch of vault of, 40
polypoid closure of, 62
vault of, 39
Wood's metal casts of, 60
turbinate, 38
amputation of, 47
body, chronic hypertrophy of, 22
cavernous tissue of, 46
conservation of, 237
posterior tip of, 241
hyperplasia of, 22
hypertrophy of, 58
needle transfixing the, 121
relation of sphenopalatine foramen to posterior tip of, 118
to tubercle of septum, 52
removal of, 237
Migraine, 28, 173
and sphenoidal headache, case of, 337
cause of, 291
ophthalmic, 169, 290
case of, 359, 360, 361, 387
ophthalmoplegic, case of, 360
sympathetic, 169
vulgar, 163
case of, 338
Motor phenomena, 288
case of, 343
Mucous membrane of sphenoidal sinus during coryza, 165
of sphenoidal sinus, papillary hypertrophy of, 20
Muscle imbalance, 176
internal pterygoid, 151
levator palati, 151
superior oblique, 32
tensor palati, 146
relation of, to sphenoidal sinus, 154
tonus, and sympathetic nervous system, 300
Myalgia, 289

N

Nasal asthma, 99
mechanism of, 101
diseases, neck and shoulder pains in, 27
varieties of, 80
disturbances, dizziness of, 27
fossae, narrow, 36
ganglion, alcoholic injection of, 106, 115
anatomical relations of, 78, 83
anatomy of, 74
Nasal ganglion—Cont'd
and sphenoidal pain, differential diagnosis of, 165
branches of, 78
cervical sympathetic connections with, 100
clinical relations of, 90
cocainization of, 244, 271
control of angina pectoris through, 284
of earache through, 273
of hiccough through, 275
of mandibular pain through, 273
of toothache through, 273
degeneration of, 294
electrical stimulation of, 106
environment of, 82
experiments upon, 113
headache and motor phenomenon, case of, 347
histology of, 74, 112, 134
injection of, 115
comparison of methods, 127
correct placing of needle, 118
failure of, case of, 331
hemorrhage from, 122
infiltration of nerve sheaths in, 137
in hay fever, 106
instrumentarium in, 122
lateral wall of nose in, 119
needles for, 125
relation of sphenoidal fissure to, 132
results of, 136
technique of, 123
through posterior palatine canal, 127
transitory results of, 112
motor phenomena, case of, 347
motor root of, 75
neuralgia, case of, 325, 326, 328, 339
diagnosis of, 107
differential diagnosis of, 110
prognosis of, 111
secondary to hyperplastic postethmoidal sphenoiditis, 114
treatment of, 115
anatomical considerations in, 115
neurosis, syndrome of, 74
phenomena, case of, 335, 337
relation of hyperplastic sphenoiditis to, 139, 182
of sphenomaxillary fossa to, 87
of sciatica to, 285
to lateral wall of nose, 89
to nasal cavity, 80
to sinuses, 80
to walls of paranasal cells, 88
to walls of sinuses, 88
roots of, 75

Digitized by Illinois College of Optometry

Nasal ganglion—Cont'd
sensory root of, 75
sympathetic and sensory, case of, 357
root of, 75
syndrome, 93
syndromes, cases of, 325
unusual phenomena of, 98
headaches, differentiation of, 27
lesions giving rise to headaches, 30
nerve, 68
anatomical description of, 68
varieties, 70
polyps, 57, 59
surgery, twilight sleep in, 245
Nasociliary neuralgia, 68
Nasofrontal duct, 37
Nasopharyngoscope, Holmes,' 165
sphenoidal observations with, 169
Nasopharynx, tumors of, 110
Nausea and vomiting of nasal ganglion origin, case of, 358
Needle, correct placing in nasal ganglion injection, 118
transfixing middle turbinate, 121
Needles for injection of nasal ganglion, 125
straight and curved, correctly placed for injection of nasal ganglion, 119
Nerve, abducent, relation of, to sphenoid, 148
anterior ethmoidal, cocainization of, 244
branch to the ciliary ganglion, 69
great deep petrosal, 76
great superficial petrosal, 76
infratrochlear, 69
maxillary, 77
relation of, to sphenoidal sinus, 150
nasal, 68
anatomical description of, 68
varieties, 70
oculomotor, paralysis of, 167
relation of, to sphenoid, 148
of pterygoid canal, anatomical relations of, 82
ophthalmic, relation of, to sphenoid, 148
optic, disorders from hyperplastic sphenoiditis, 176
operative injury to, case of, 384
relation of sphenoidal sinus to, 90
sheaths, infiltration of, in nasal ganglion injection, 137
supraorbital, neuralgia of, 63
trigeminal, relation of, to sphenoid, 145
trunks, involvement of, 167
Vidian, 112
faradic stimulation of, 164
relation of, to sphenoid, 149
Nerves, cardiac, connection of, 280
cervical sympathetic, 299
cranial, relation of, to cavernous sinus, 141
to sinuses, 26
to sphenoidal sinus, 27, 180
hyperplastic sphenoiditis and its relation to, 139
clinical, and its relations to, 139
laryngeal, 299
long ciliary, 69
pain, 287
Nervous system, involuntary, 280
afferent and efferent impulses through, 295
explanation of, 297
observations on, 295
phenomena of, 297
sympathetic, 280
and hypertension, 301
and muscle tonus, 300
and peripheral vascular system, 302
and spastic paralysis, 300
observations on, 300
Nervus terminalis, 276
Neuralgia, anterior ethmoidal, 68
cases of, 72, 323
clinical picture of, 70
diagnosis of, 71
differential diagnosis of, 71
treatment of, 71
glossopharyngeal, 110
maxillary and Vidian, case of, 329
nasal ganglion, case of, 339, 343
diagnosis of, 107
differential diagnosis of, 110
prognosis of, 111
secondary to hyperplastic postethmoidal sphenoiditis, 114
sympathetic, case of, 353
treatment of, 115
anatomic considerations in, 115
of supraorbital nerve, 63
supraorbital, case of, 339
Vidian, 102
Neurasthenia, 28
Neuritis, optic, case of, 378, 385
Neurological problems in rhinology, 271
Neurons, postganglionic, 77
preganglionic, 77
somatic sensory, 75
sympathetic, 284
afferent, 76
Neuroretinitis, case of, 385
Neurosis, nasal ganglion, 74
Nodular headache, 279, 289
case of, 336
Nose, 25
anatomy of, 29, 62
of middle meatus of, 36
clinical appearance, normal, 56
fatalities following operation on, 236

Digitized by Illinois College of Optometry

Nose—Cont'd
general considerations of, 25
hyperplastic disease of, extent of, 168
injury to, 25
orthopedic problems of, 27
periosteum of, 26
relation of hypophysis to, 28
of orbit to, 311
short, 268
tall, 269
wall of, 146

O

Ocular lesions of nasal ganglion origin, 359
of post-ethmoidal-sphenoidal origin, case of, 359
tuberculosis, 216
Oculomotor nerve, paralysis of, 167
relation of, to sphenoid, 148
Ophthalmic artery, 145
herpes, 274
migraine, 290
case of, 359, 360, 361
nerve, relation of, to sphenoid, 148
Ophthalmoplegic migraine, case of, 360
Ophthalmoscope, discovery of, 29
Operation, antrum, Sluder's, 303
post-ethmoidal-sphenoidal, technique of, 242, 248
sphenoidal, danger of, 190
technique of, 248
Operative procedure on post-ethmoidal sinuses, 246
conservative, 246
radical, 246
on sphenoidal sinus, 246
conservative, 246
radical, 246
Optic atrophy, 28
case of, 377
canal, lesions on, 167
narrowing of, 178
observations on, 178
prolongation of sphenoidal sinus around, 141
size of, 177
nerve disorders in hyperplastic sphenoiditis, 176
lesions of, 27
operative injury to, case of, 384
neuritis, 28
case of, 378, 385
idiopathic, 28
Orbit, 48
relation of, to nose, 311
right, dissection of, 32
Orbital abscess, 311
case of, 316
diagnosis of, 312
differential diagnosis of, 314
dislocation of globe in, 312
Orbital abscess—Cont'd
extension of inflammatory process in, 313
history of, 312
symptoms of, 312
treatment of, 315
hemorrhage, case of, 399
Osteitis, rarefying, 20
Osteoblasts, 18
depositing bone salts, 18
Osteoclasts absorbing bone salts, 18
action of, 21
Otalgia, 273, 277, 278
and nausea and diarrhea, case of, 359
Otic ganglion, degeneration of, 294
Otitis media, secondary to removal of Gasserian ganglion, 278

P

Pain behind the eyes, 34
centers, 289
control of, in eye lesions, 386
in shoulder blades, with sphenoiditis, case of, 340
nerves, 287
of neck and shoulder, in nasal diseases, 27
sphenoidal, and nasal ganglion, differential diagnosis of, 165
sympathetic, case of, 339
transmission, 285, 293
Palate hook, use of, in diagnosis, 214
Paraguesia, case of, 343
with glossodynia, case of, 343
Paralysis of accommodation, case of, 387
of oculomotor nerve, 167
of trochlearis, with dilated pupil, case of, 386
spastic and sympathetic nervous system, 300
third and sixth nerves, case of, 387
ulnar, 286
Paranasal cells, painful diseases of, clinical diagnosis, 59
source of infection, 28
surgery of, 237
anesthesia in, 242
Sluder's method, 242
summary of, 263
Paratrigeminal area, lesions of, 108
Paresthesia, case of, 333
of upper extremity, case of, 330
Pathological changes in post-ethmoidal-sphenoidal district, 189
in sphenoidal district, 189
observations of sphenoidal sinus, 167
Pathology of hyperplastic sphenoiditis, 184
Petrosal nerve, great deep, 76
great superficial, 76

Digitized by Illinois College of Optometry

Pharyngeal tonsil, remnant of, 151
Pharyngoscope, Holmes', used in diagnosis, 192
Pharynx and soft palate, in post-nasal diagnosis, 193
practical application of observations on, 202
Phlegmon, orbital, 311
case of, 316
diagnosis of, 312
differential diagnosis in, 314
dislocation of globe in, 312
extension of inflammatory process in, 313
history of, 312
symptoms of, 312
treatment of, 315
Photophobia, 276
case of, 392, 393
Polyps, formation of, in hyperplastic sphenoiditis, 175
nasal, 57, 59
Post-ethmoidal forceps, 262
Post-ethmodial-sphenoidal district, pathological changes in, 189
normal description of, 188
operation, technic of, 242, 248
suppuration, case of, 372, 399
recognition of, 191
Post-ethmoidal sphenoiditis, hyperplastic, treatment of, 219
Post-ethmoiditis, hyperplastic (*see* Hyperplastic sphenoiditis)
Pregnancy, and hyperplastic sphenoiditis, case of, 336
Proetz displacement irrigation, 221
Professional cramp, case of, 344, 346
Prognosis of headaches, 64
of hyperplastic sphenoiditis, 216
of nasal ganglion neuralgia, 111
Protopathic sensibility, 287
Pulley of superior oblique, 31
Pupil and asthma, 352
dilatation of, 158
dilated, case of, 333, 369
with paralysis of trochlearis, 386
Psychosis associated with sinus disease, 173
Pterygoid canal, nerve of, anatomical relations of, 82
Pterygomaxillary fossa, 146
Pterygopalatine fossa, 78
fissures in, 78

R

Reflexes in hiccough, 288
Retinitis, 28
Rhinitis, vasomotor, case of, 355, 356
Rhinology, neurological problems in, 271
Rhinorrhea, 105

S

Sciatica, 276
relation of, to nasal ganglion, 285
Scotoma and vertigo, coryza with, case of, 358
case of, 361
scintillans, case of, 393
Secretion in hyperplastic sphenoiditis, character of, 205
Semilunar ganglion, relation to sphenoid, 147
Sensibility, epicritic, 287
protopathic, 287
Sensory fibers of trigeminus, 274
phenomena, 288
Septum, tubercle of, 49
relations of middle turbinate to, 52
Silver nitrate, applications of, to sphenopalatine foramen, 130
Sinus, cavernous, 143
cross section of, 143
relation of cranial nerves to, 141
thrombosis of, 314
disease, psychosis associated with, 173
frontal, 32
closure of, 31
floor of, 31
infection, 33
methods of closure of, 62
middle meatus communicating with, 39
removal of floor of, 239
maxillary, basal dissection of, 81
posterior ethmoidal, anatomical relations of, 140
variations of, 86
sphenoidal, 48, 143
abscess of, 167
anatomical observations of, 167
anatomical relations of, 140, 171
asymmetry of, 81
basal dissection of, 81
bony wall of, 151
clinical observations of, 167
clinical relation of, 156
effect of coryza on, 164
extent of, 145
headache from, 166
mucous membrane of, during coryza, 165
observations on, 140
pathological observations of, 167
permeability of wall of, 148, 159
pneumatization of, 81
prolongation of, around optic canal, 141
into pterygoid process, 153
relation of cranial nerves to, 27, 180
Gasserian ganglion to, 147
maxillary nerve to, 150
optic nerve to, 90
Vidian canal to, 149
to eustachian tube, 152

Digitized by Illinois College of Optometry

Sinus, sphenoidal, relation—Cont'd
to deafness, 155
variations of, 86
Vidian canal in, 165
x-ray of, 154
probes in, 211
Sinuses, face in development of, 26
formation of, 25
function of, 25
gravity drainage, 25
relation of cranial nerves to, 26
shape of, 26
size of, 26
suppurating, suction treatment of, 220
x-ray of, 36
in vacuum frontal headache, 59
technique of exposure, 231
with use of lipiodol, 230
Sinusitis, sphenoidal, in children, 181
Skull, anterior and middle fossae of, 142
left middle fossa of, 144
Sluder's antrum operation, 303
cribriform tubinectomy, 247
sphenoidal operation, 248
Soft palate, 48
and pharynx in post-nasal diagnosis, 193
practical application of observations on, 202
Spasm of diaphragm, 279
of esophagus, 275
case of, 346
of face, 279
of larynx, 279
of throat, 279
Spastic paralysis, and sympathetic nervous system, 300
Speculum, bivalve, Vienna model, 55
Hurd's, 54
Killian's long blade, 53
sphenoidal, 267
Sphenoethmoidal wall, hyperplasia of bone of, 19
Sphenoethmoiditis, hyperplastic, case of, 366
Sphenoid, lesser wing of, 146
Sphenoidal and nasal ganglion pain, diagnosis of, 165
cell and foramen rotundum, bone separating, 144
in man, 25
district, normal description of, 188
pathological changes in, 189
empyema, case of, 329
fissure, 27
anatomy of, 132
bony environments of, 131
nerves of, 27
relation to injection of nasal ganglion, 132
variations of structure in, 132
headache and migraine, case of, 337
with drooping eyelids, case of, 389
Sphenoidal—Cont'd
knife, 263
operation, danger of, 190
technique of, 248
sinus, 48, 143
abscess of, 167
anatomical observations of, 167
relations of, 140, 171
variations of, 210
anomalies of, 210
asymmetry of, 81
basal dissection of, 81
bony wall of, 151
clinical observations of, 167
clinical relation of, 156
effect of coryza on, 164
extent of, 145
headache from, 166
mucous membrane of, during coryza, 165
observations on, 140
Onodi's observations on, 172
papillary hypertrophy of mucous membrane of, 20
pathologic observations of, 167
permeability of wall of, 148, 159, 174
pneumatization of, 81
prolongation of, around optic canal, 141
into pterygoid process, 153
relation of:
abducent nerve to, 148
cranial nerves to, 27, 180
Gasserian ganglion to, 147
maxillary antrum to, 81
maxillary nerve to, 150
ophthalmic nerve to, 148
optic nerve to, 90
semilunar ganglion to, 147
to cavernous sinus, 143
to cranial nerves, 180
to deafness, 155
to eustachian tube, 152
Vidian canal to, 149
Vidian nerve to, 149
Sluder's observations on, 172
surgery of, 237
Tiersche grafts in, 219
two types of involvement of, 157
variations of, 86
Vidian canal in, 165
x-ray of, 154
of probes in, 211
sinusitis in children, 181
speculum, 267
suppuration, recognition of, 191
Sphenoiditis and tic douloureux, case of, 334
case of, 333
character of secretion in, 205
distribution of pain in, 163

Digitized by Illinois College of Optometry

Sphenoiditis—Cont'd
hyperplastic, and pregnancy, case of, 336
case of, 394
change of climate in, 235
character of secretion in, 205
clinical relations of, to environing nerves, 139
diagnosis of, 185
in children, 214
examination of bone in, 168
formation of polyps in, 175
high grade, case of, 377
lesions caused by, 168
optic nerve disorders in, 176
pathology of, 184
post-ethmoidal, case of, 359
treatment of, 219
prognosis of, 216
relation of, to nasal ganglion, 139, 182
removal of tonsils in, 235
surgery of, 237
treatment of, 219
unilateral significance of, 209
vaccines in, 235
Wright's observations on, 168
post-ethmoidal, bacteriological investigation of, 216
nasal ganglion neuralgia secondary to, 114
uveitis with, case of, 364
simple, case of, 398
suppurative, case of, 359, 393
with choroiditis, case of, 370
with optic nerve involvement, case of, 373
with pain in shoulder blades, case of, 340
Sphenomaxillary fossa, 76
description of, 84
Sphenopalatine foramen, 79
an unusual, 117
application to, 130
bony environments of, 131
relation to posterior tip of middle turbinate, 118
unusual position of, 92
fossa, 76
ganglion, alcoholic injection of, 115
anatomical relations of, 78, 83
anatomy of, 74
branches of, 78
clinical relations of, 90
experiments upon, 113
histology of, 74, 112, 134
injection of, 115
comparison of methods, 127
hemorrhage from, 122
infiltration of nerve sheaths in, 137
instrumentarium in, 122
lateral wall of nose in, 119
Sphenopalatine ganglion injection—Cont'd
needles for, 125
results of, 136
technique of, 123
through posterior palatine canal, 127
in the sphenomaxillary fossa, relations of, 87
motor root of, 75
neuralgia, diagnosis of, 107
differential diagnosis of, 110
prognosis of, 111
treatment of, 115
neurosis, syndrome of, 74
position of, 27
relation of, to hyperplastic sphenoiditis, 139
to lateral wall of nose, 89
to nasal cavity, 80
to sinuses, 80
to walls of paranasal cells, 88
to walls of sinuses, 88
roots of, 75
sensory root of, 75
sympathetic root of, 75
Suppuration, post-ethmoidal-sphenoidal, case of, 372, 395, 399
post-ethmoidal-sphenoidal, recognition of, 191
sphenoidal, recognition of, 191
Suppurative sphenoiditis, case of, 359, 393
Supraorbital nerve, neuralgia of, 63
neuralgia, case of, 339
Surgery, nasal, twilight sleep in, 245
of maxillary antrum, 303
of paranasal cells, 237
anesthesia in, 242
Sluder's technique, 242
summary of, 263
Sympathetic afferent neurons, 76
irritation, eye changes from, 282
nervous system, 280
and hypertension, 301
and muscle tonus, 300
and peripheral vascular system, 302
and spastic paralysis, 300
general, 274
observations on, 300
neurons, 284
pain, case of 339
phenomena, 288
syndrome, 94
Sympathectomy, cervical, in angina pectoris, 281
Syndrome, Horner's, 281
nasal ganglion, 93
cases of, 325
neuralgic, 93
sympathetic, 94
Syphilis, 28
Syphilitic headache, 275

Digitized by Illinois College of Optometry

T

Tabes, case of, 384
Technique of nasal ganglion injection, 123
of post-ethmoidal-sphenoidal operation, 242, 248
of sphenoidal operation, 248
Temporal bone, petrous part of, 145
Tensor palati muscle, 146
relation of, to sphenoidal sinus, 154
Thornwald's disease, 196
Throat, spasm of, 279
Thrombosis of cavernous sinus, 314
Tic douloureux and sphenoiditis, case of, 334
case of, 334
Tiersche grafts in sphenoid, 219
Tongue, abscess of, 273
burning, 272
herpes of, 272
case of, 341
Tonsils, pharyngeal remnant of, 151
removal of, in hyperplastic sphenoiditis, 235
Toothache, control of, through nasal ganglion, 273
Trochlearis, paralysis of, with dilated pupil, case of, 386
Treatment of anterior ethmoidal neuralgia, 71
of headaches, 65
of hyperplastic post-ethmoidal sphenoiditis, 219
of hyperplastic sphenoiditis, 219
of nasal ganglion neuralgia, 115
of orbital abscess, 315
suction, of suppurating sinuses, 220
Trigeminal hypalgesia, case of, 333
nerve, relation of, to sphenoid, 145
neuralgia, relation of, to sympathetic, 283
Trigeminus, sensory fibers of, 274
Tuberculosis, ocular, 216
Tuberculous laryngitis, control of earache in, 274
Tumors of Gasserian ganglion, 109
of nasopharynx, 110
Turbinate body, middle, chronic hypertrophy of, 22
knife, 263
middle, 48
amputation of, 47
cavernous tissue of, 46
conservation of posterior tip of, 241
hypertrophy of, 58
Turbinate, middle—Cont'd
needle transfixing the, 121
relation of sphenopalatine foramen to posterior tip of, 118
relations of, to tubercle of the septum, 52
removal of, 237
Tubinectomy, cribriform, 247
Twilight sleep in nasal surgery, 245

U

Ulnar paralysis, 286
Uveitis with post-ethmoidal sphenoiditis, case of, 364

V

Vaccines, use of, in hyperplastic sphenoiditis, 235
Vacuum ethmoidal headaches with eye symptoms only, 66
frontal headaches, cases of, 318
classification of, 55
clinical picture in, 33
closure frontal sinus in, 55
coryza in relation to, 58
differential diagnosis of, 63
Ewing's sign in, 33
eye disturbance in, 32
frontal sinus and, 34
gross etiology of, 35
incidence of, 63
influence of polyps in, 62
pathology of, 55
prognosis of, 64
septal deviation in, 51
treatment of, 65
with eye symptoms only, 31
x-ray of sinuses in, 36
Vascular system, peripheral, and sympathetic nervous system, 302
Vasomotor rhinitis, case of, 355, 356
Vertigo and nausea, with glaucoma, case of, 358
and scotoma, coryza, case of, 358
case of, 360
with lower half headache, case of, 357
Vidian and maxillary neuralgia, case of, 329
canal, anterior outlet of, 151
in sphenoidal sinus, 165
narrowing of, 178
relation of, to sphenoid, 149
nerve, 112
anatomical relations of, 82
faradic stimulation of, 164
lesions of, 27
of pterygoid canal, 75
relation of, to sphenoid, 149

Digitized by Illinois College of Optometry

Vidian—Cont'd
neuralgia, 102
case of, 329, 330
Vision, failing, case of, 384
loss of, with lifetime headache, case of, 376

W

Writer's cramp, 275

X

X-ray diagnosis of anomalies of sphenoid, 212
of probes in sphenoidal sinus, 211
of sinuses in vacuum frontal headache, 36, 59
technique of exposure, 231
with use of lipiodol, 230
of sphenoid, 154

Digitized by Illinois College of Optometry

Digitized by Illinois College of Optometry